

A close-up photograph of a dental model. The model features a metal framework, likely cobalt-chromium, which is partially covered with a pink acrylic resin base. Several white, realistic-looking teeth are attached to the base. The background is dark, making the metallic and resin components stand out.

Tips and Tricks

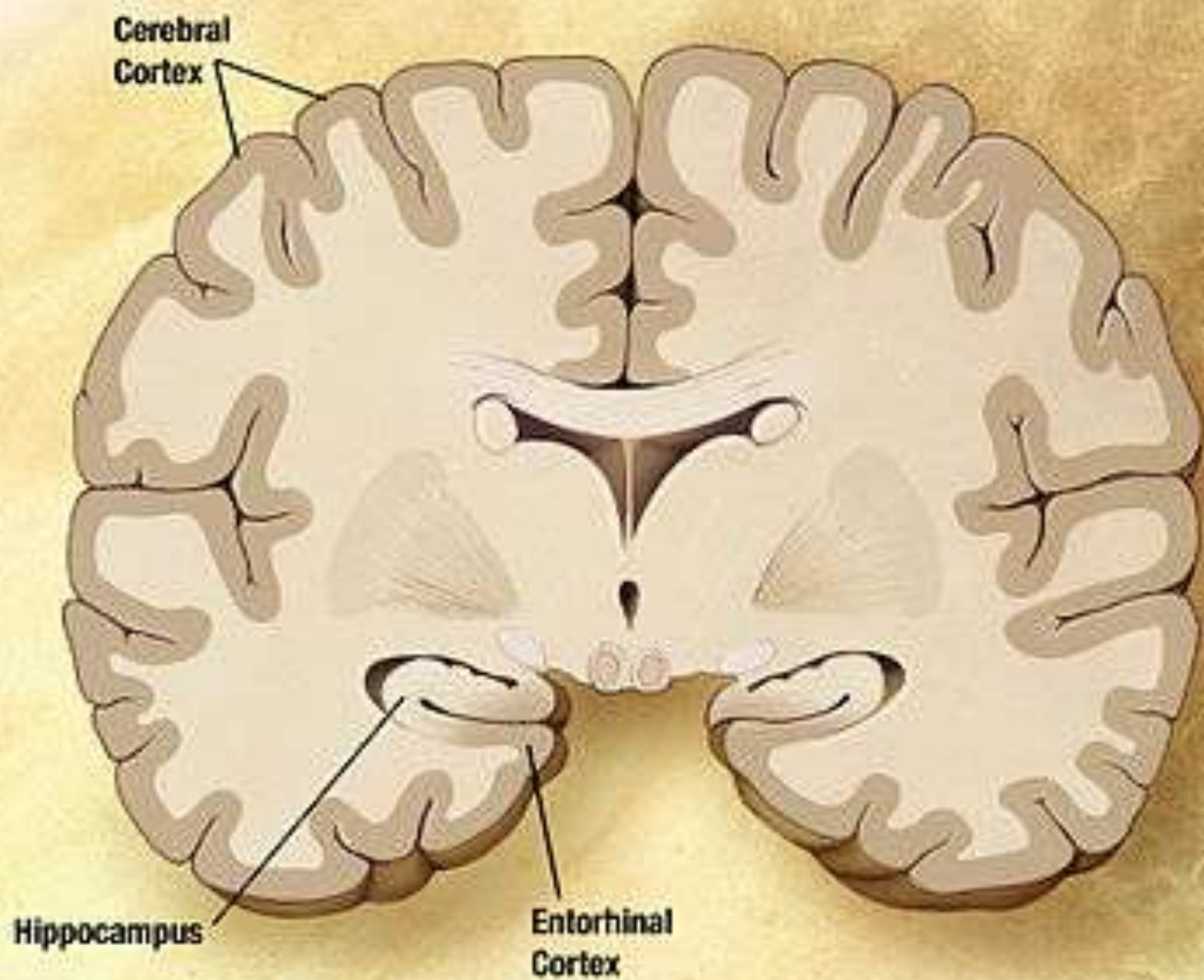
For

Successful outcomes with dentures

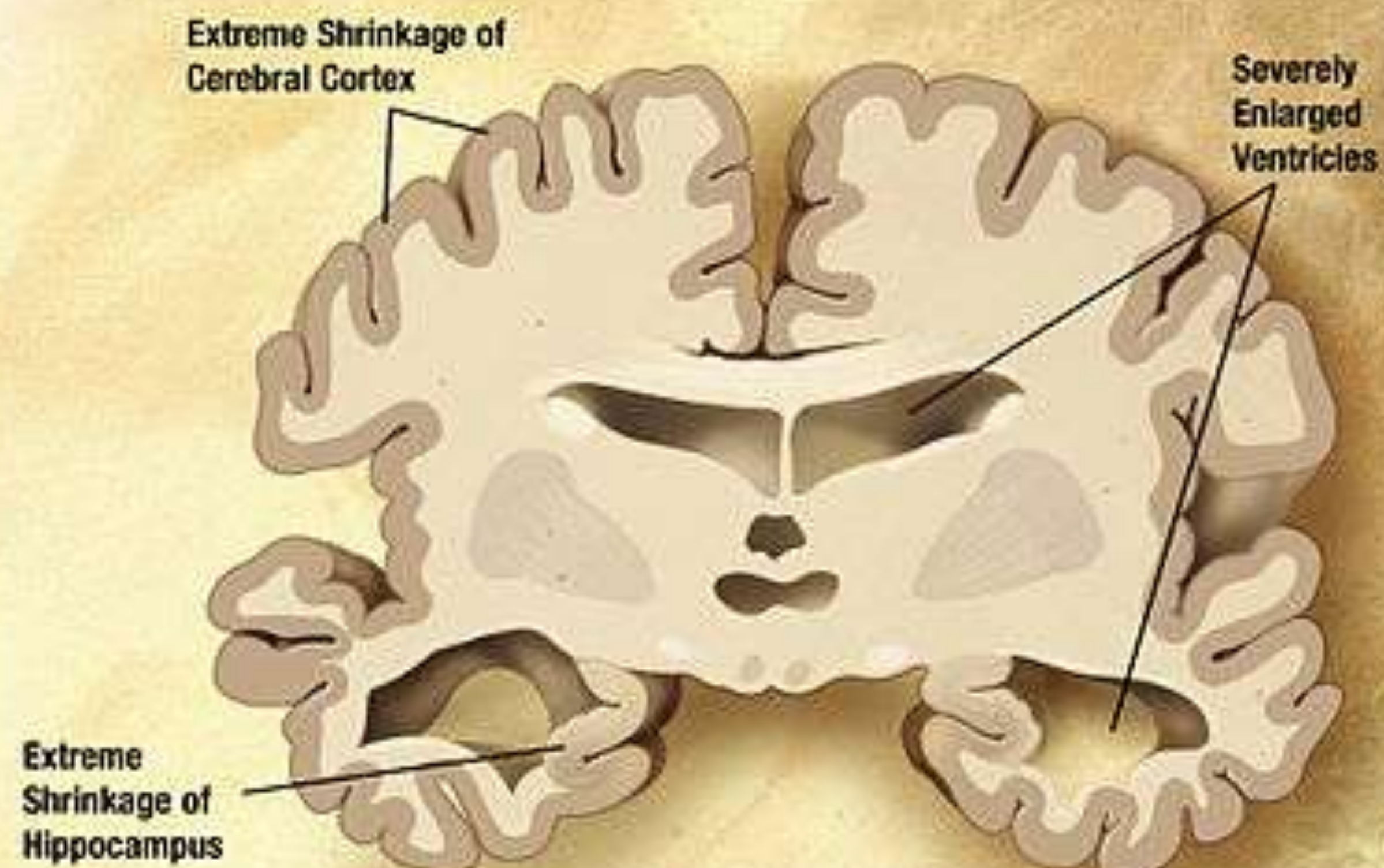
Removable prosthodontics

is difficult

Normal



Alzheimers



Find a great technician



Rowan Garstang



Sam Hesketh

Find and listen to your mentor

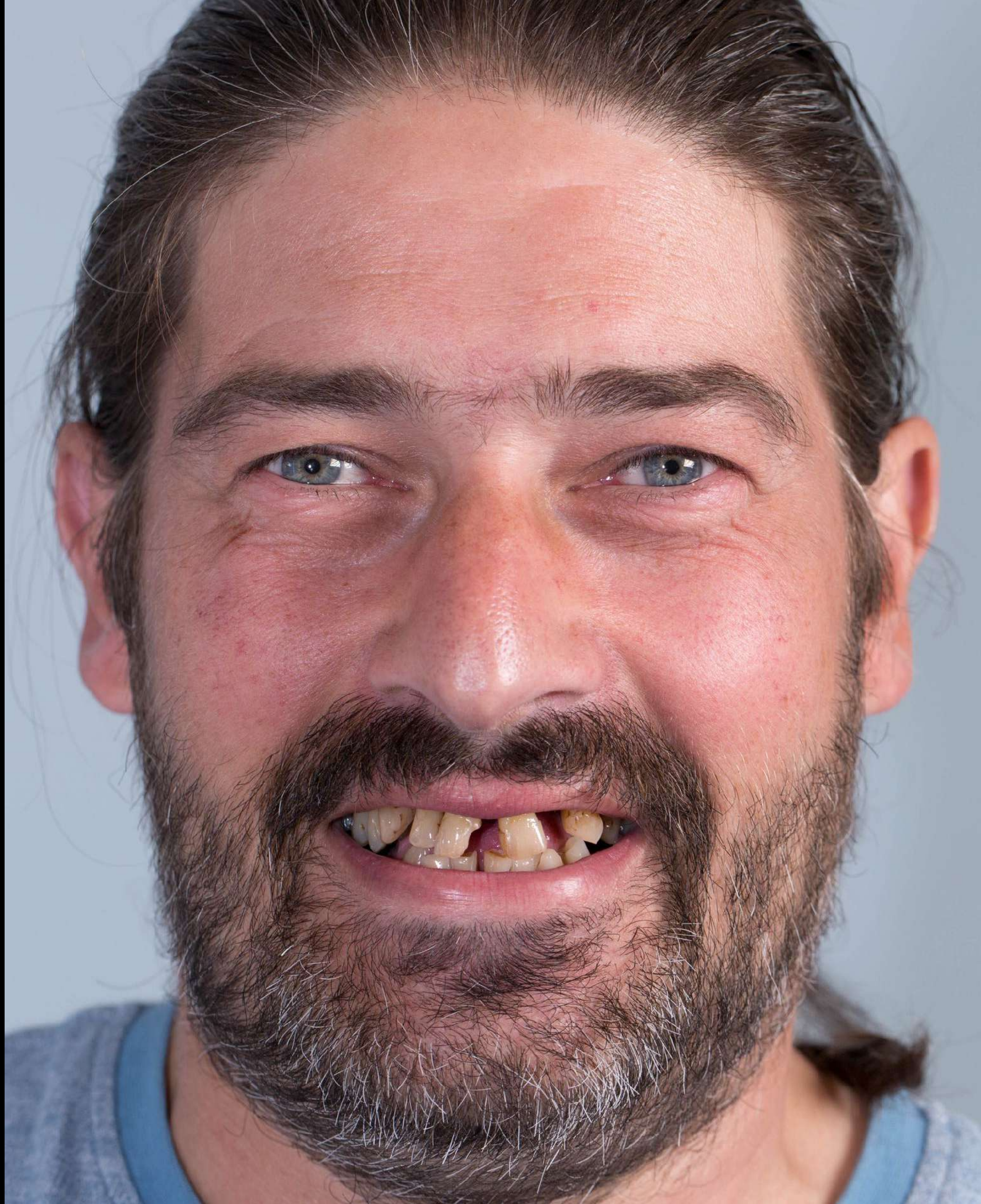

Dr John Besford

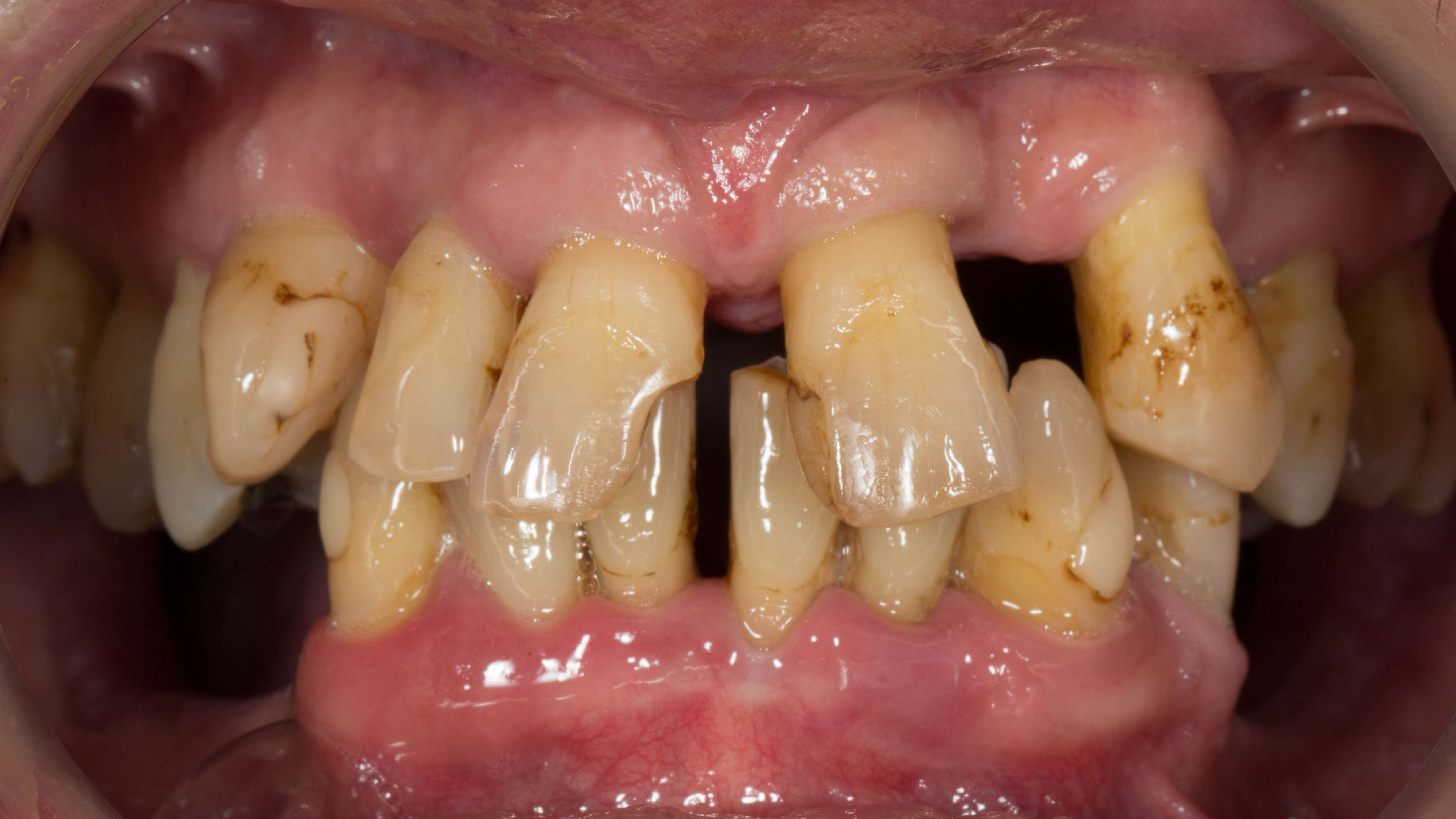Mentee

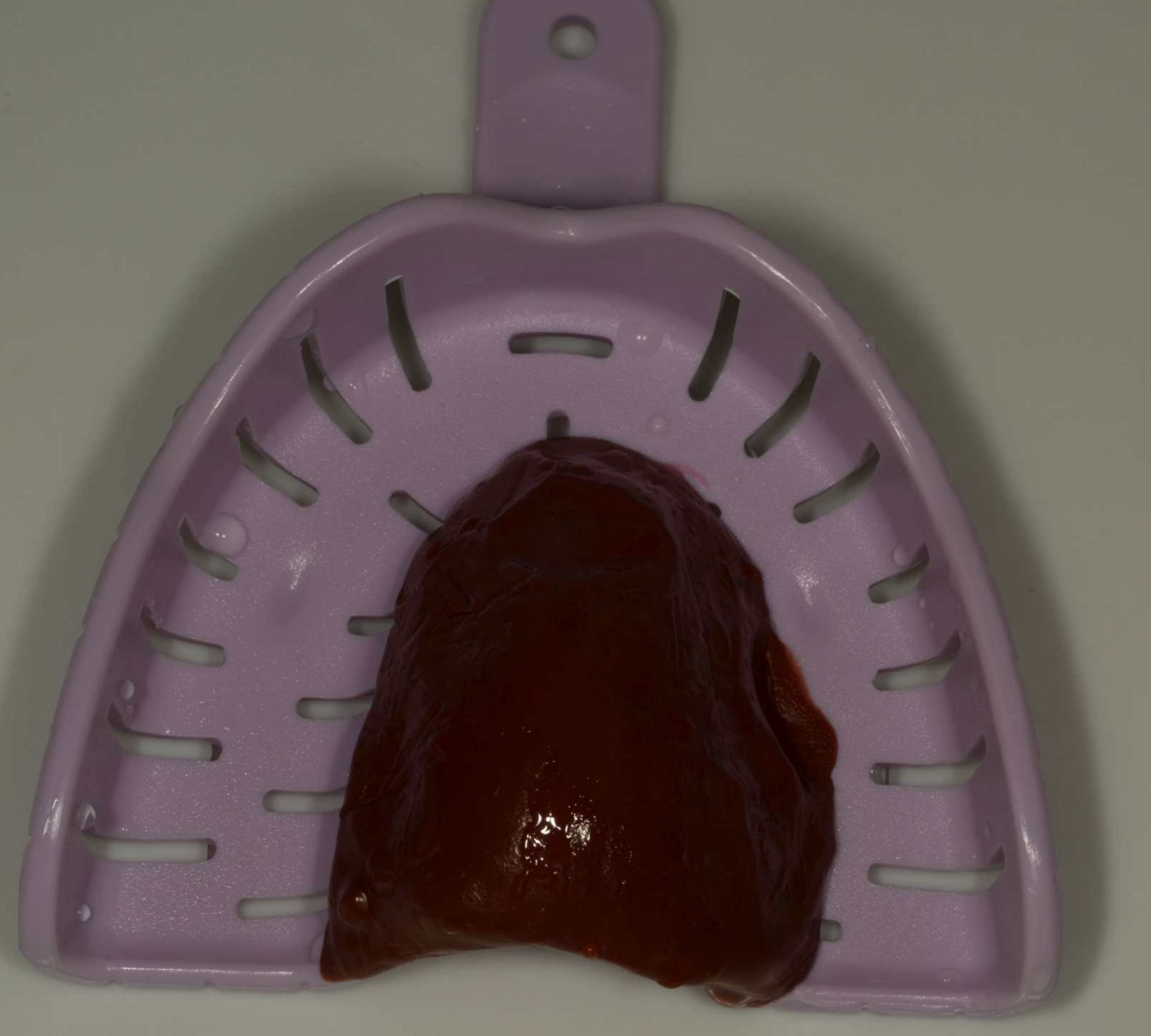Mentor

Immediate dentures

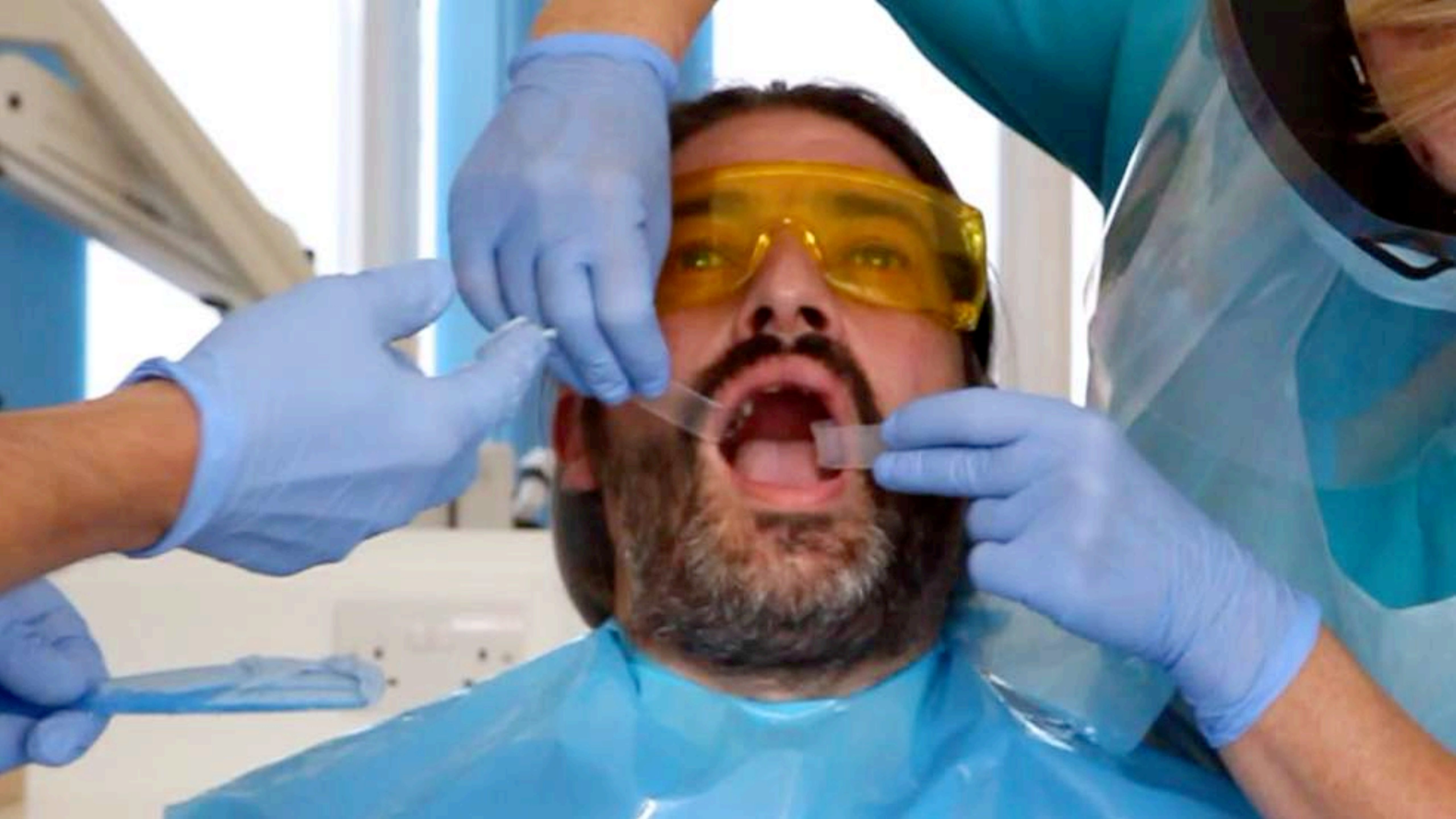

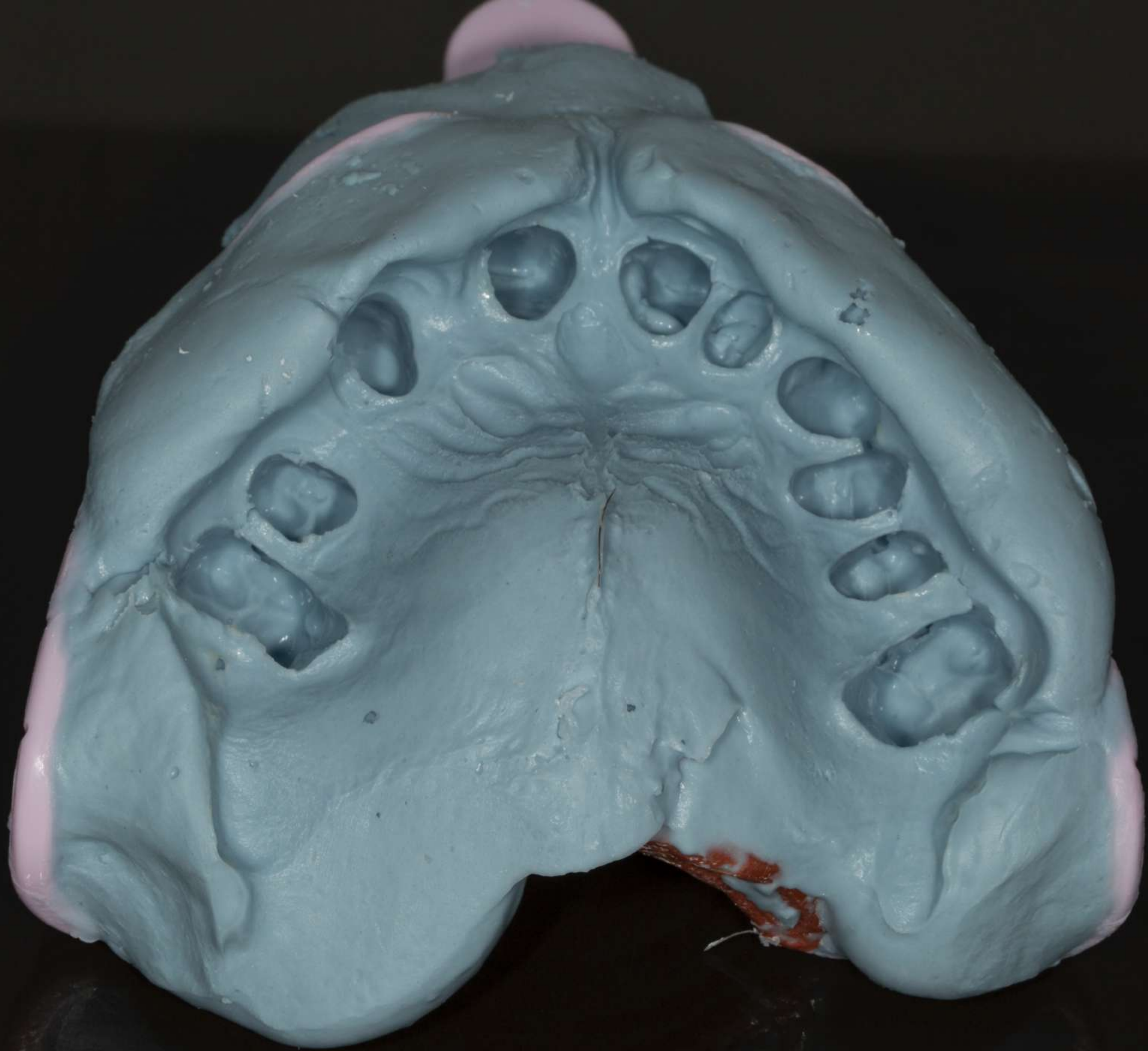
Xavier

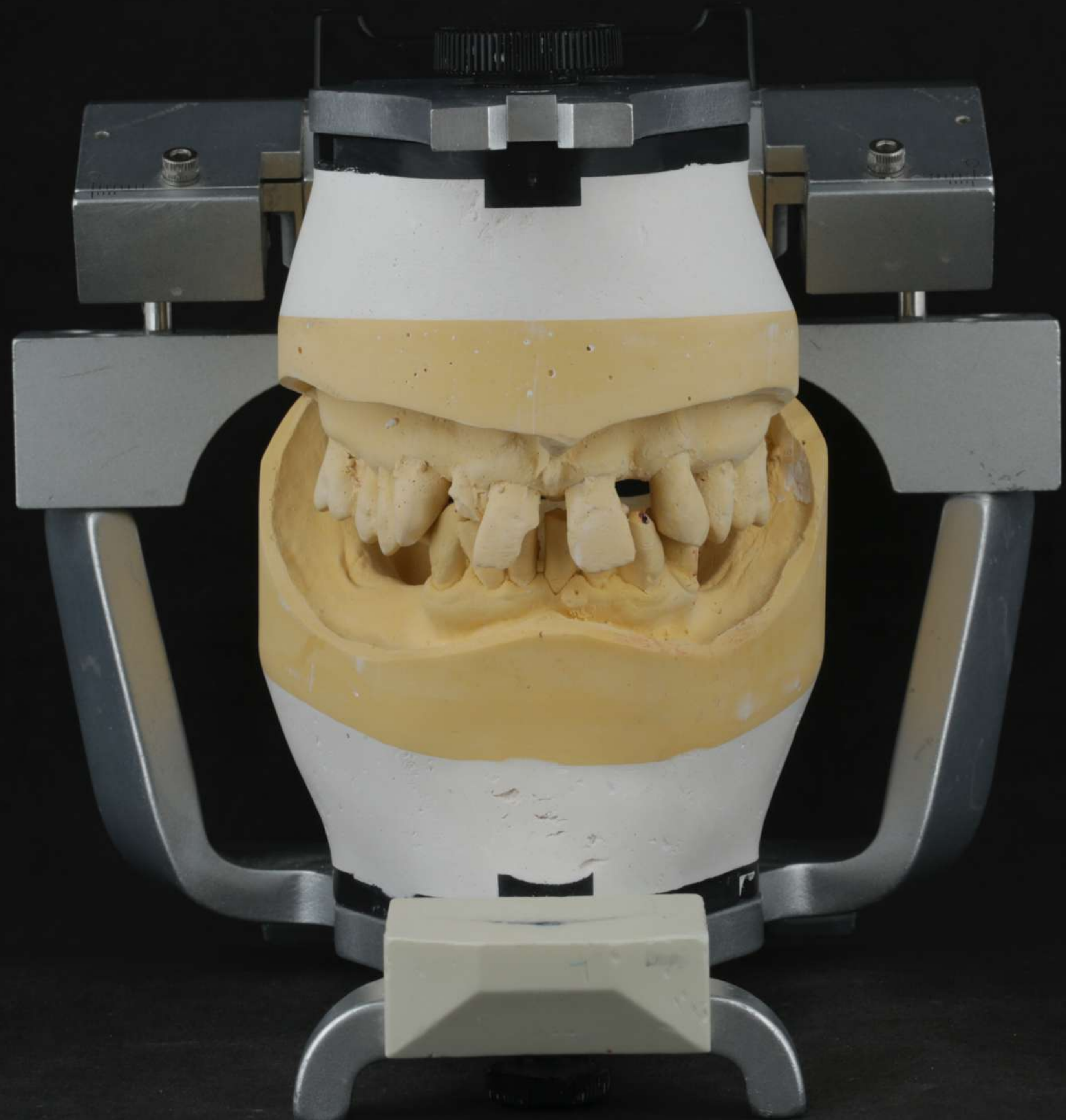


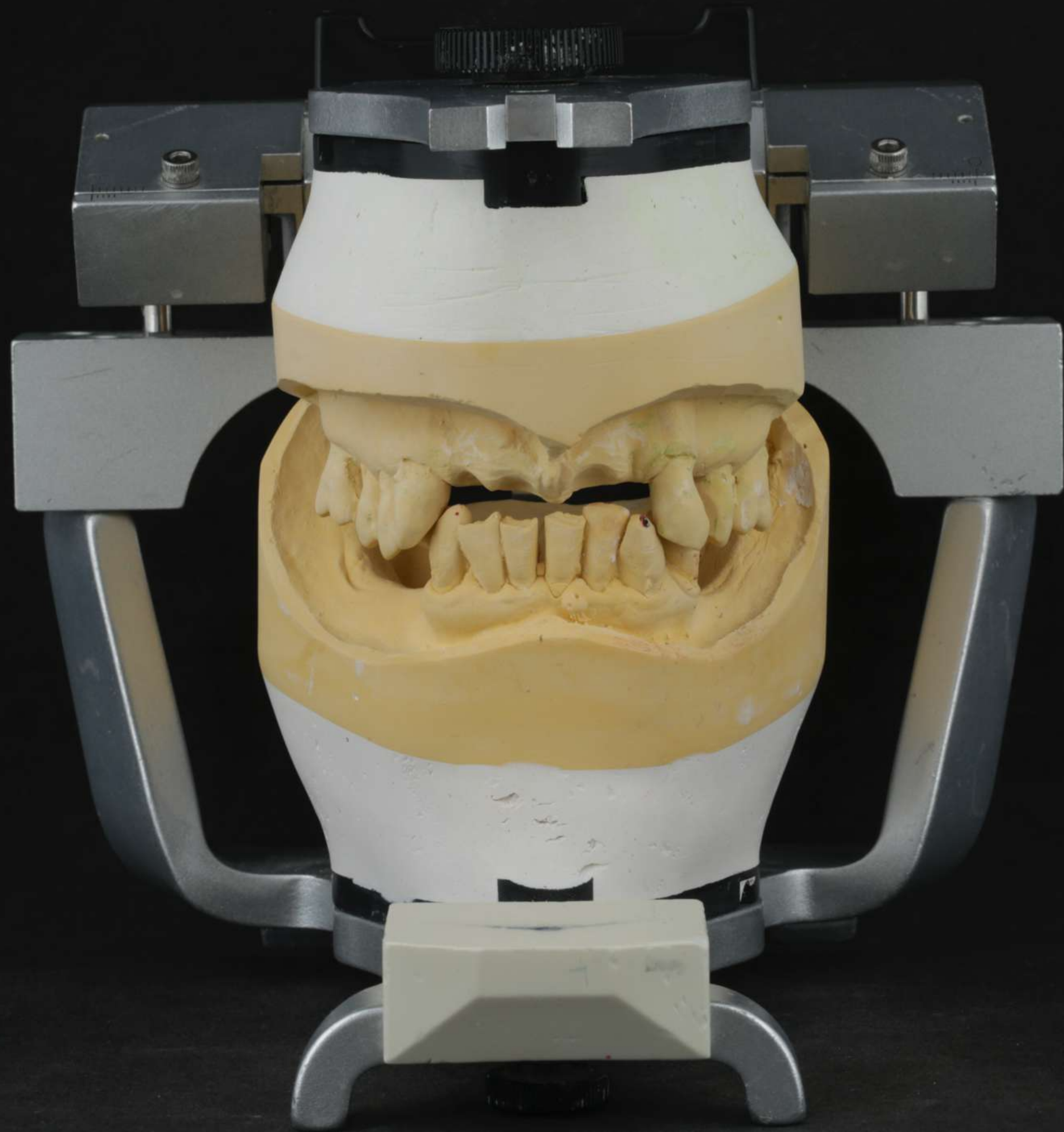
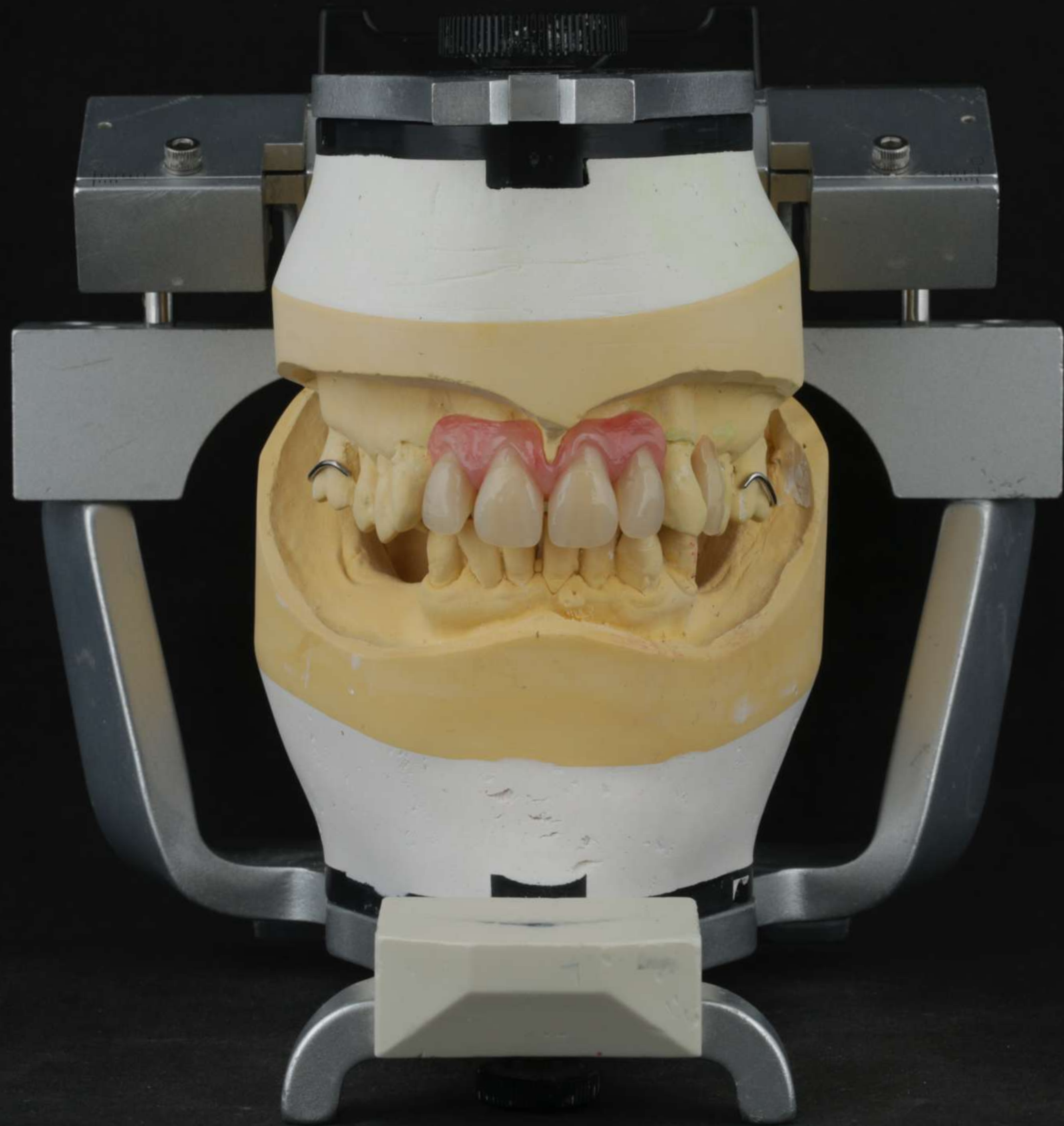Red
Compound



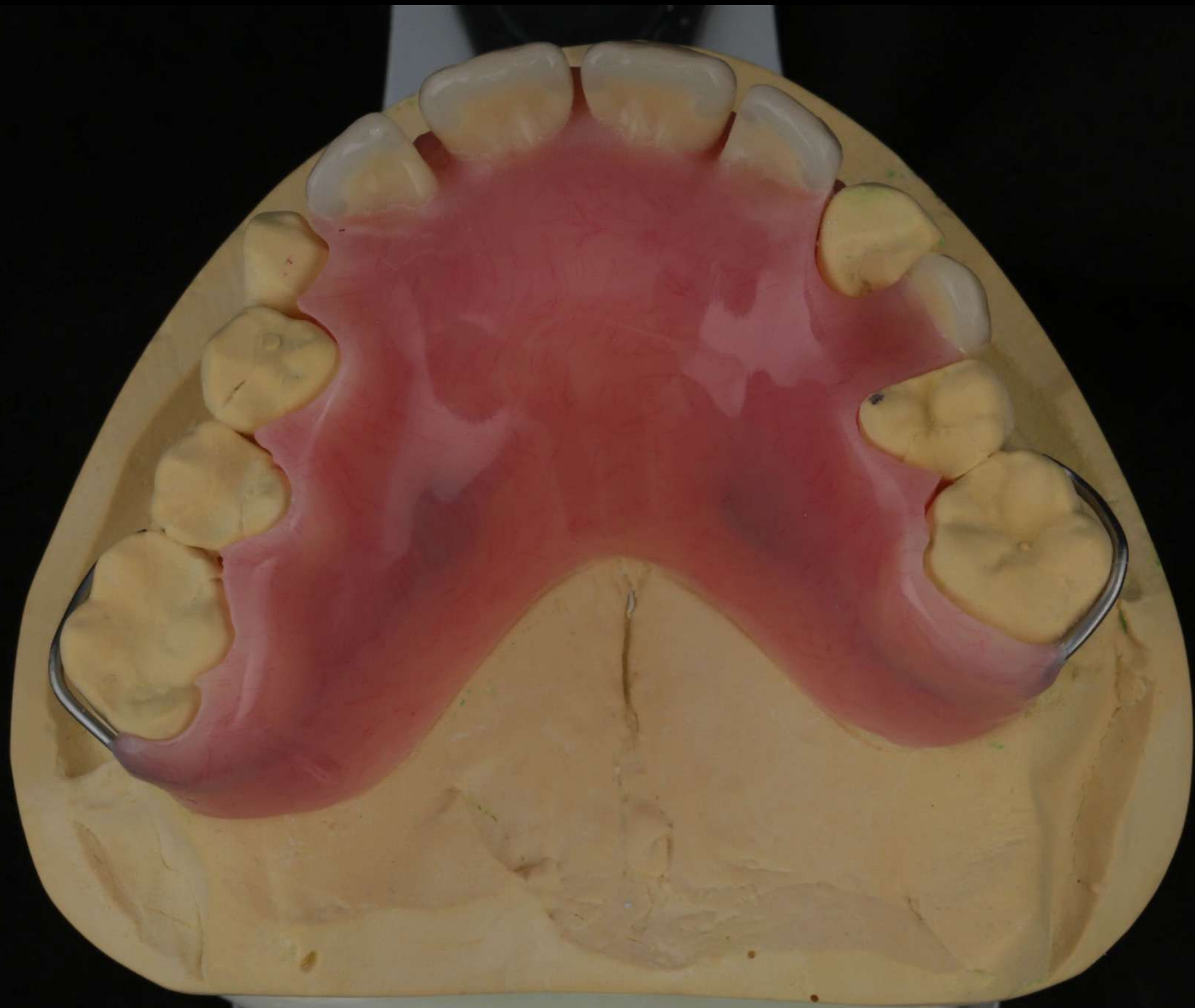

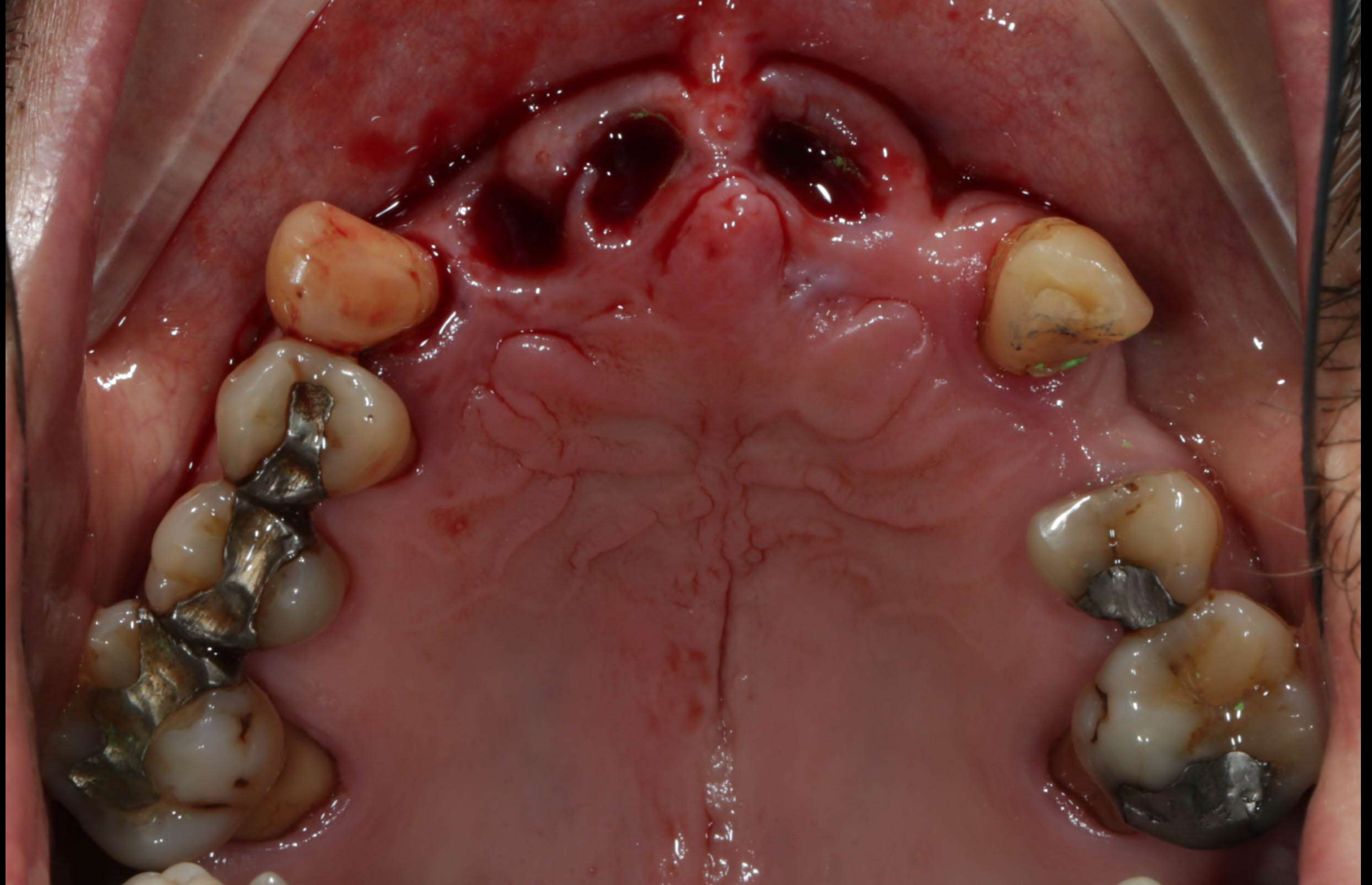



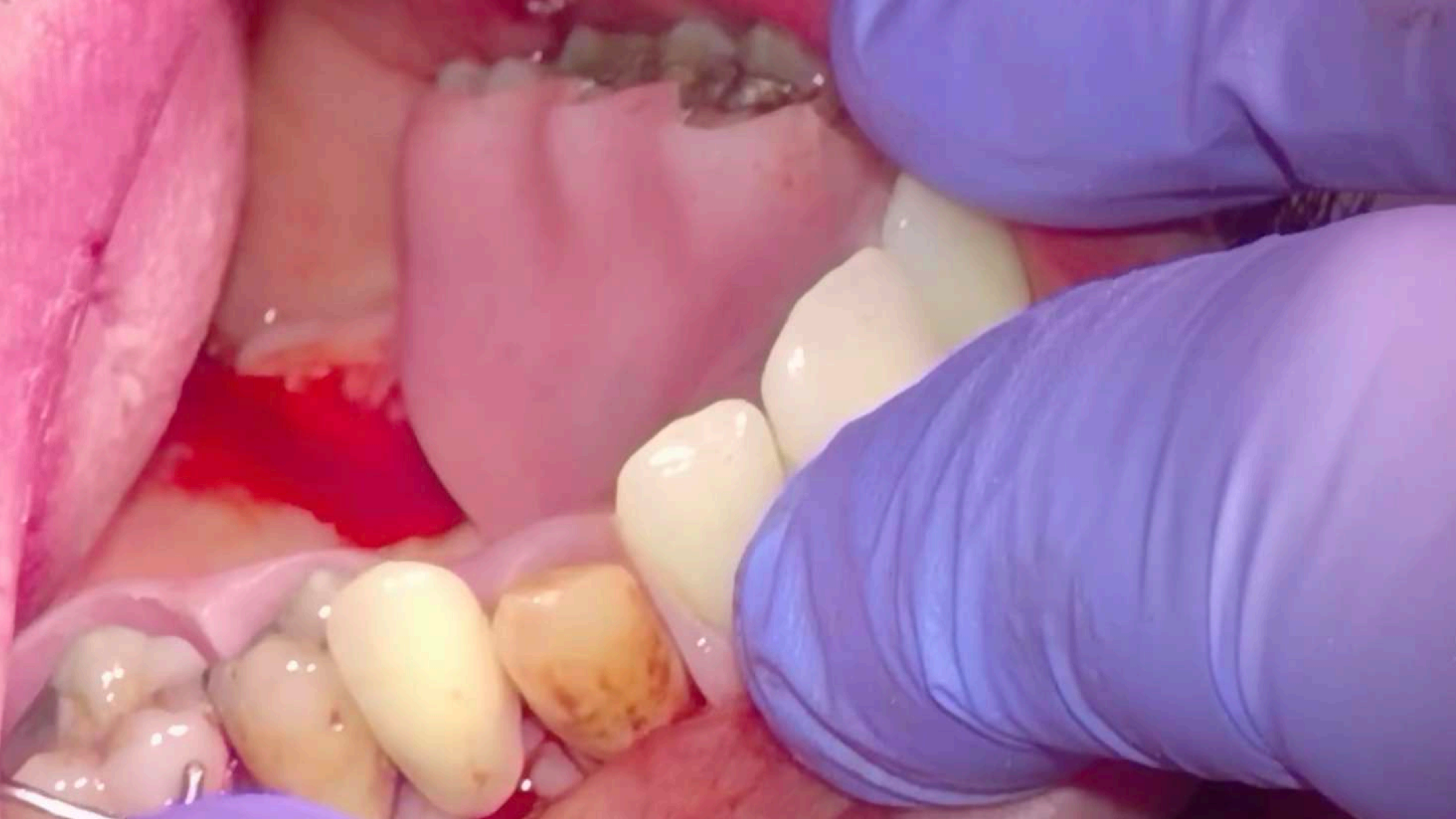
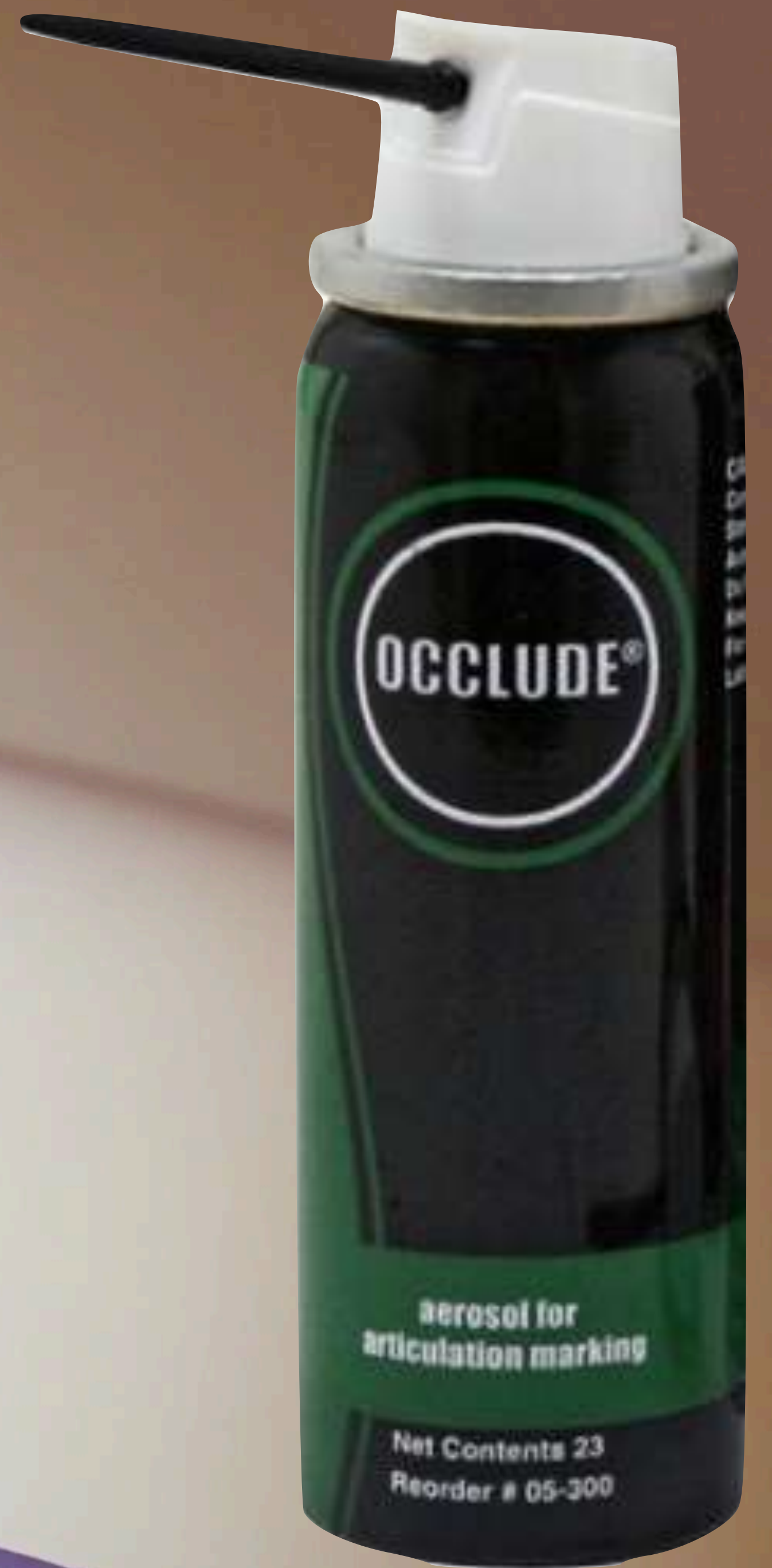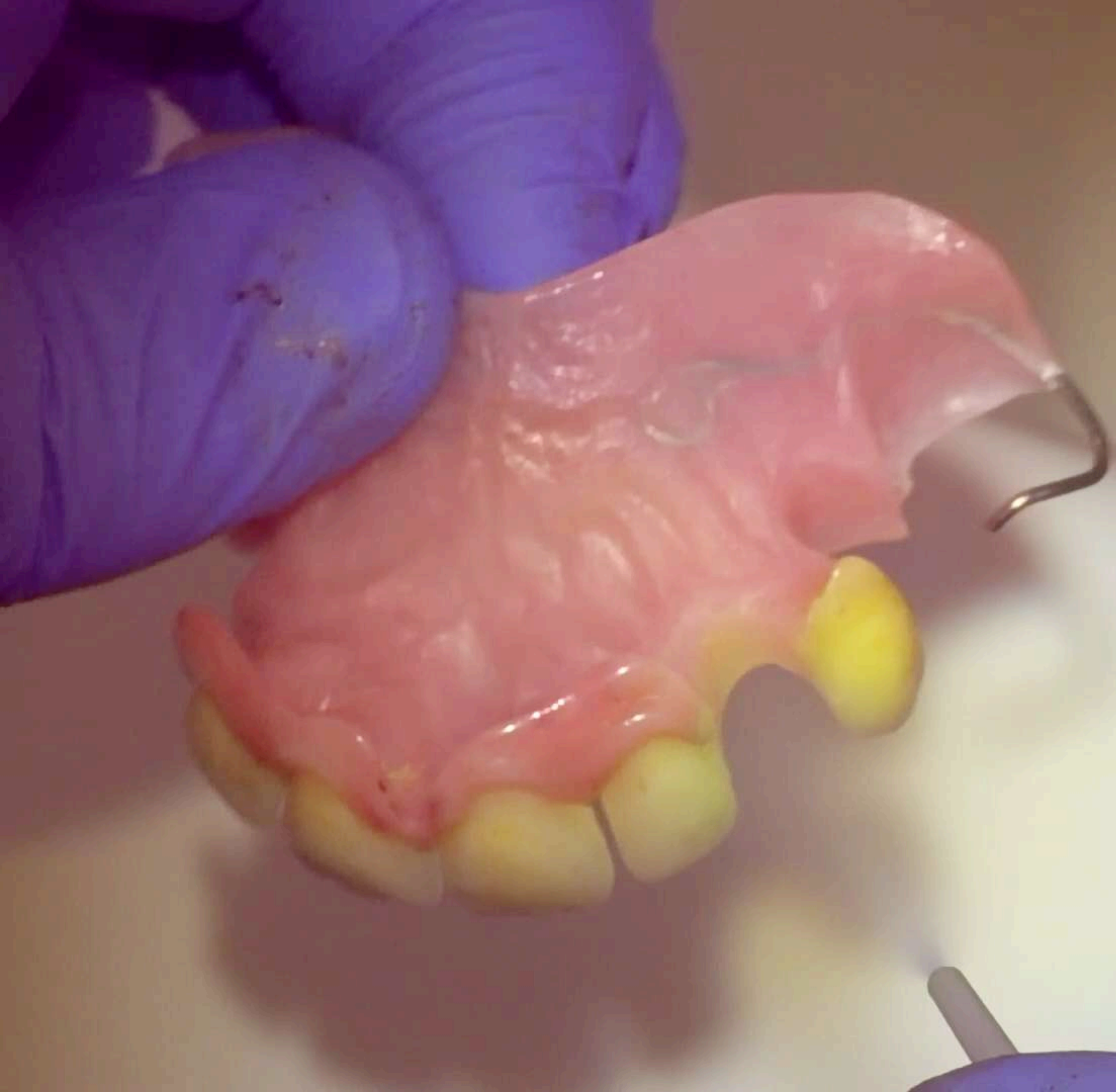




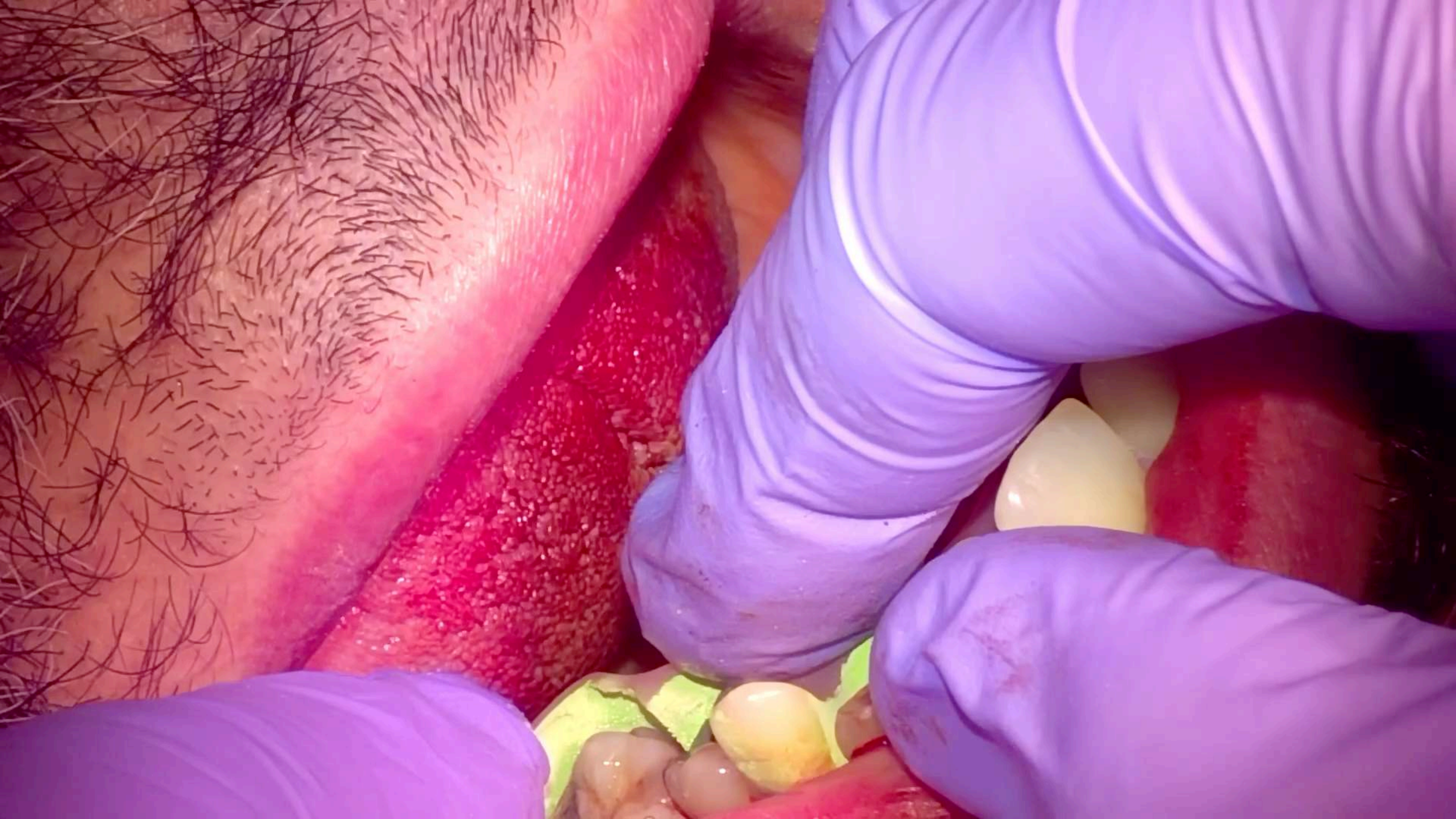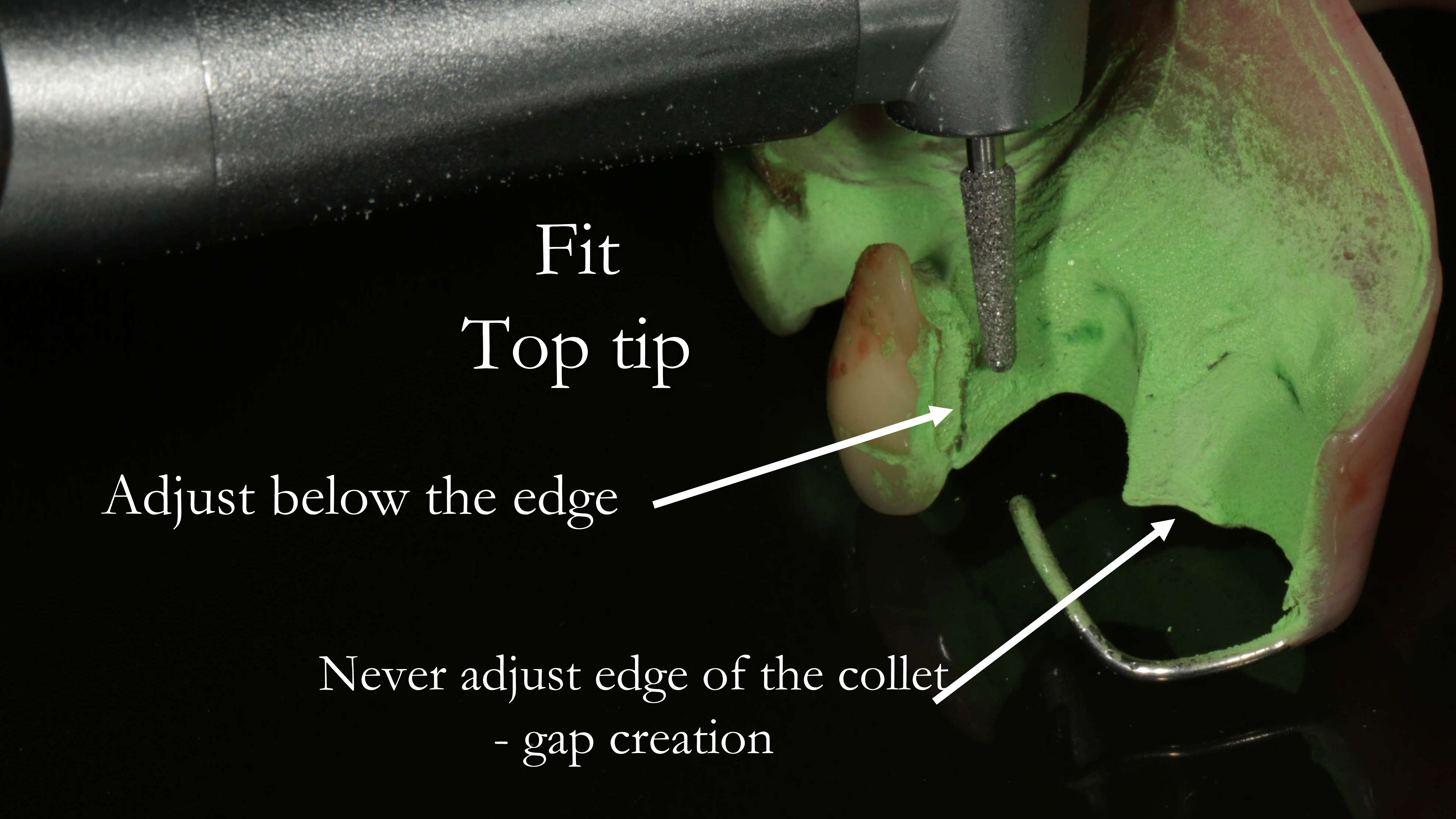








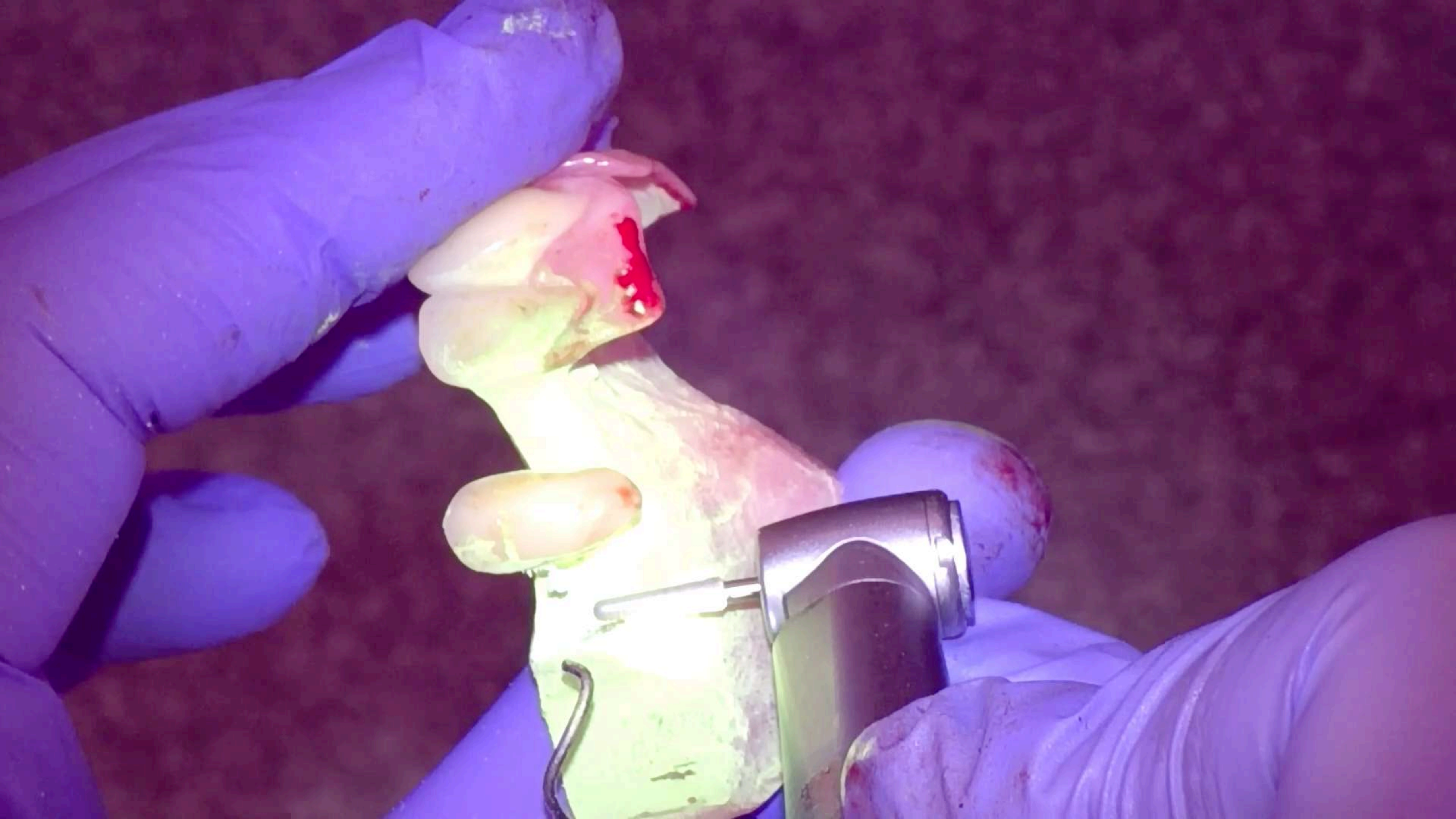




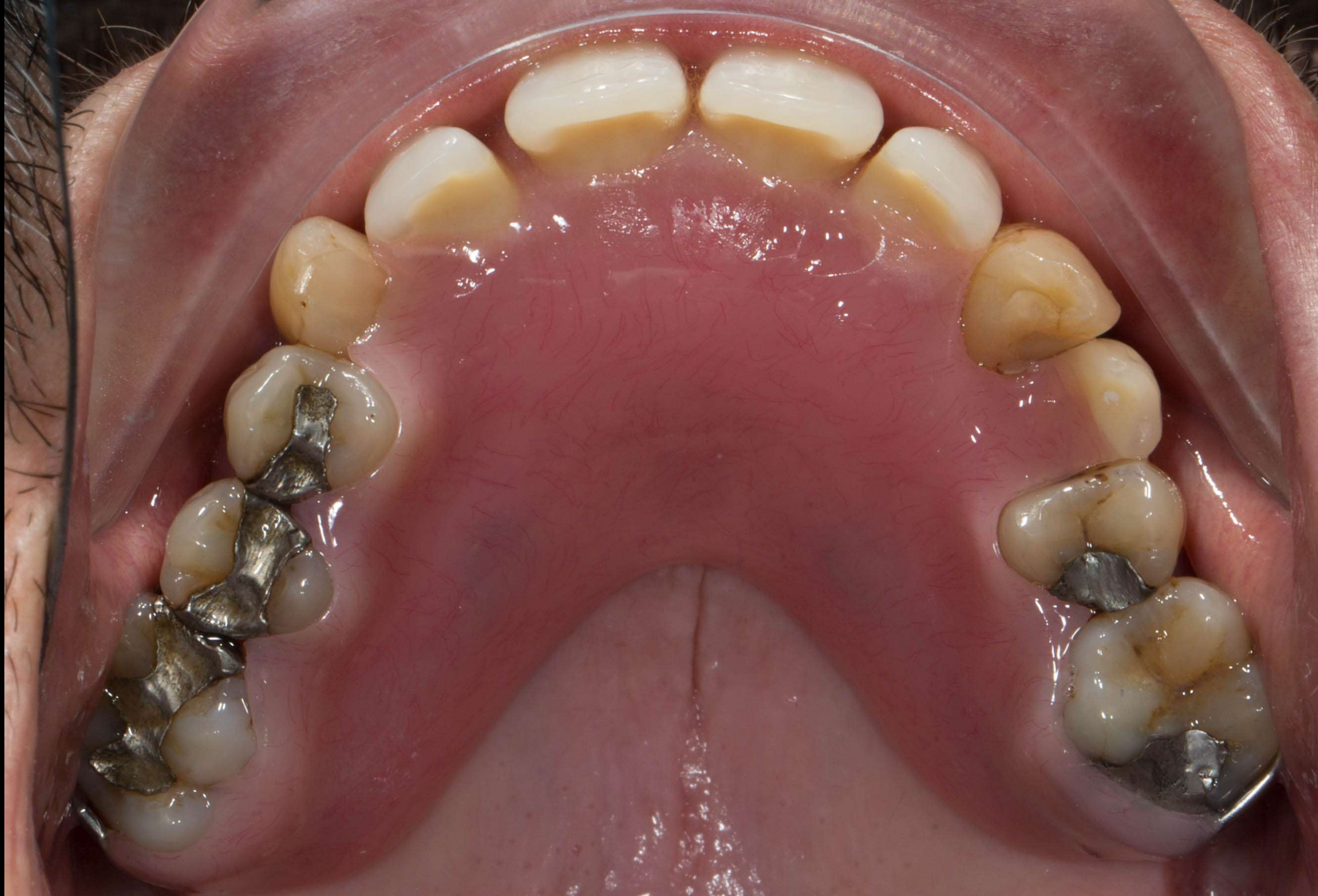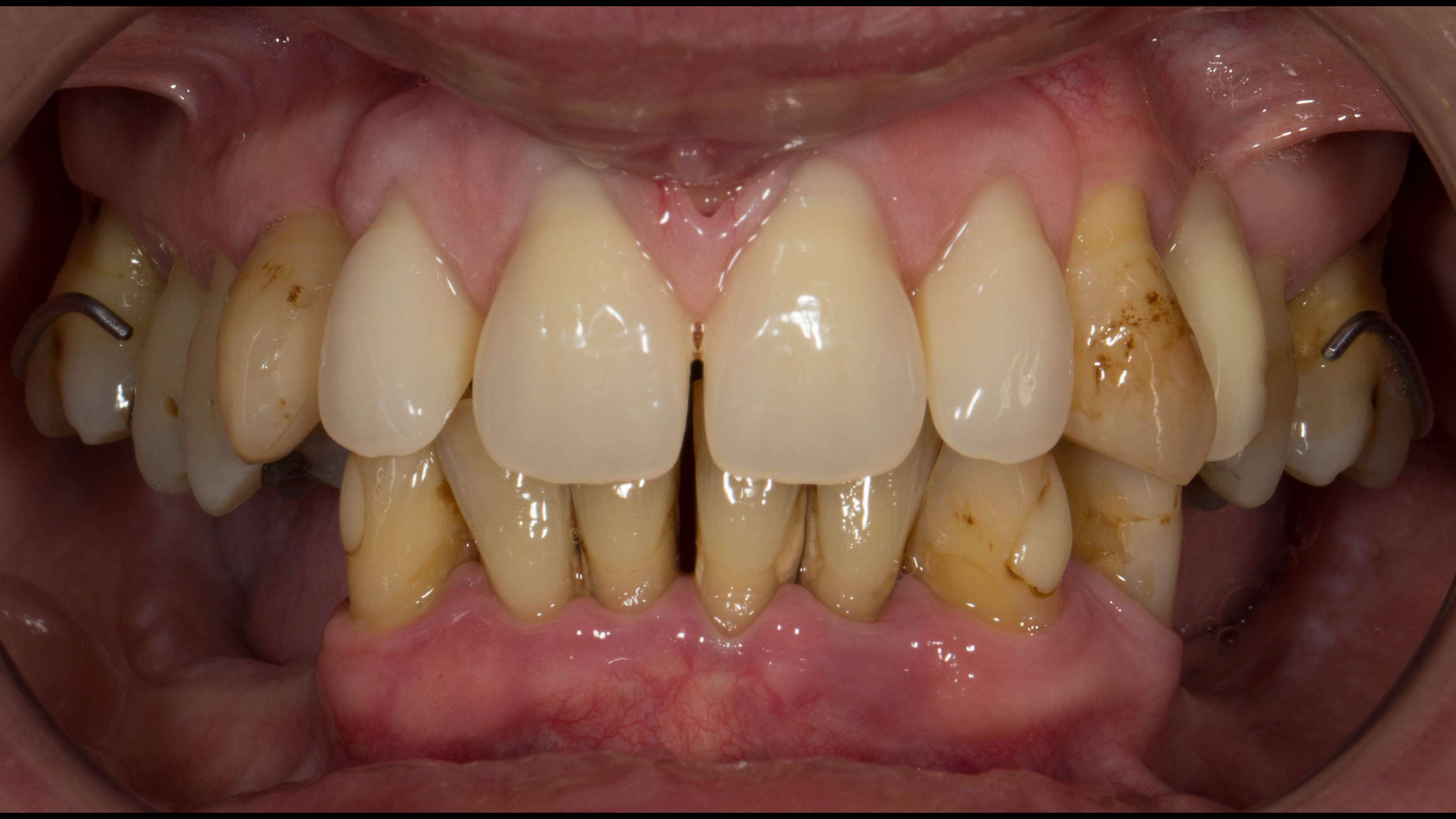Fit
Top tip

Adjust below the edge

Never adjust edge of the collet
- gap creation



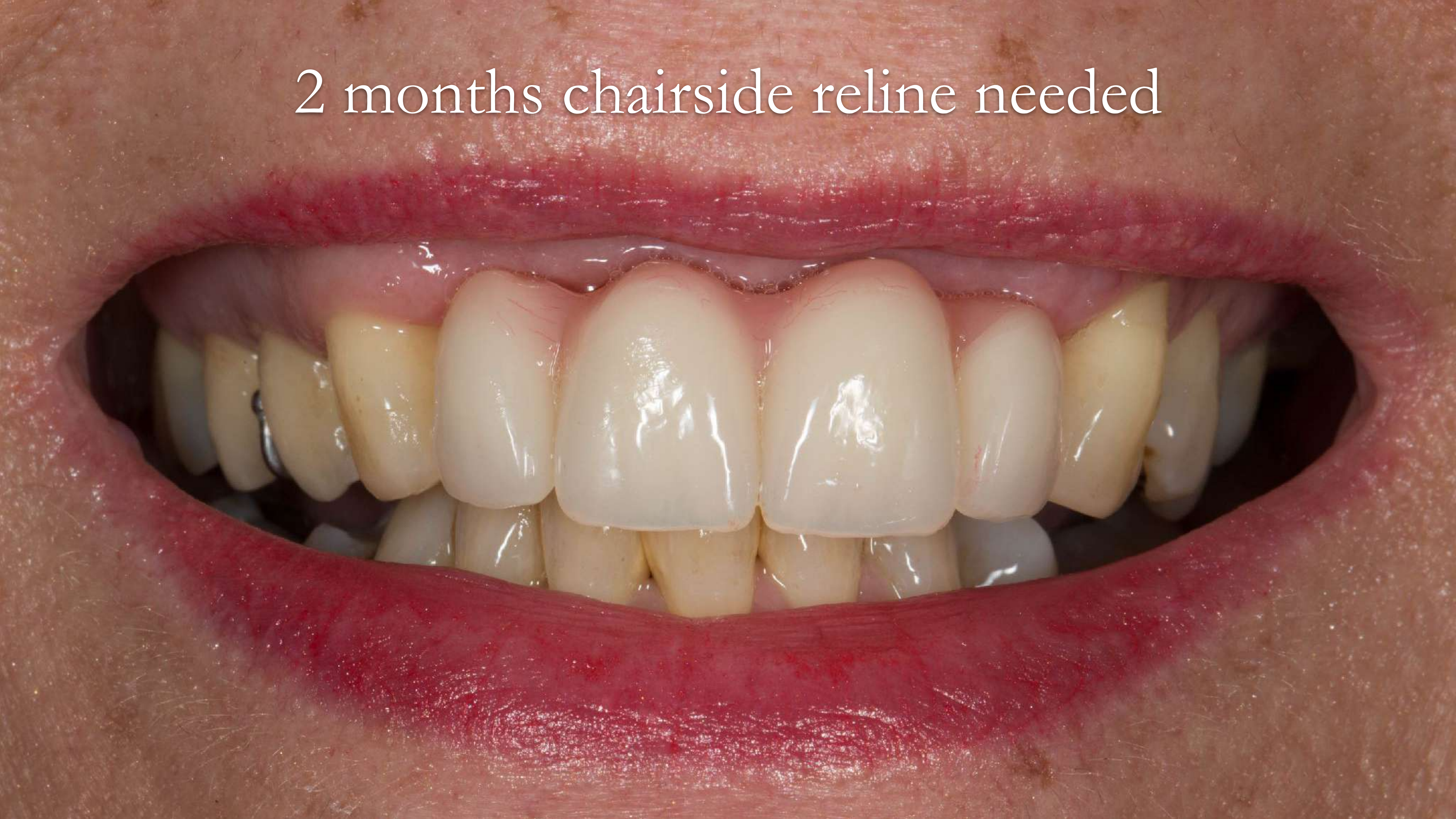




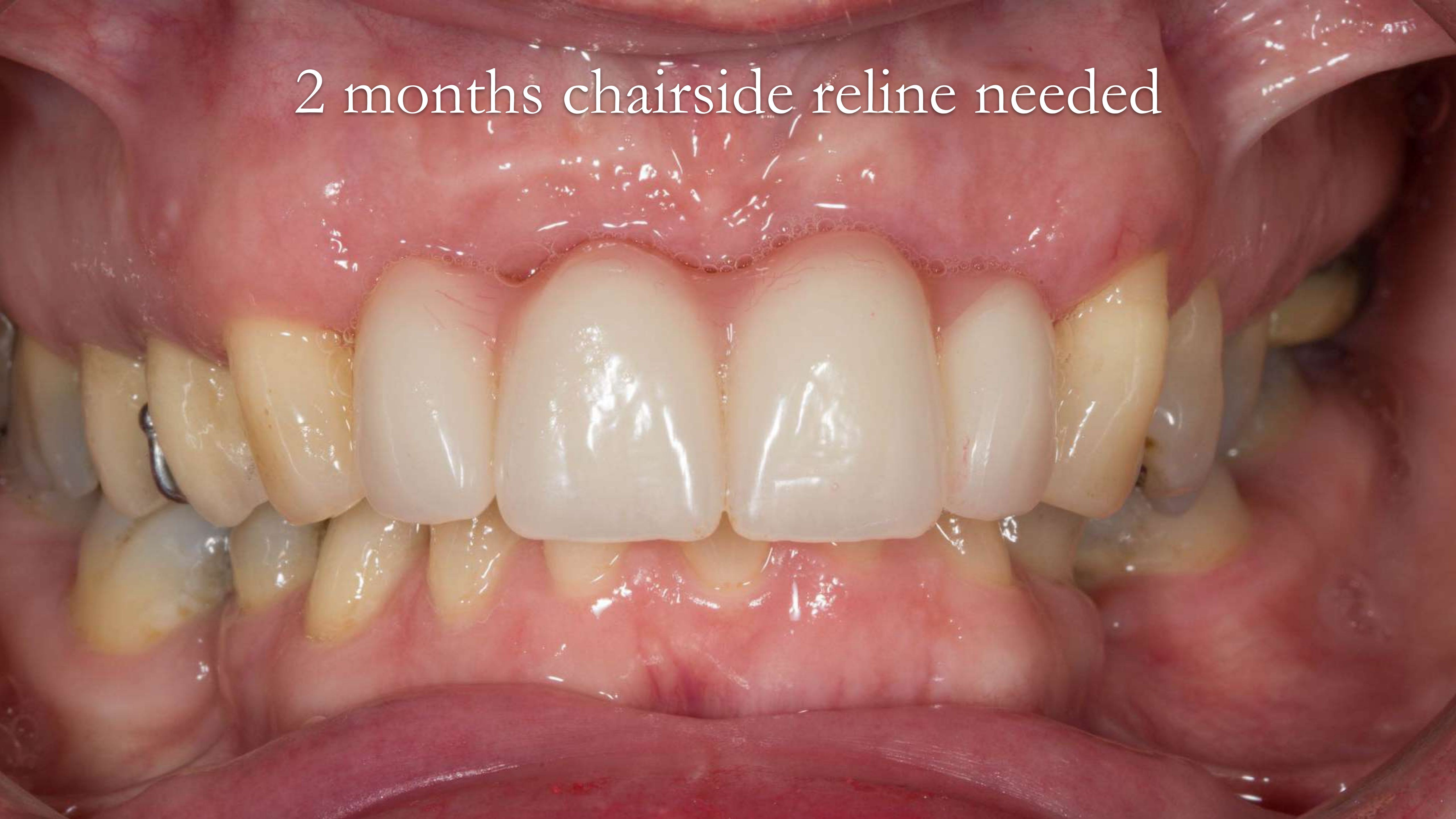
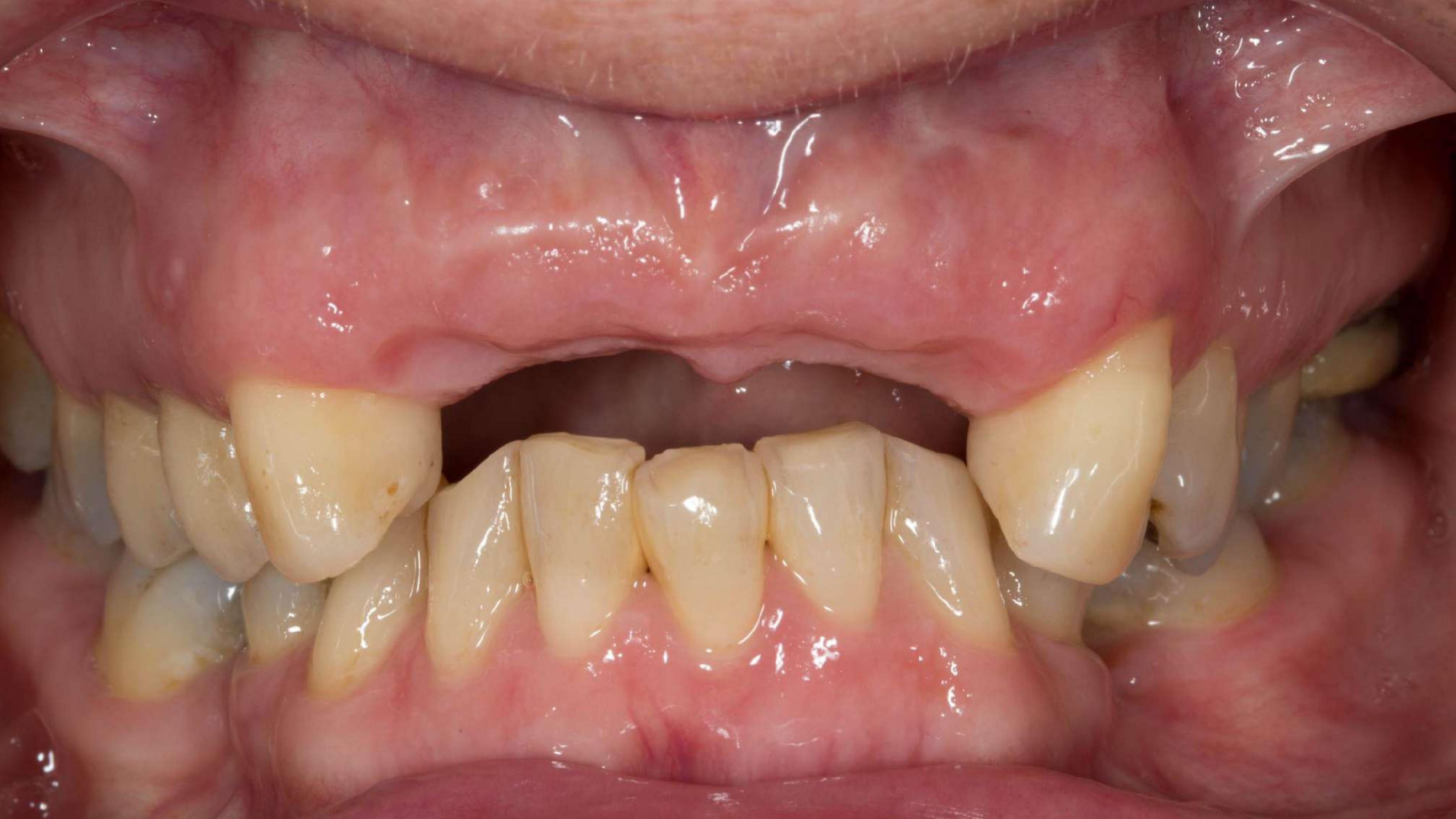Relining partial dentures

2 months chairside reline needed



2 months chairside reline needed

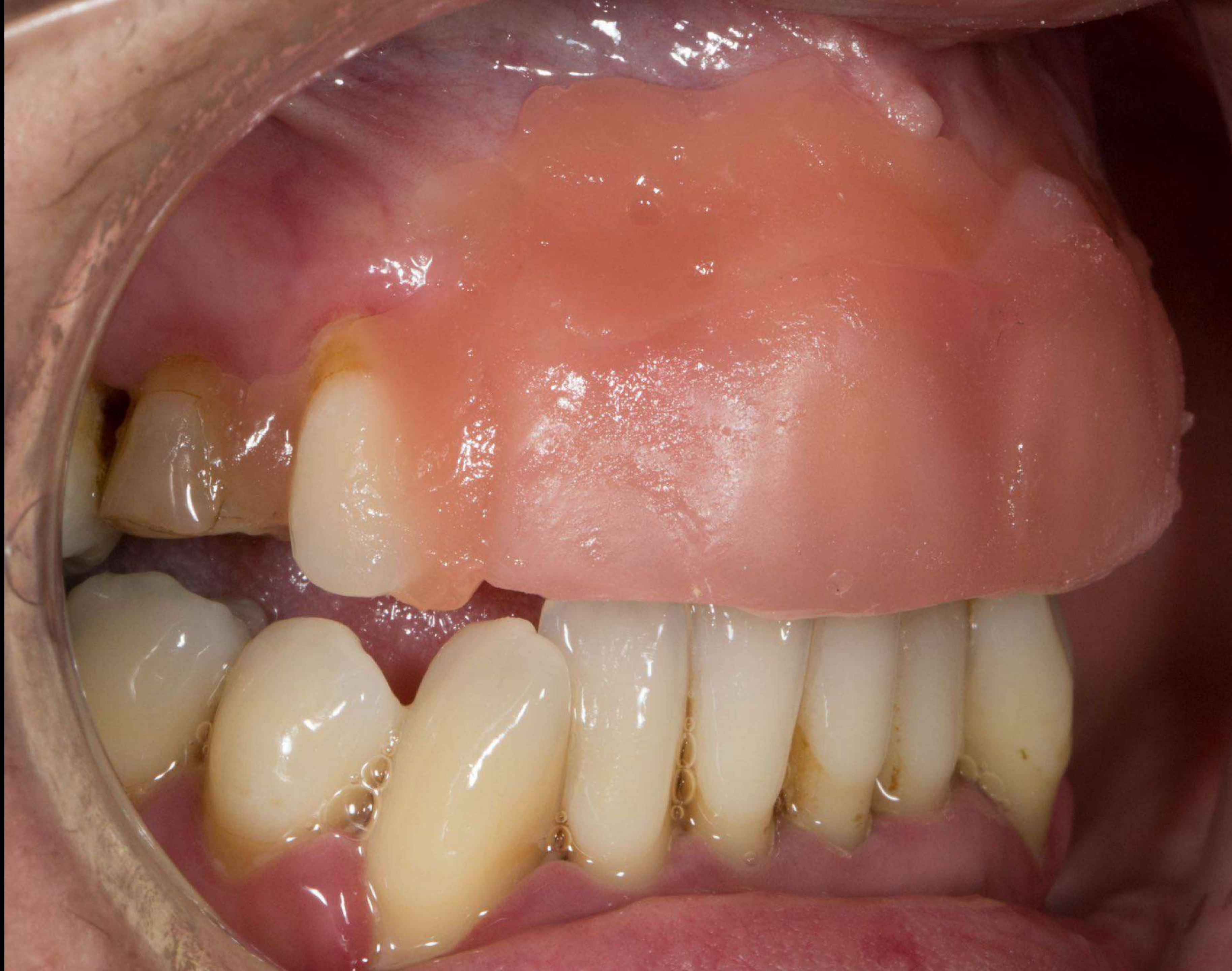


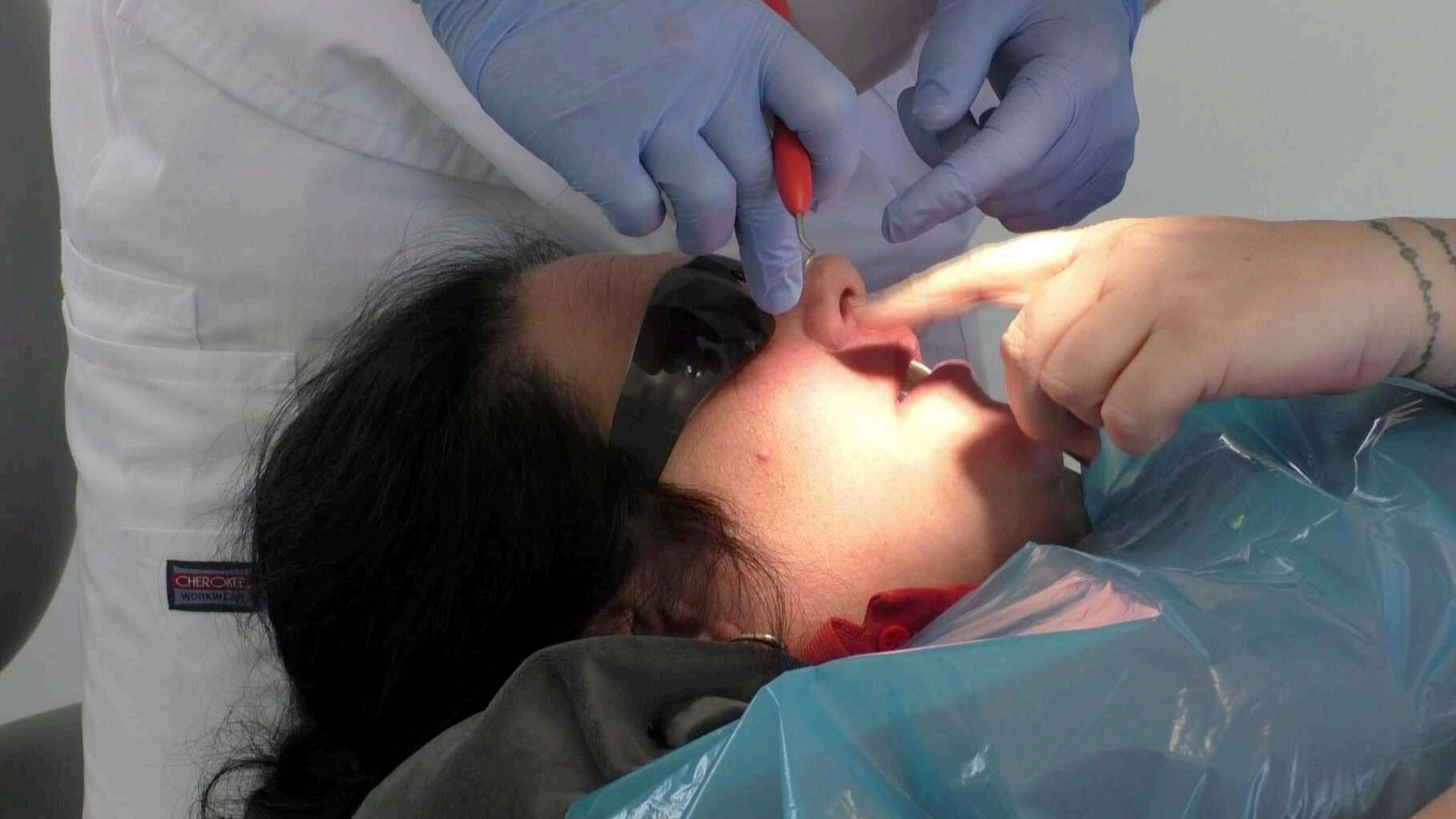
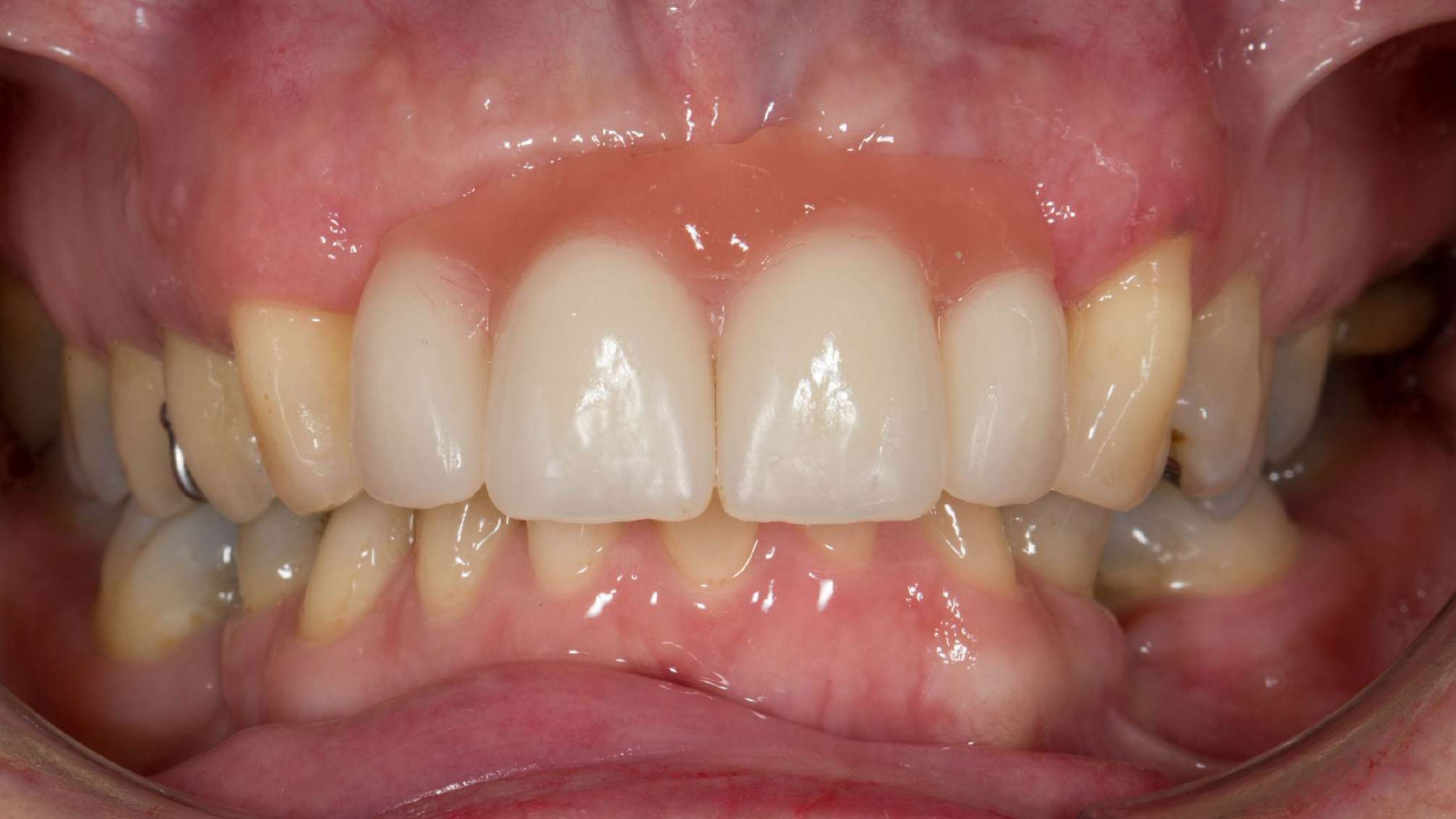UFI Gel reline material

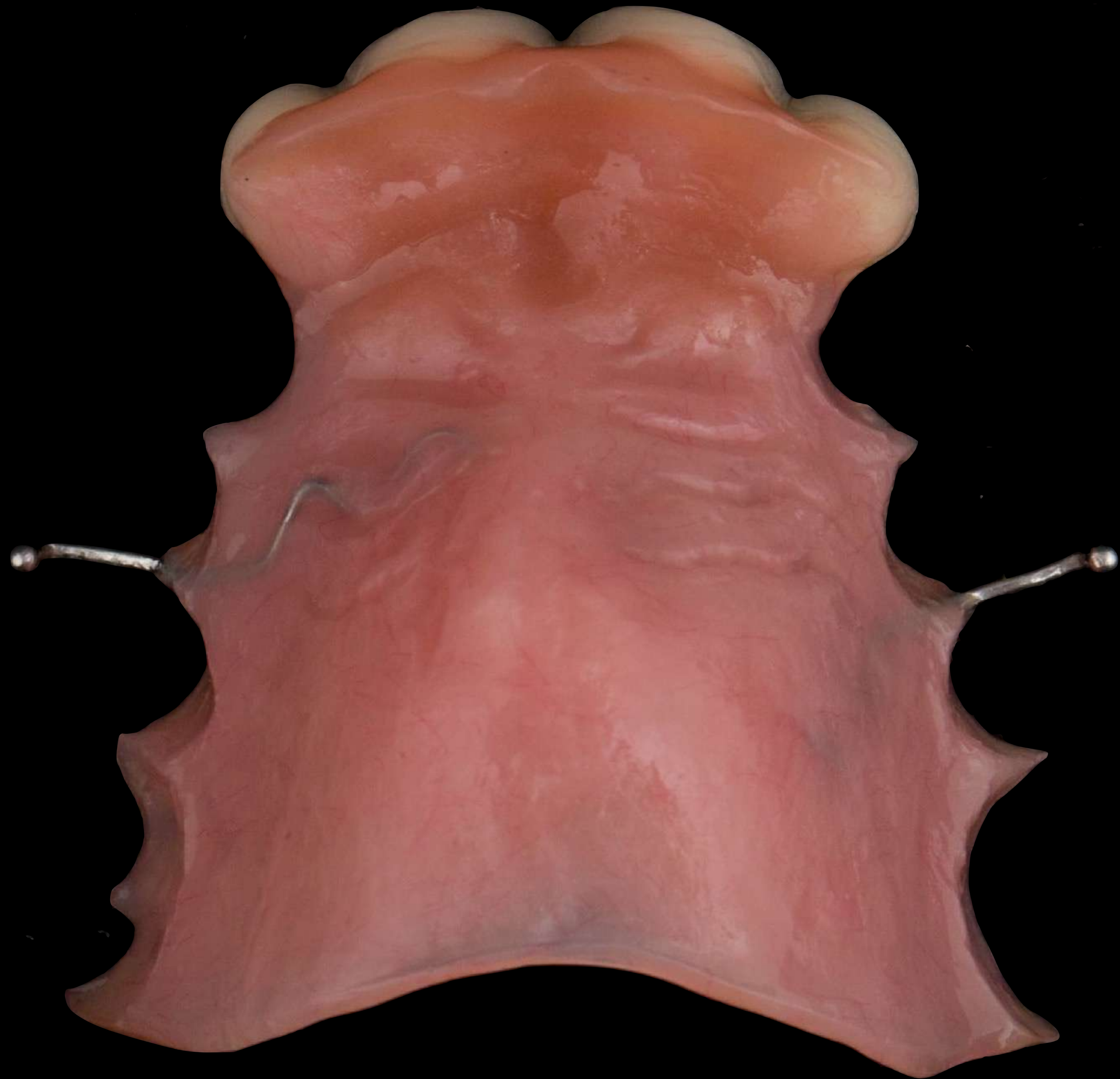


Wax blocking out teeth





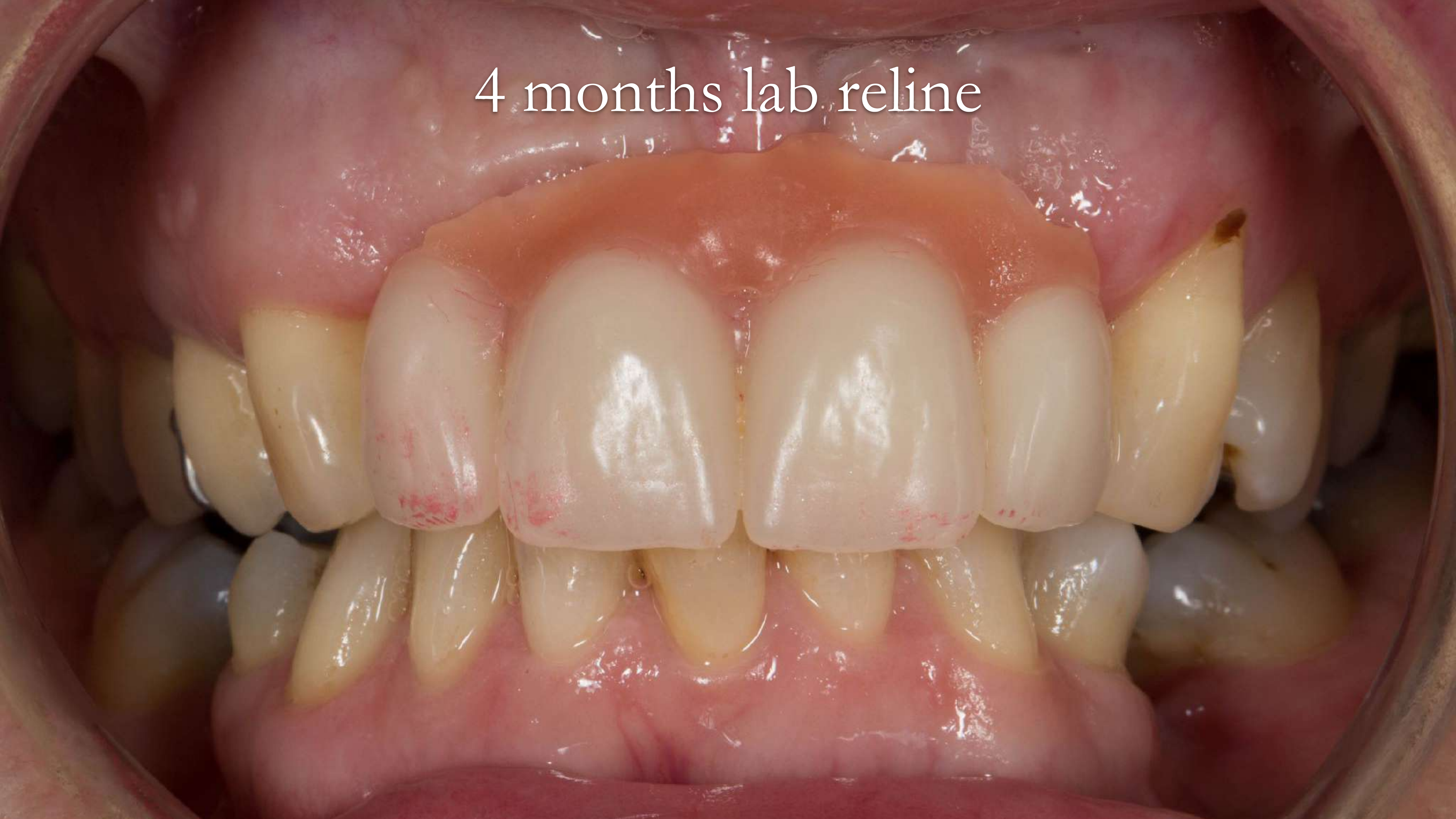


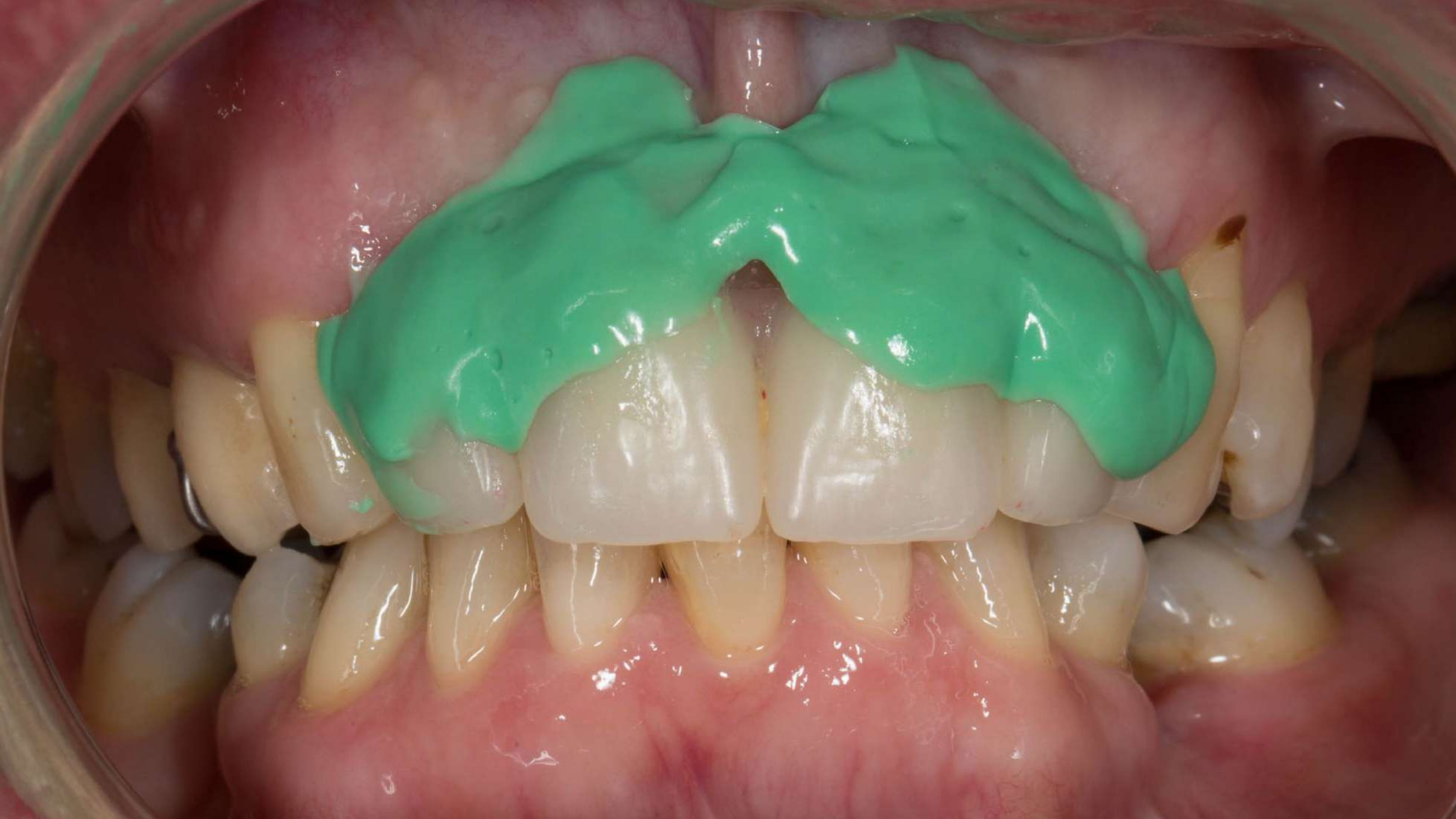
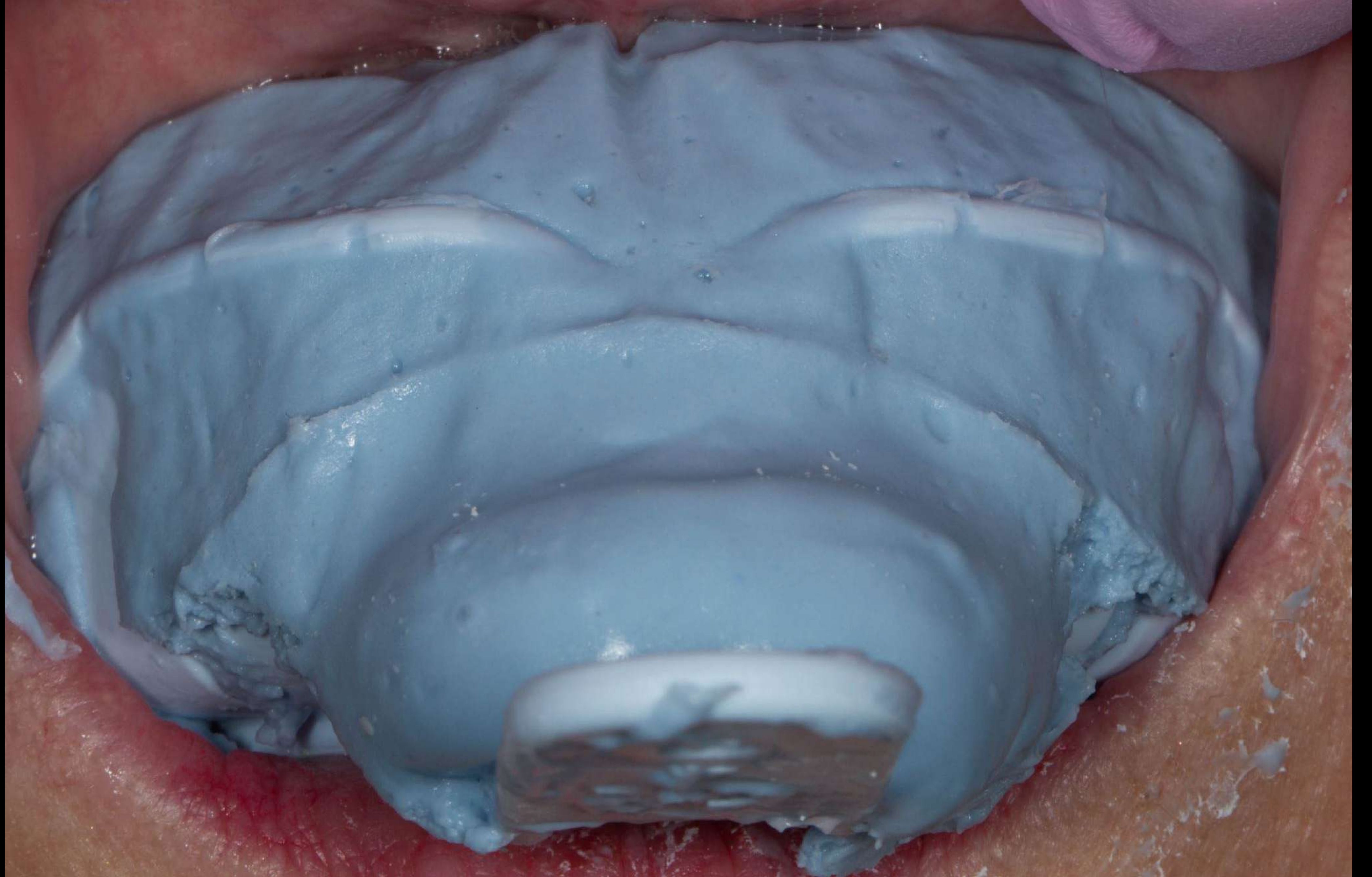Immediate P/P lab reline

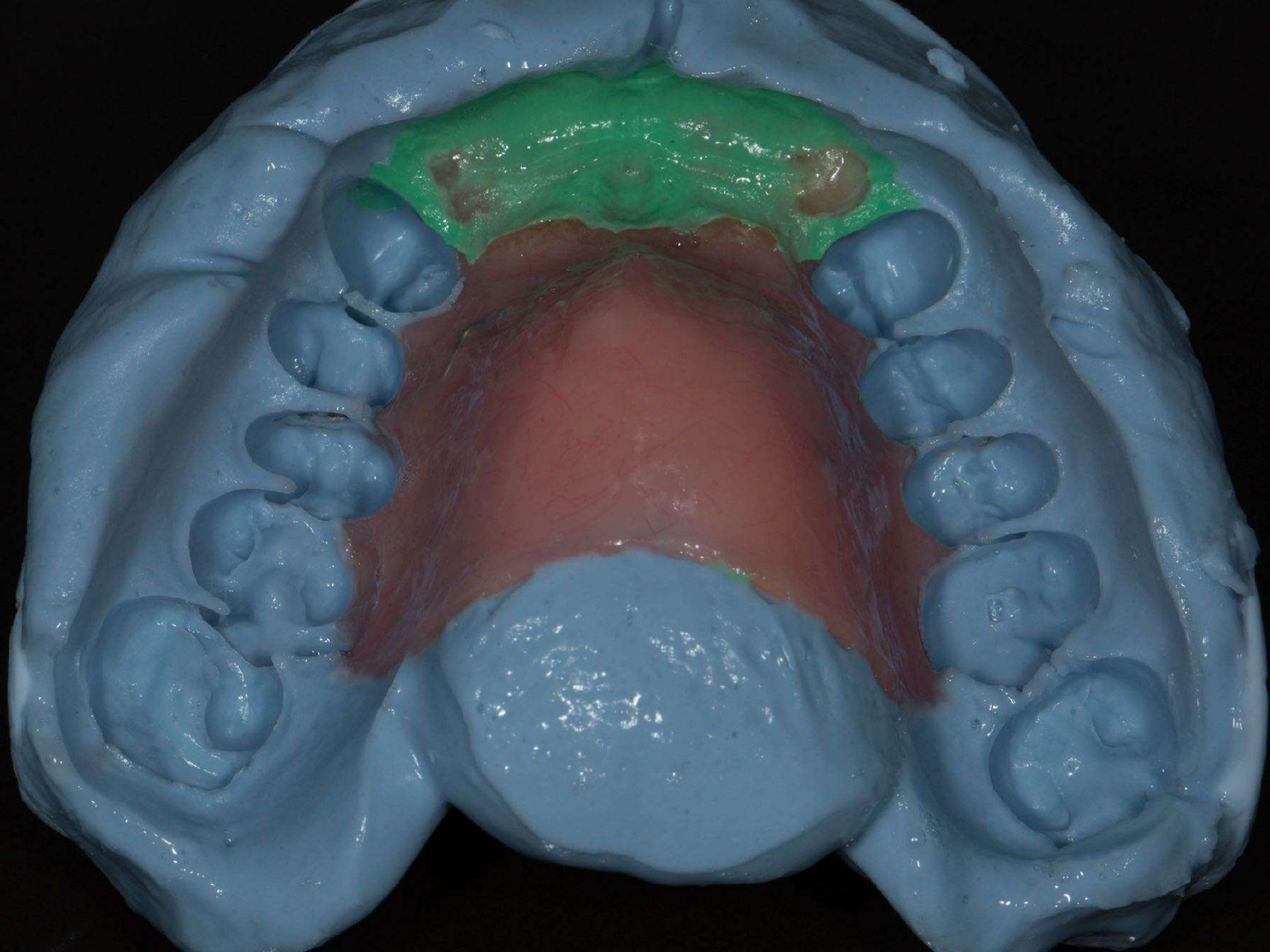
4 months

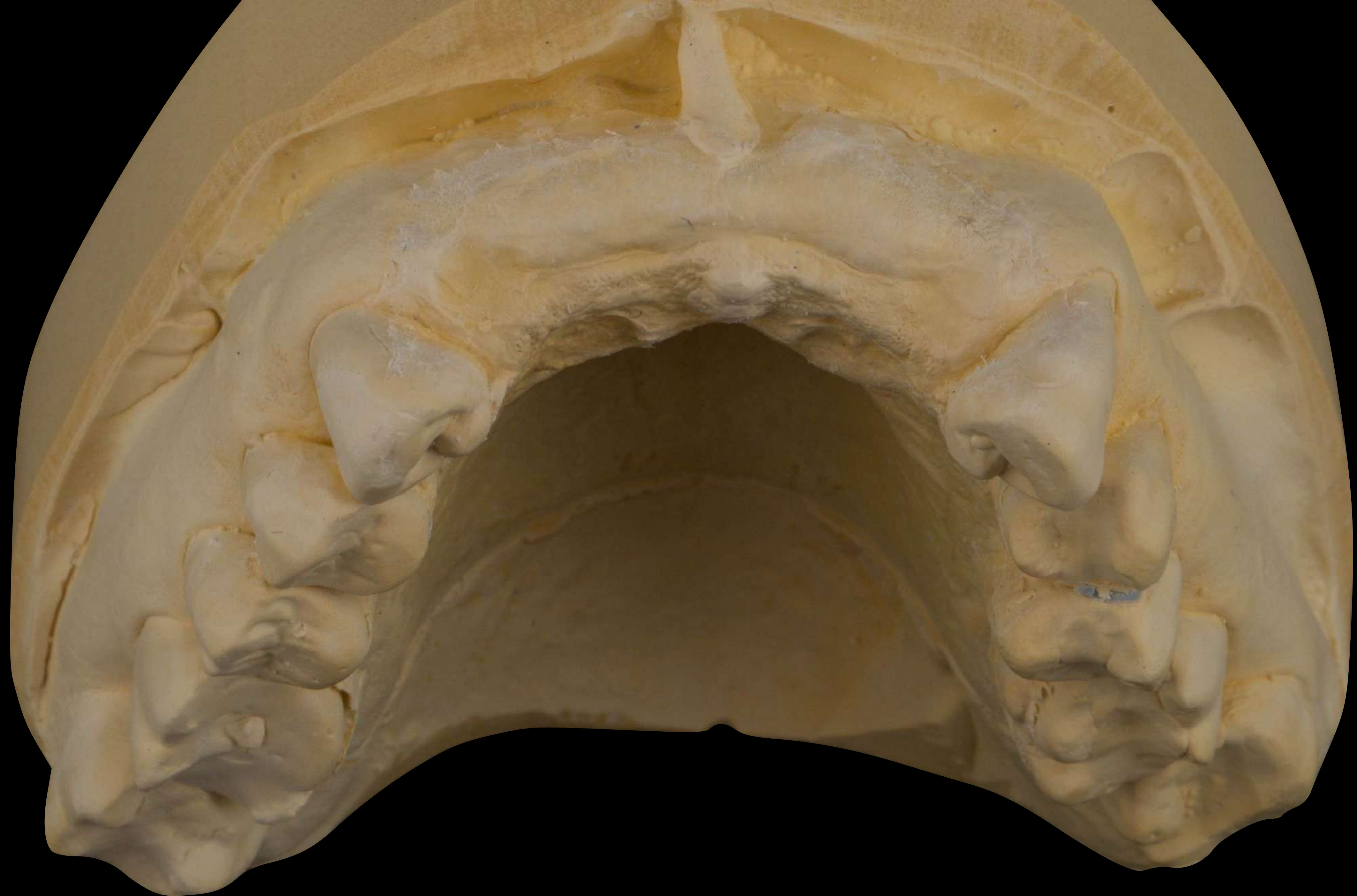4 months lab reline

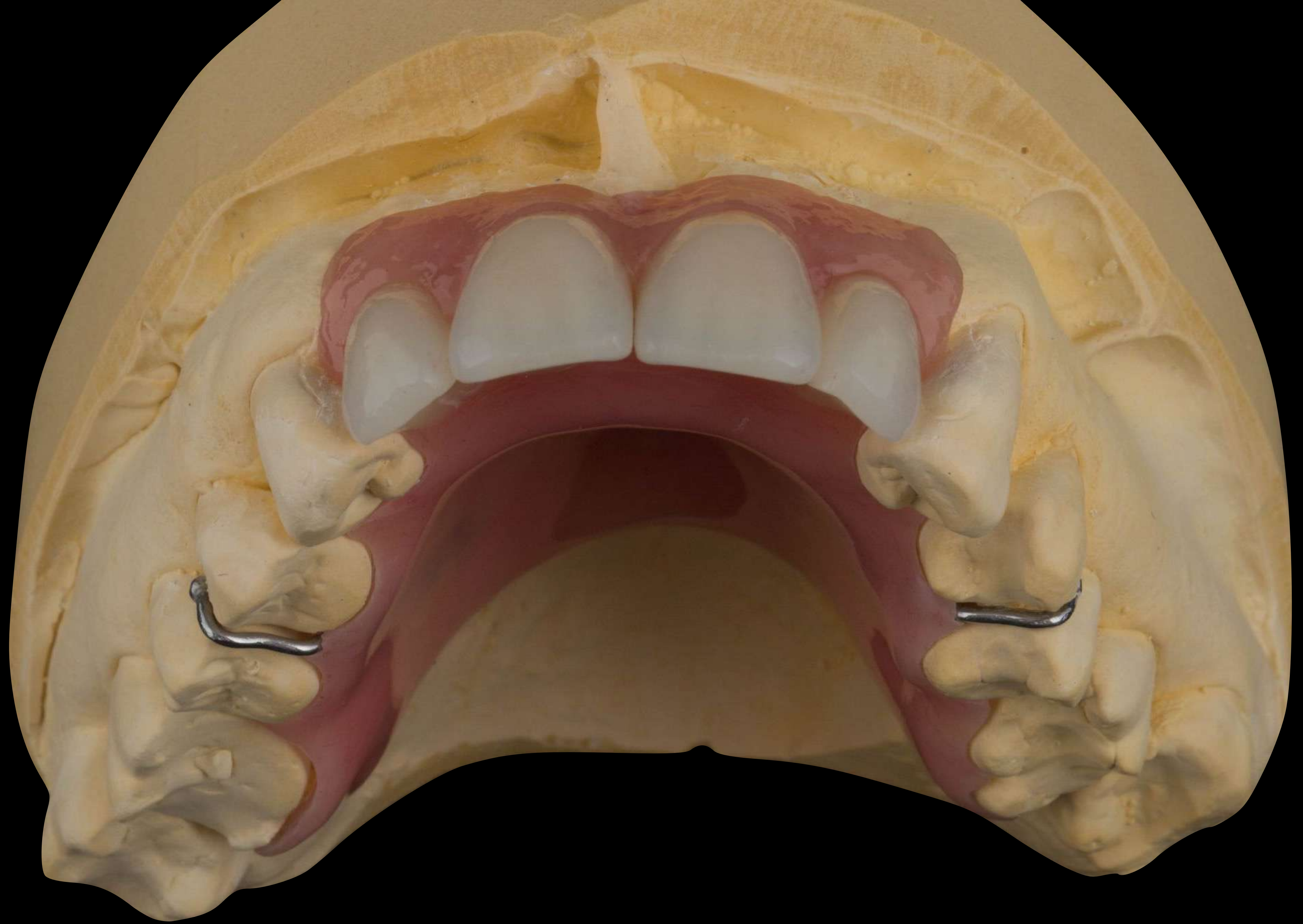


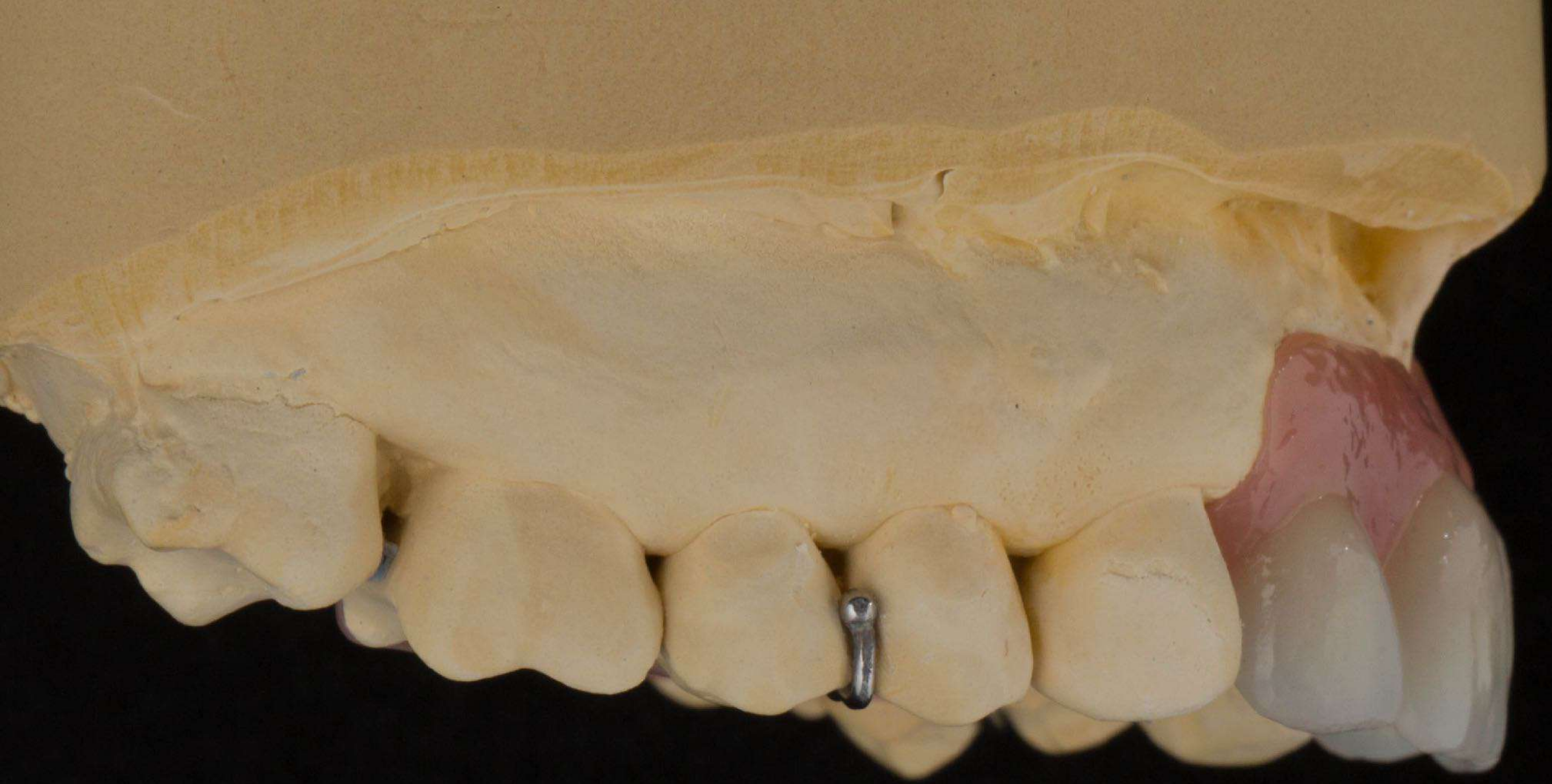


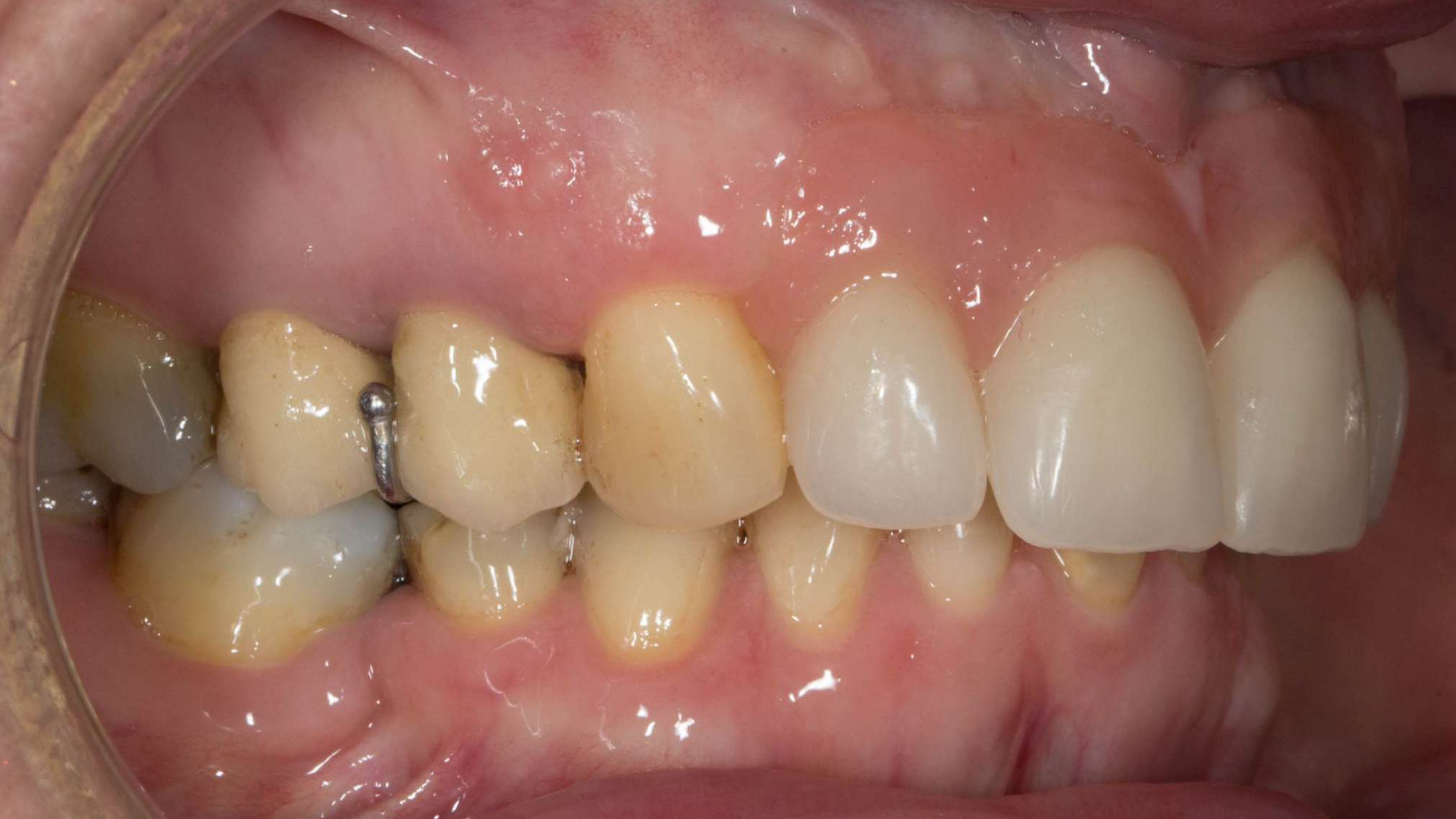




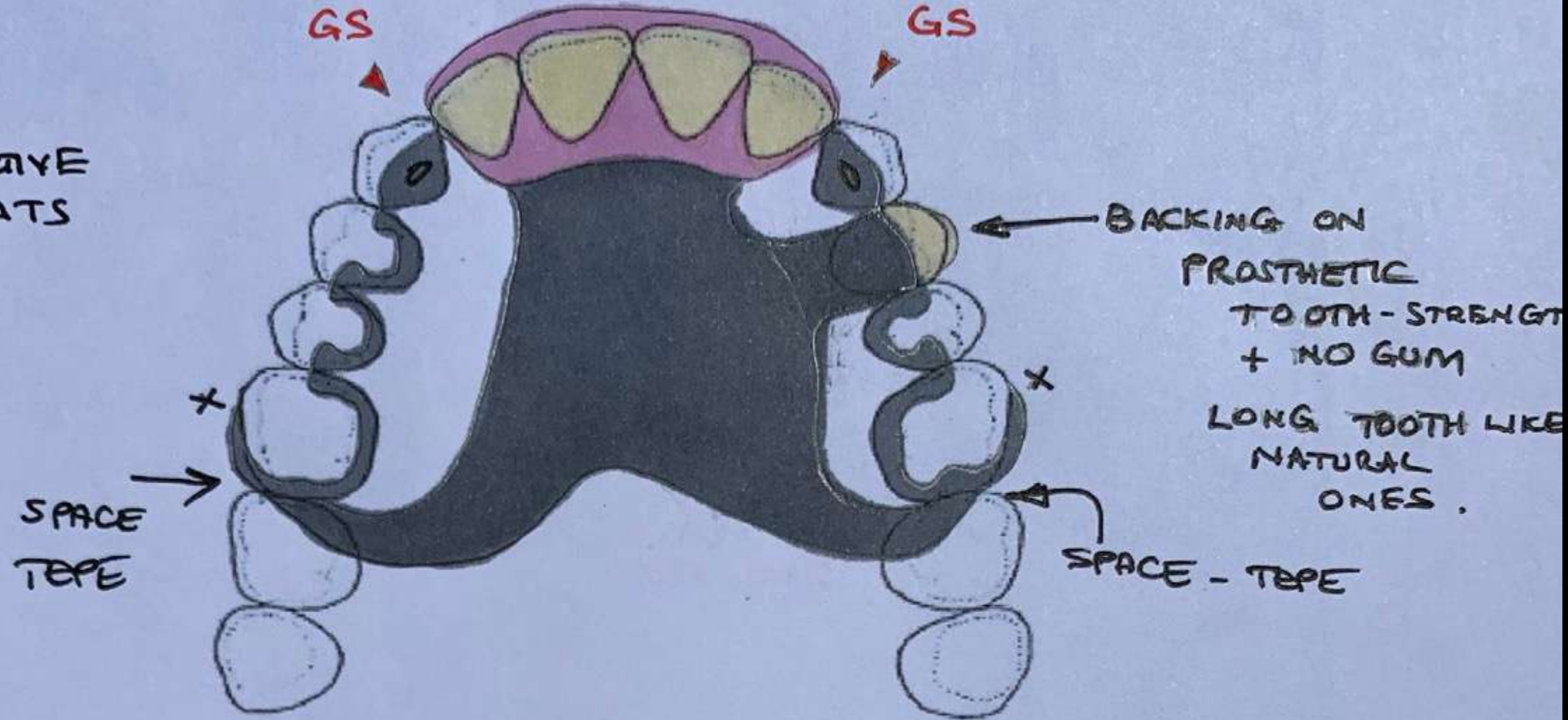






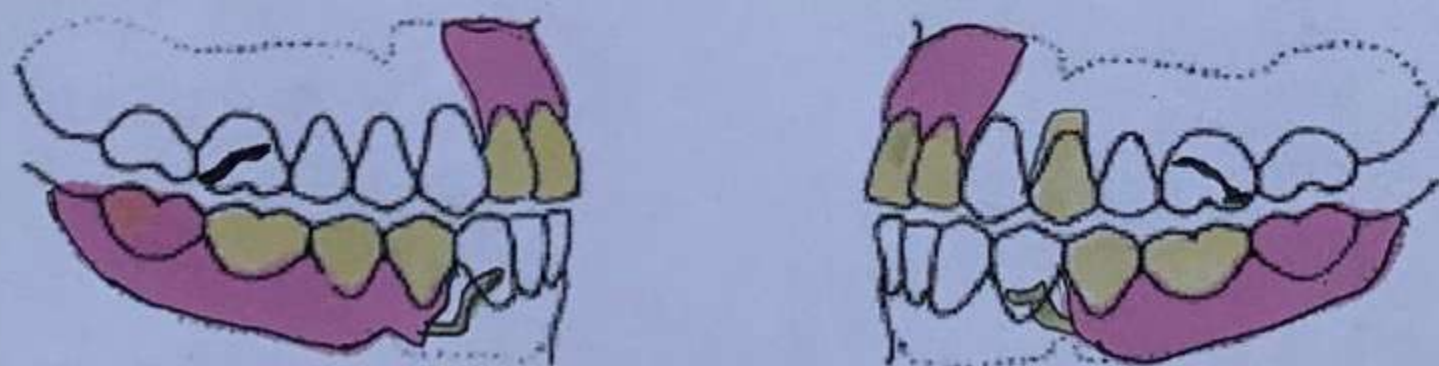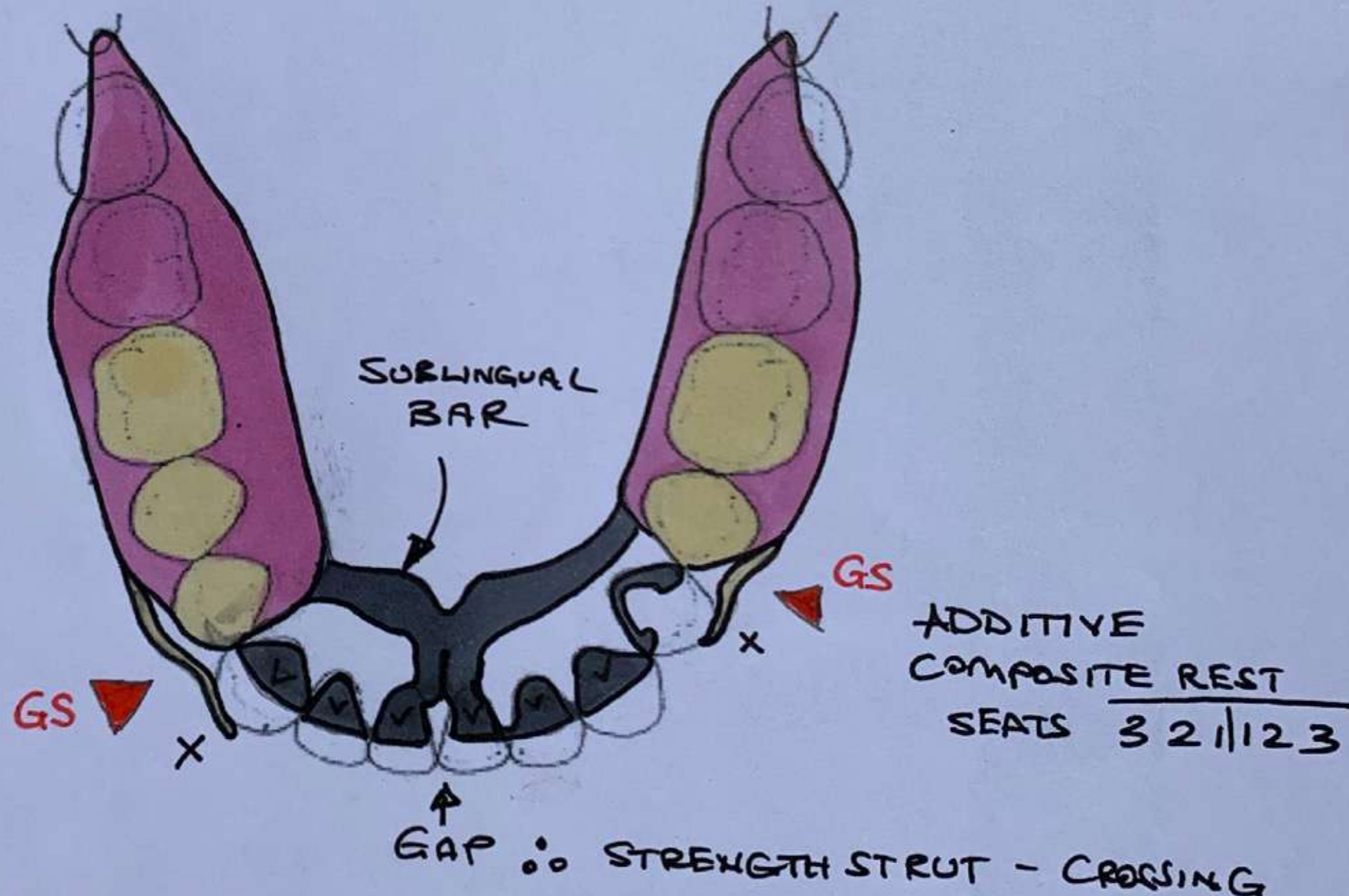
ng the definitive partial denture for

3|3
SUBTRACTIVE
REST SEATS



RESTORATIONS
NEEDED :-

- 3 | m
- 3 | d
- 3 | b
- 2 | - Inc. edge
- 1 | - " "
- 1 | - " "
- 3 - b
- 4 - b.

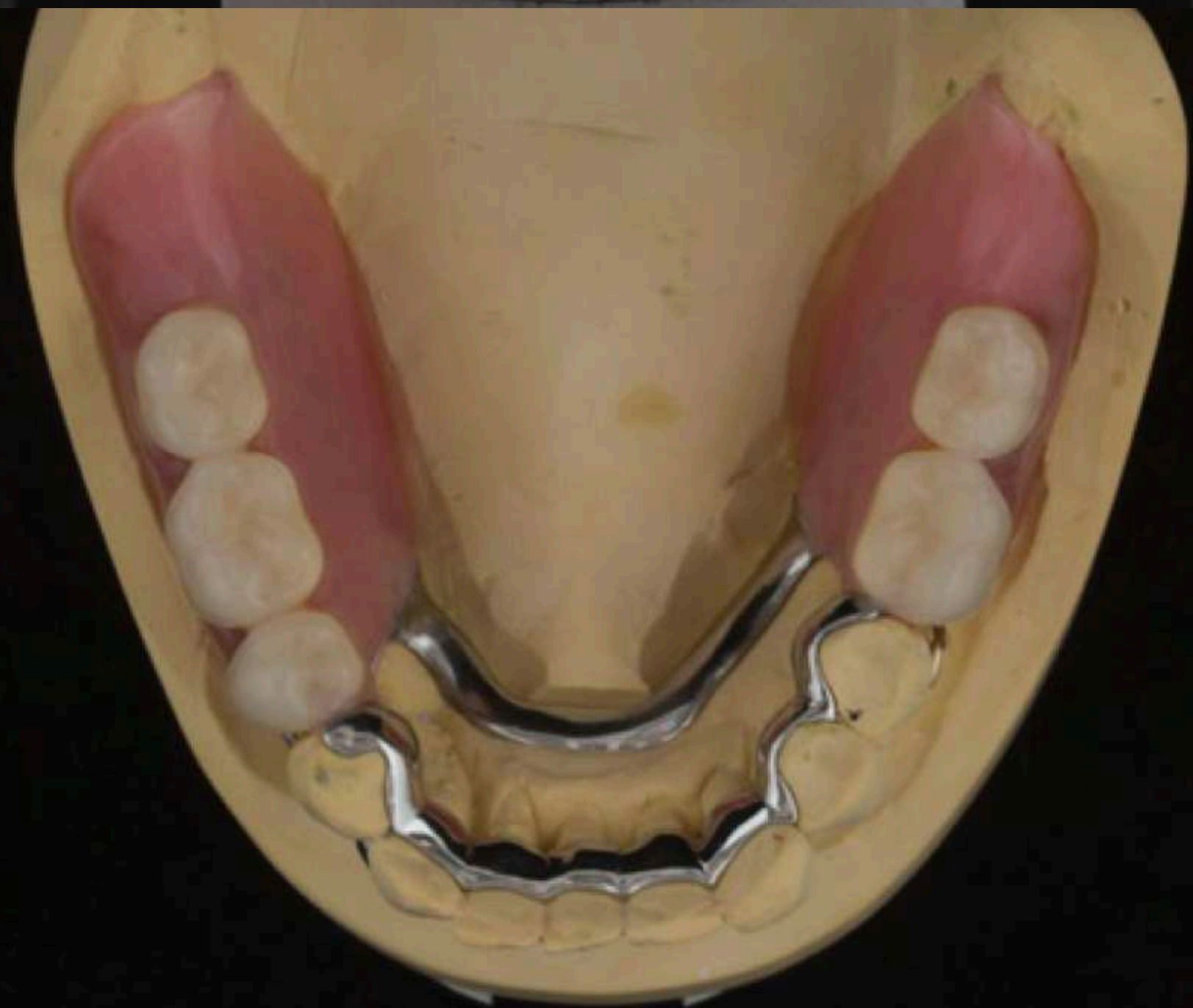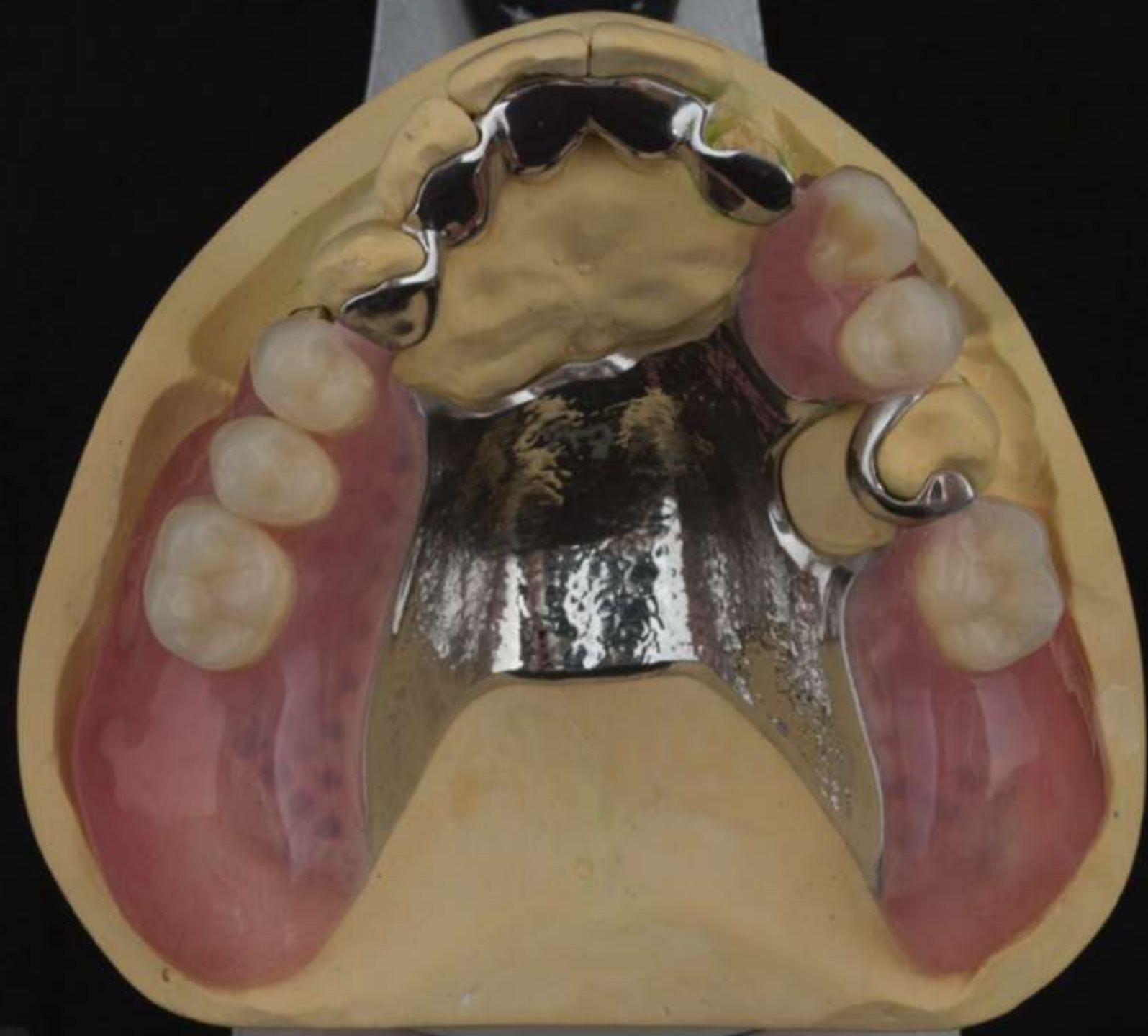


STRENGTH STRUT - CROSSING
GINGIVAL
MARGIN.
BREAKING
3MM
RULE.


Top tip
Detailed design

Xavier's

ADDITIVE
COMPOSITE REST
SEATS 3 2 | | 2 3

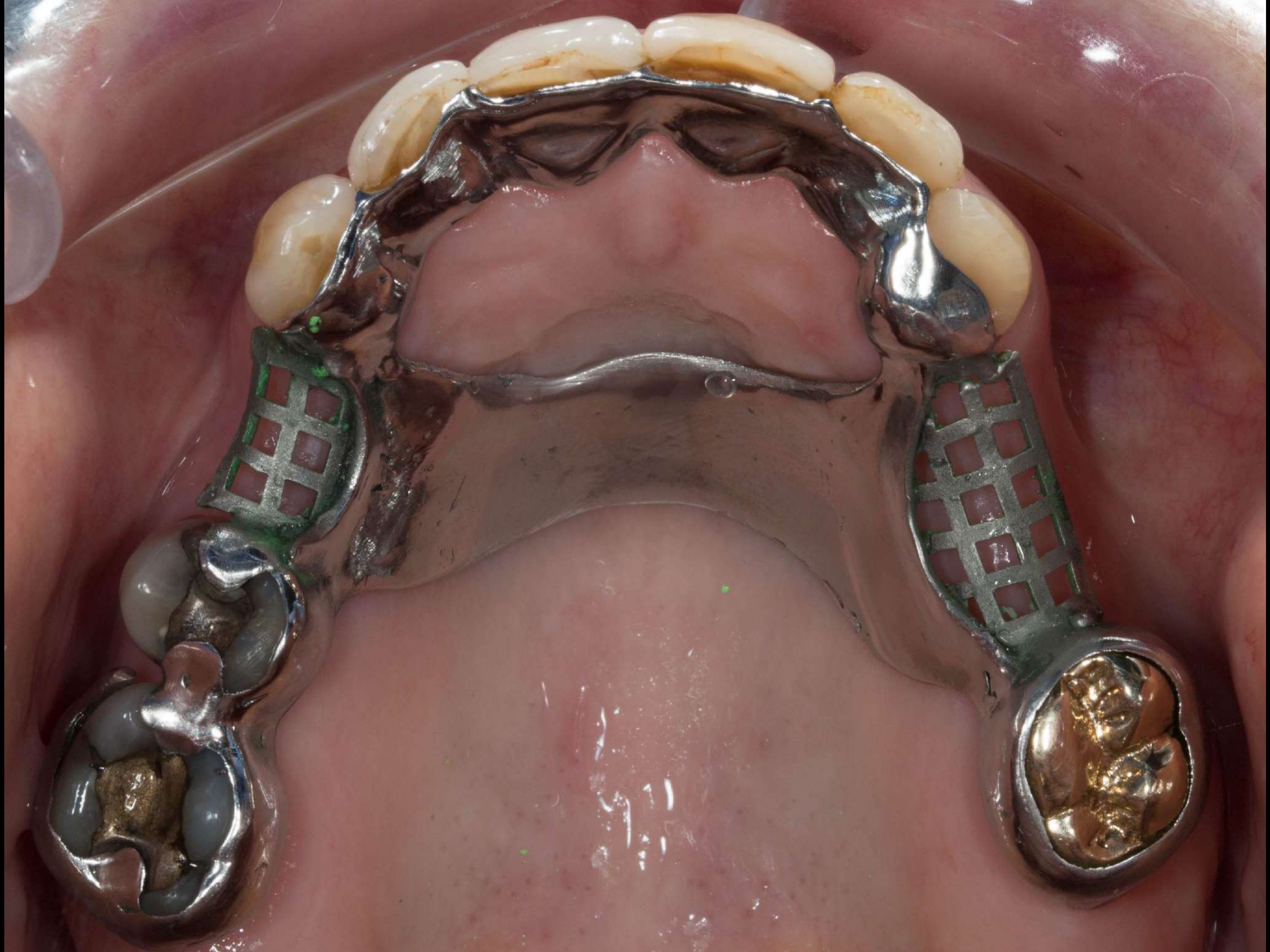

Finished P/P

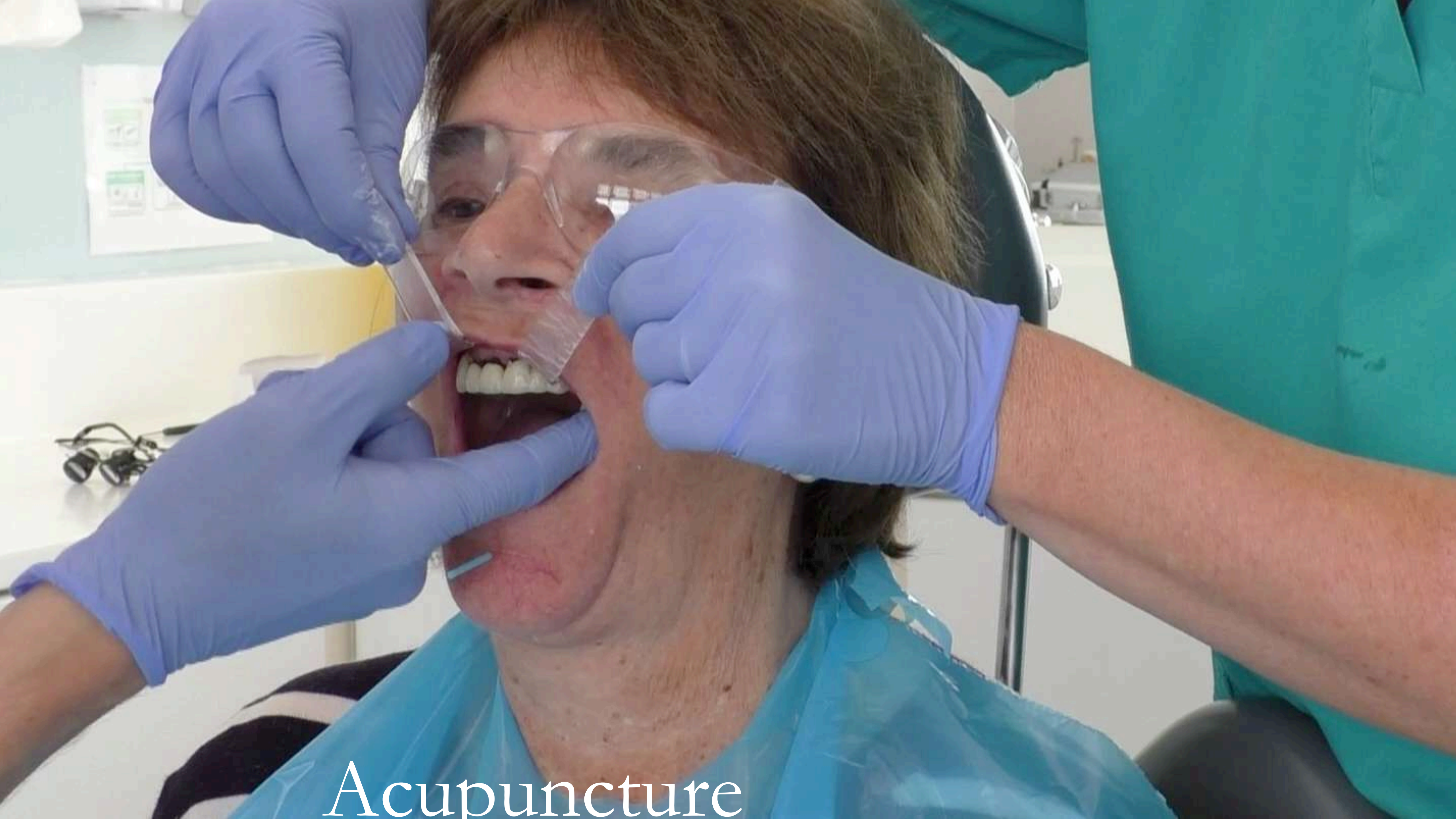

Adjust here

Almost never adjust here



Gag reflex



Acupuncture

Dentate
photographs

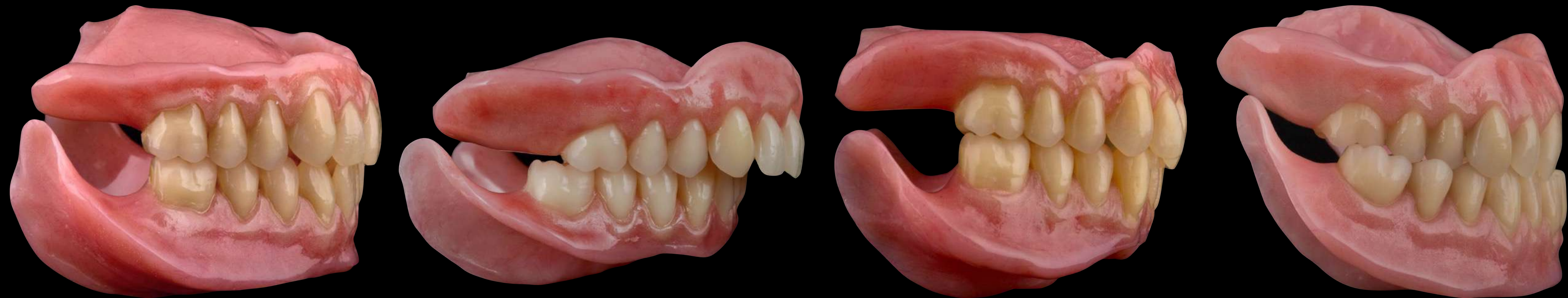

Muriel

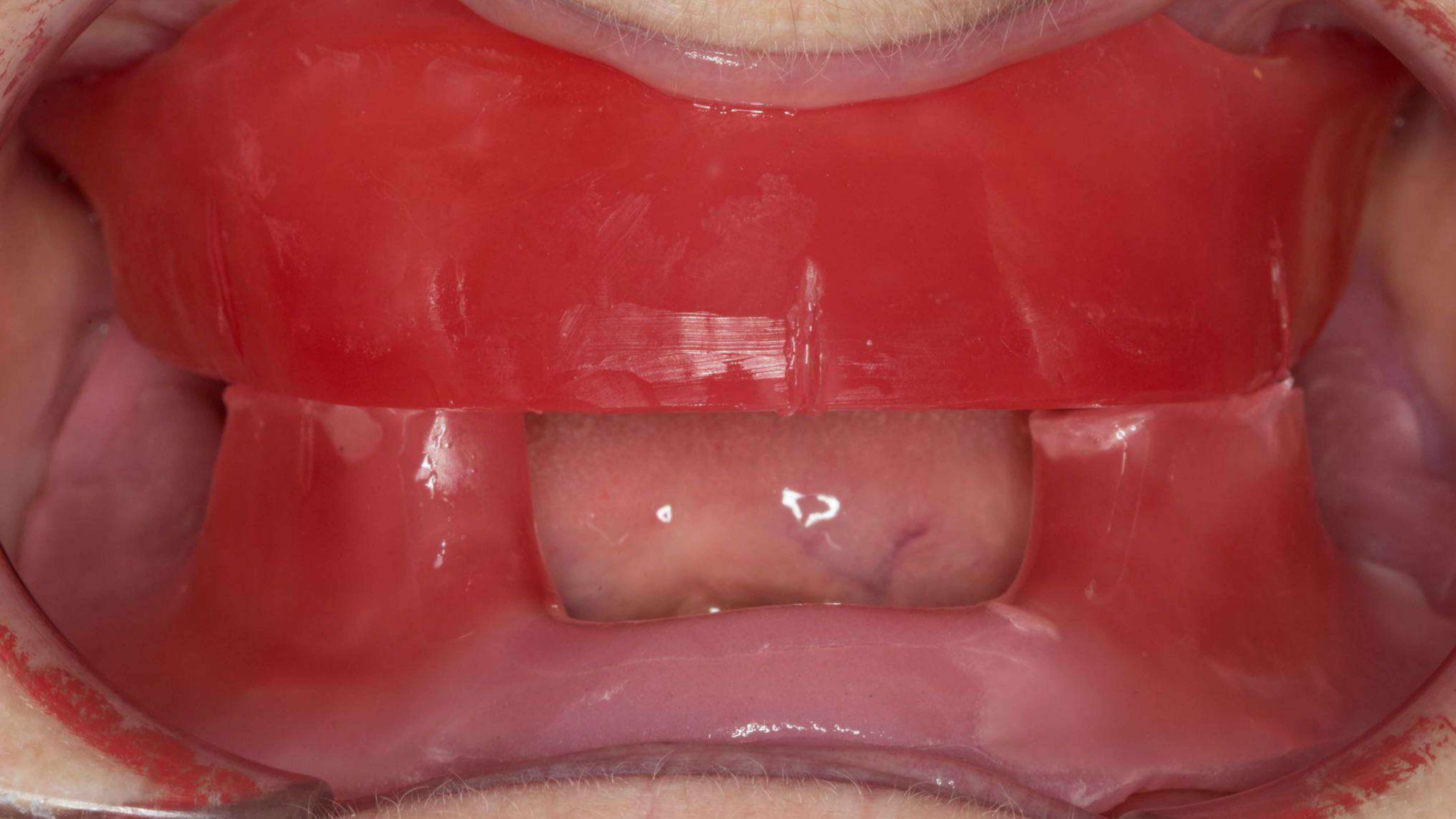


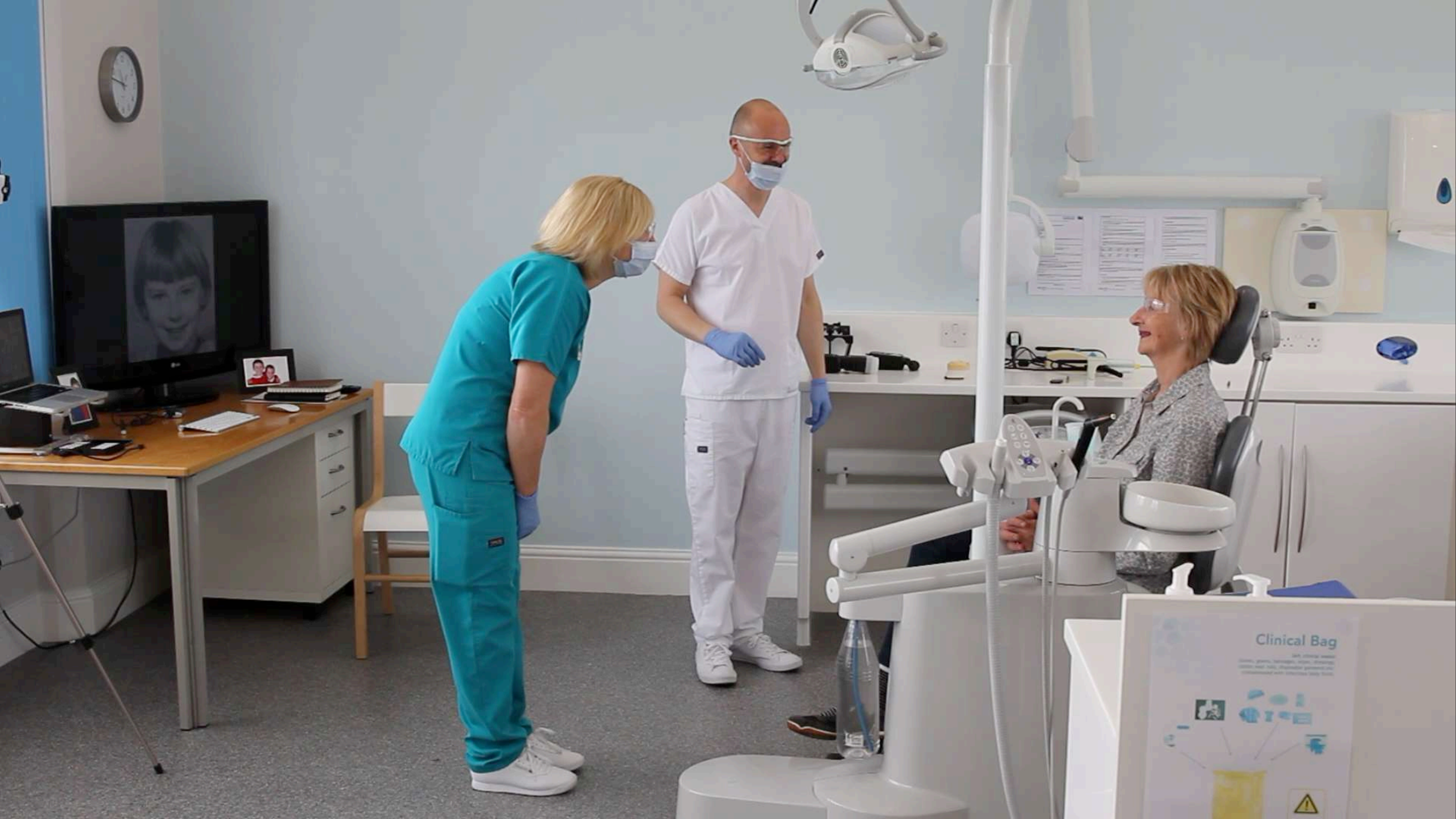
Increased stability

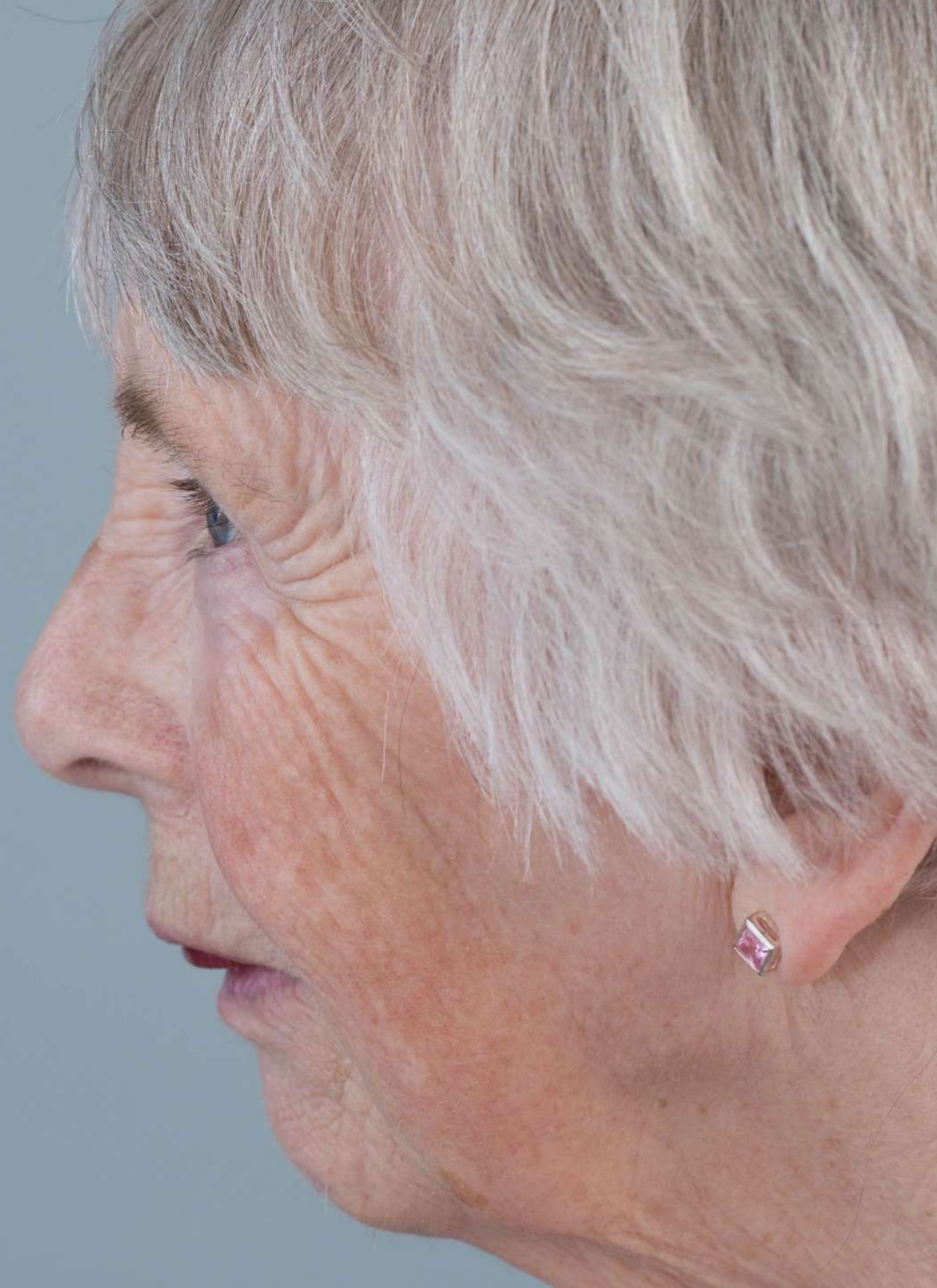

Replace teeth/gums in same place as natural predecessors



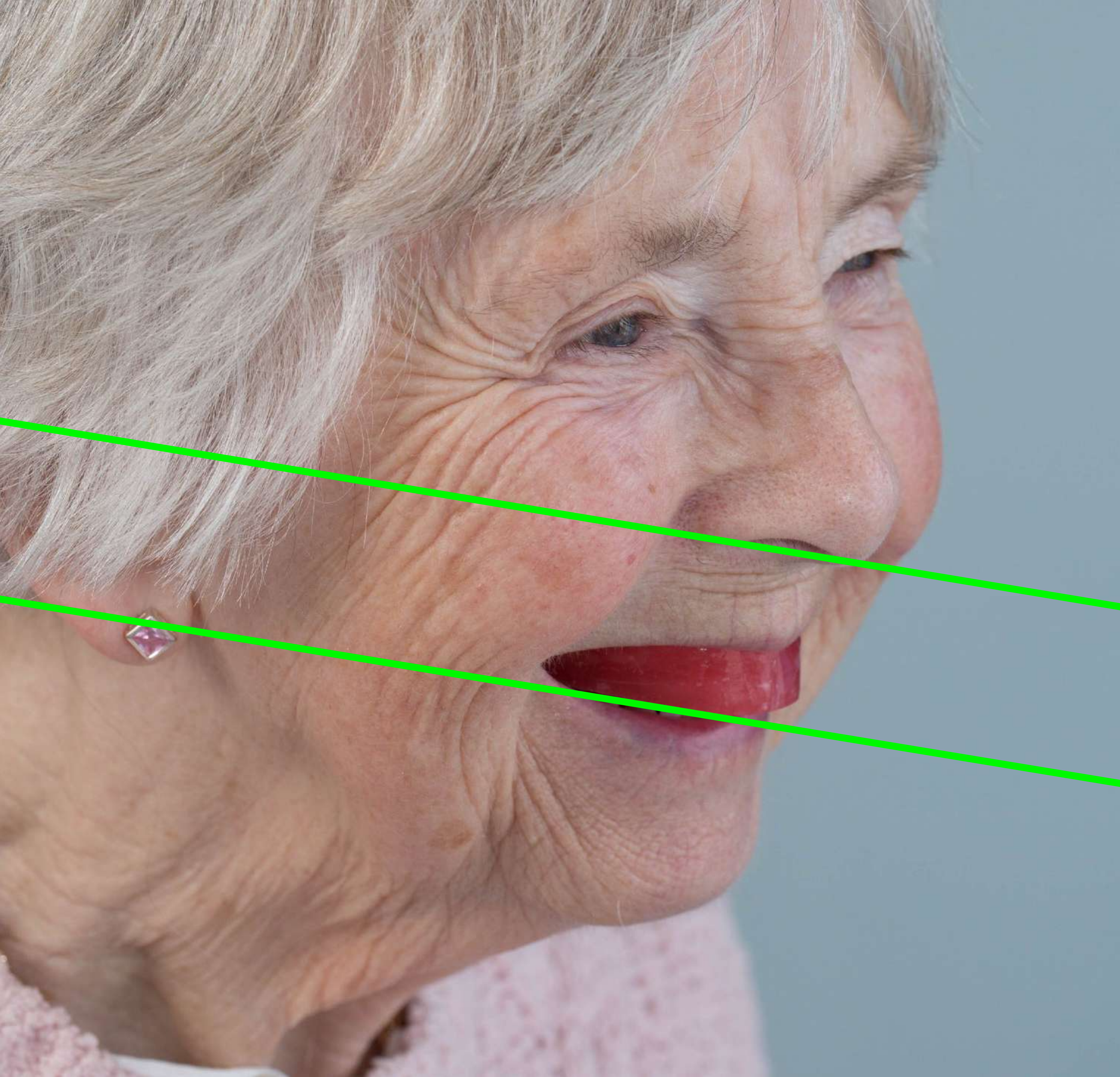


1. Lip Support



2. Incisal plane



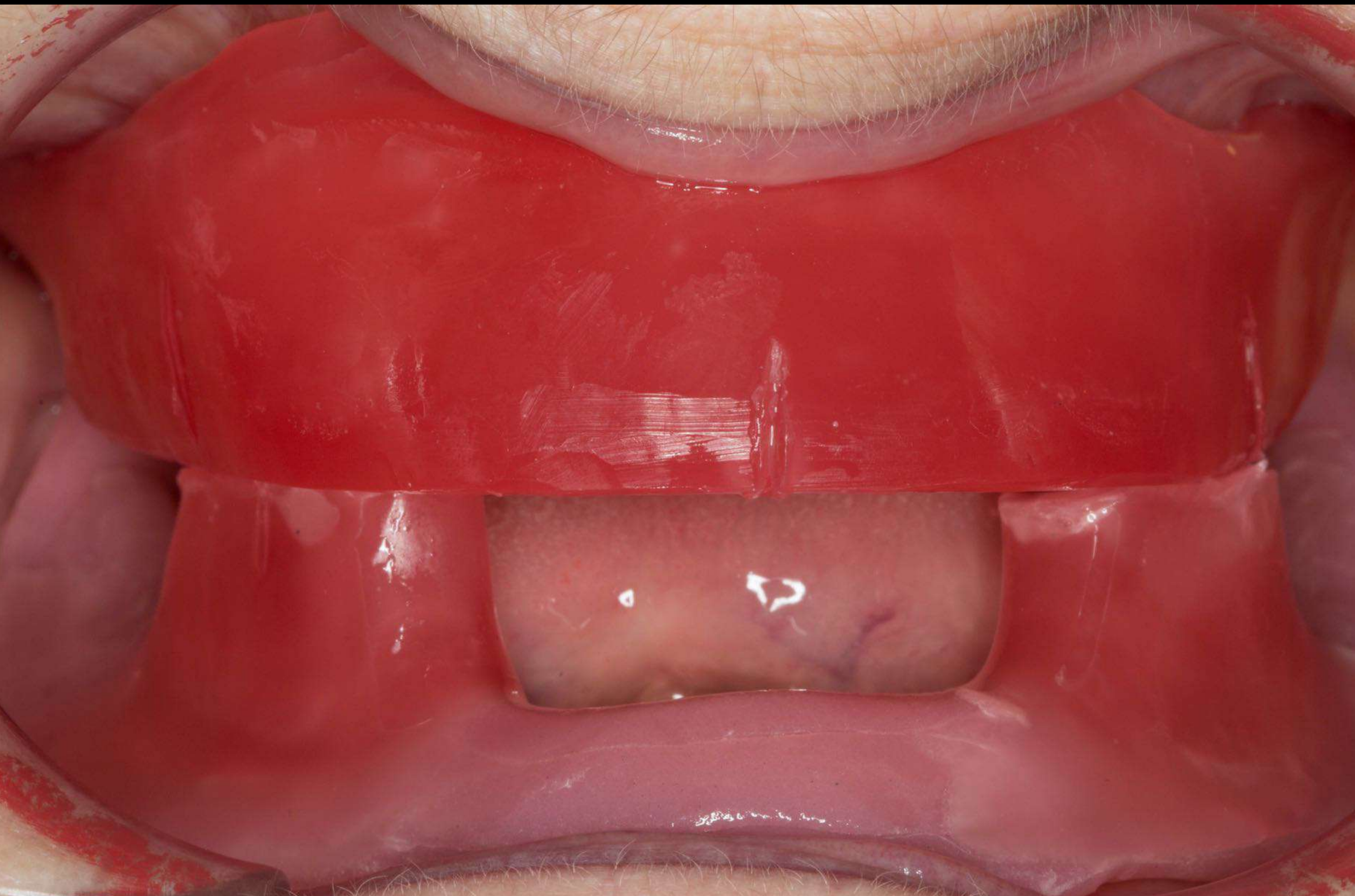


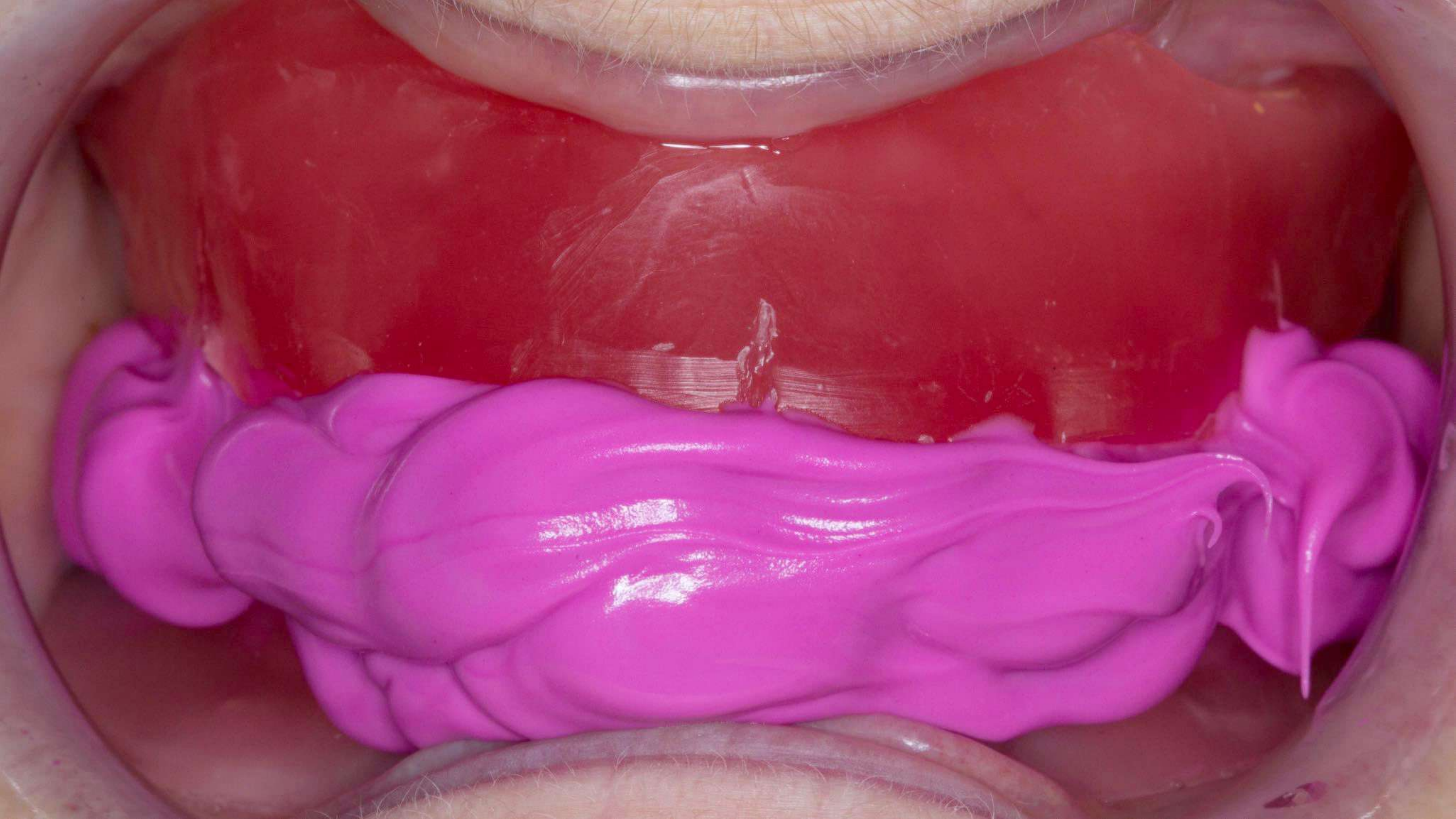
3. Occlusal plane



4 & 5 Buccal corridors and centre line

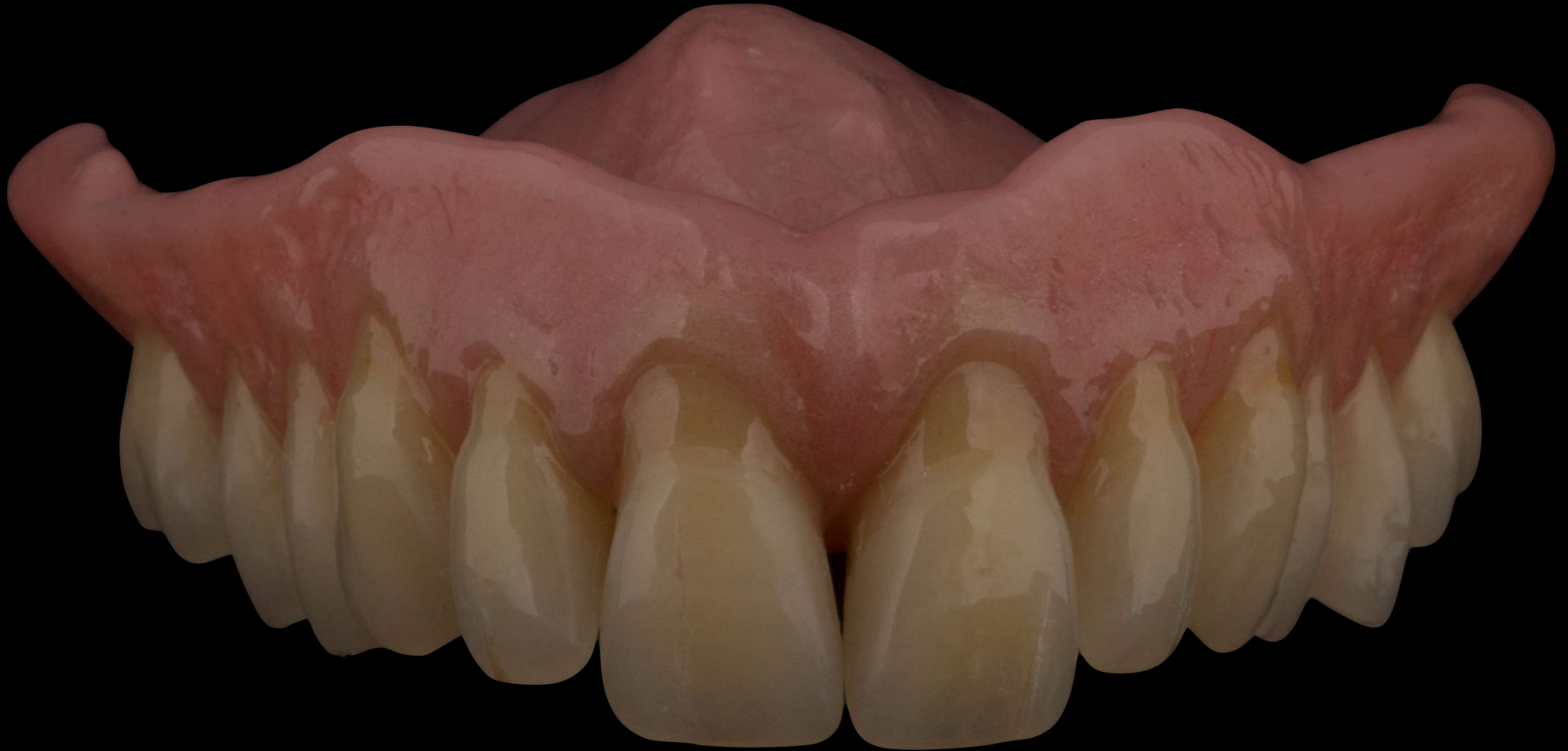6. Occlusal Vertical Dimension

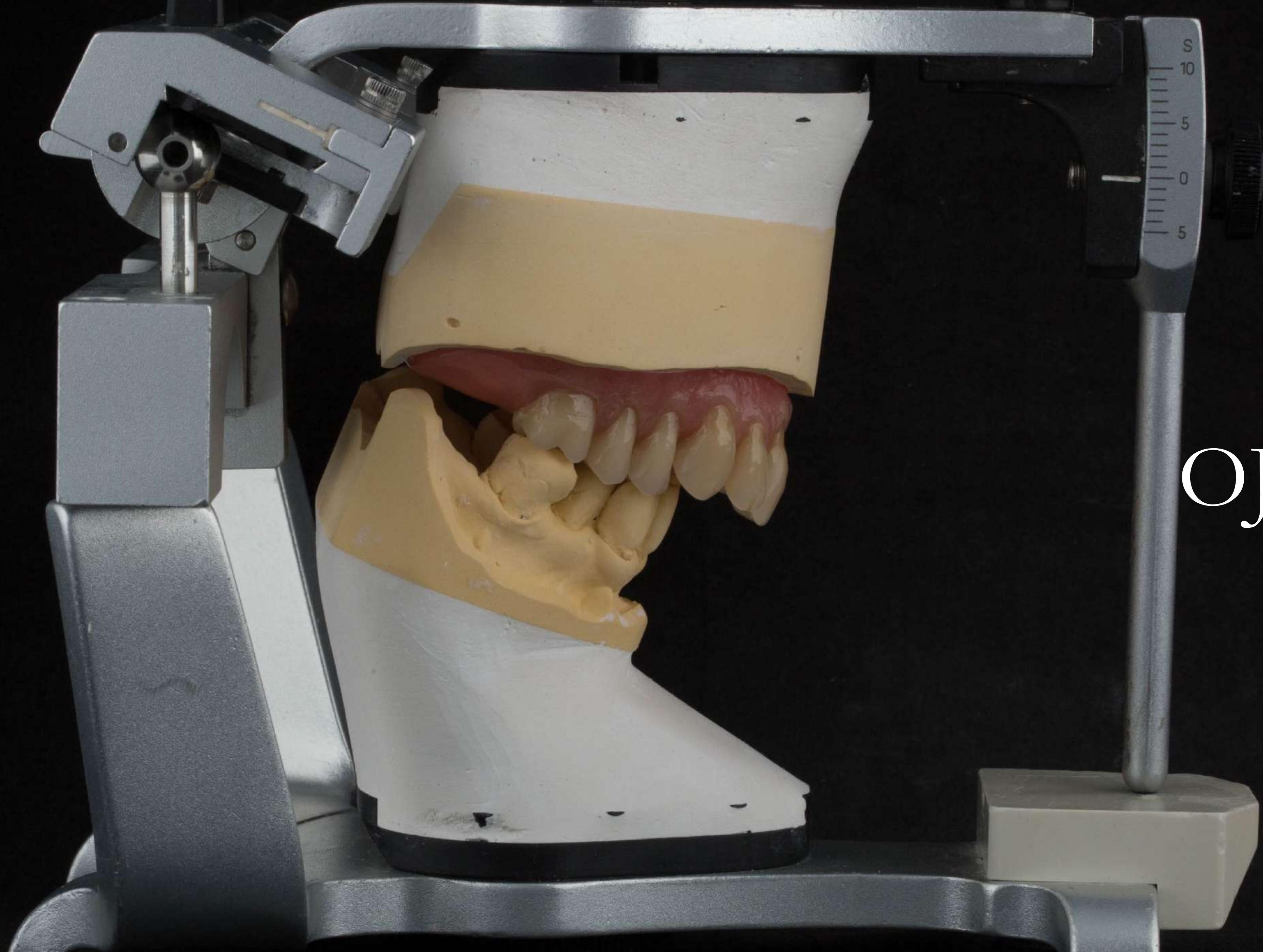






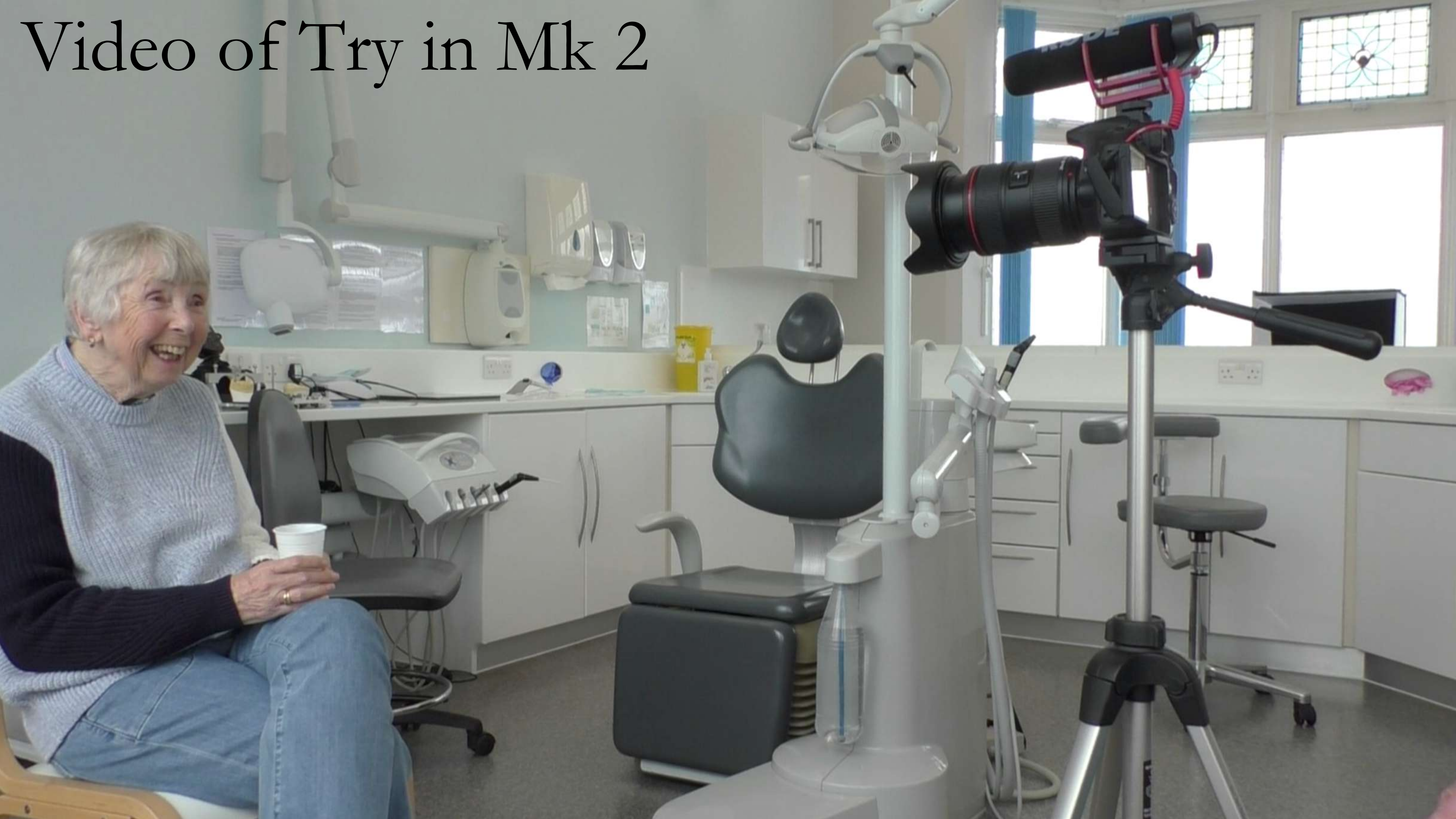




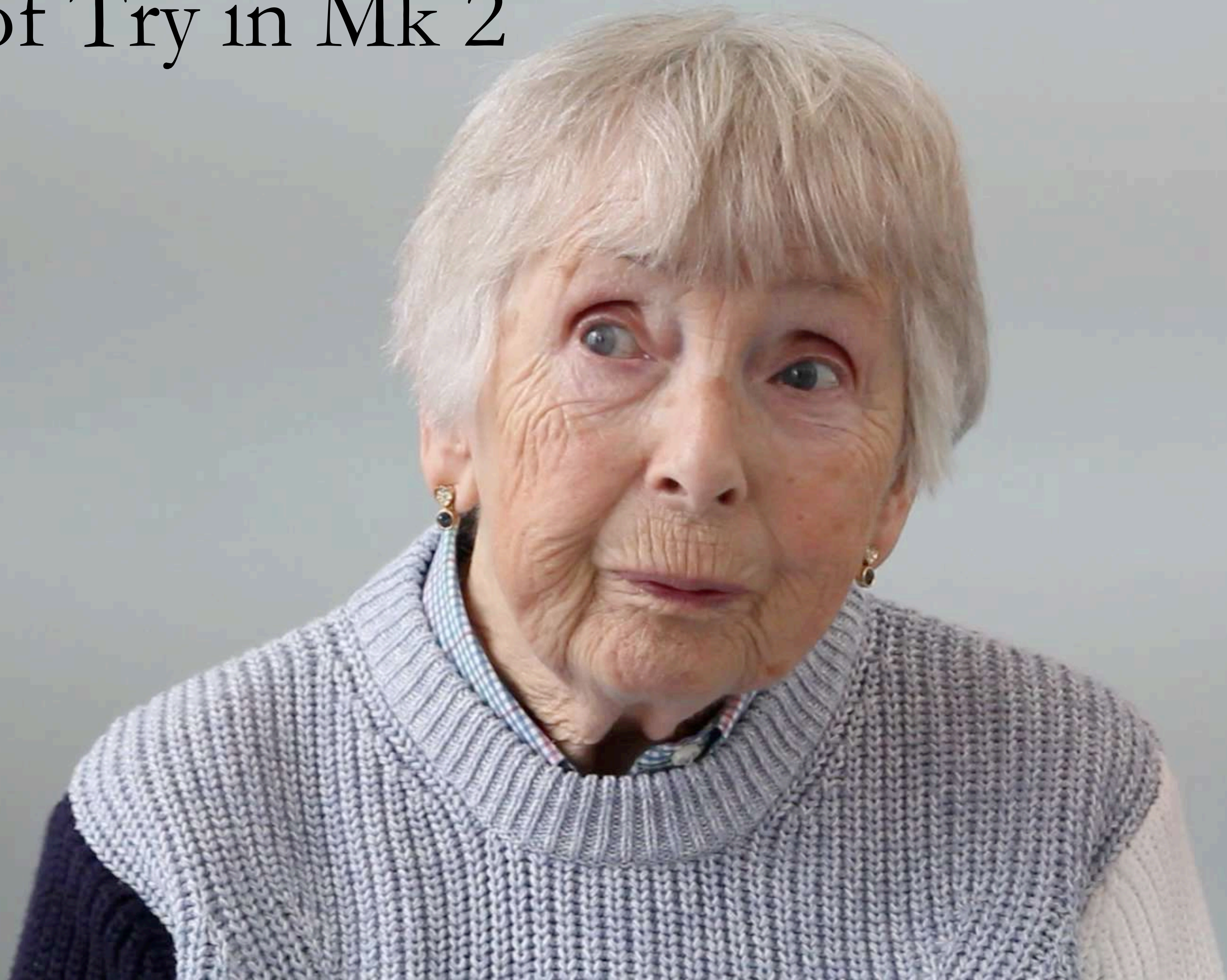
OJ - 12.5 mm

Video of Try in Mk 2

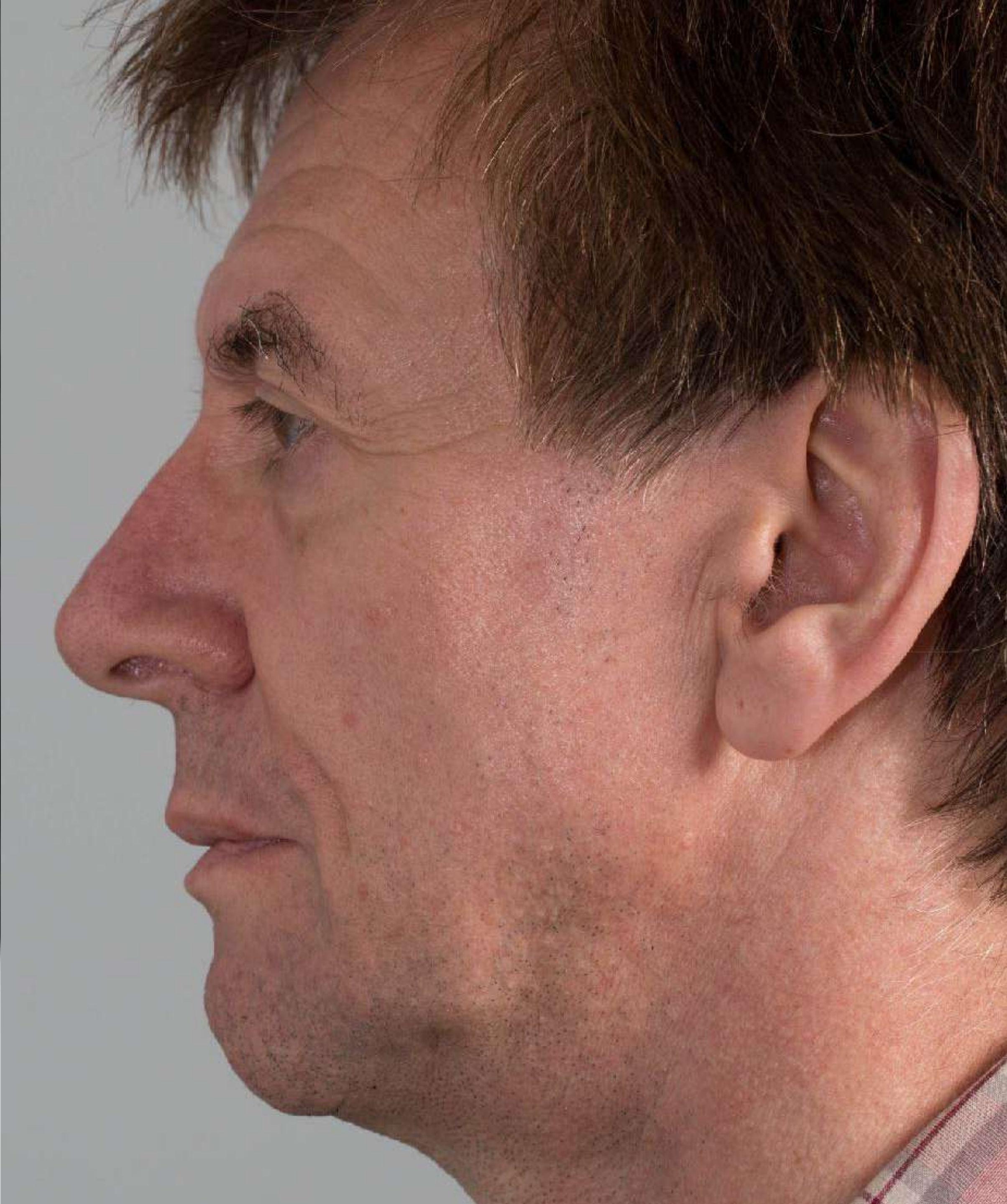
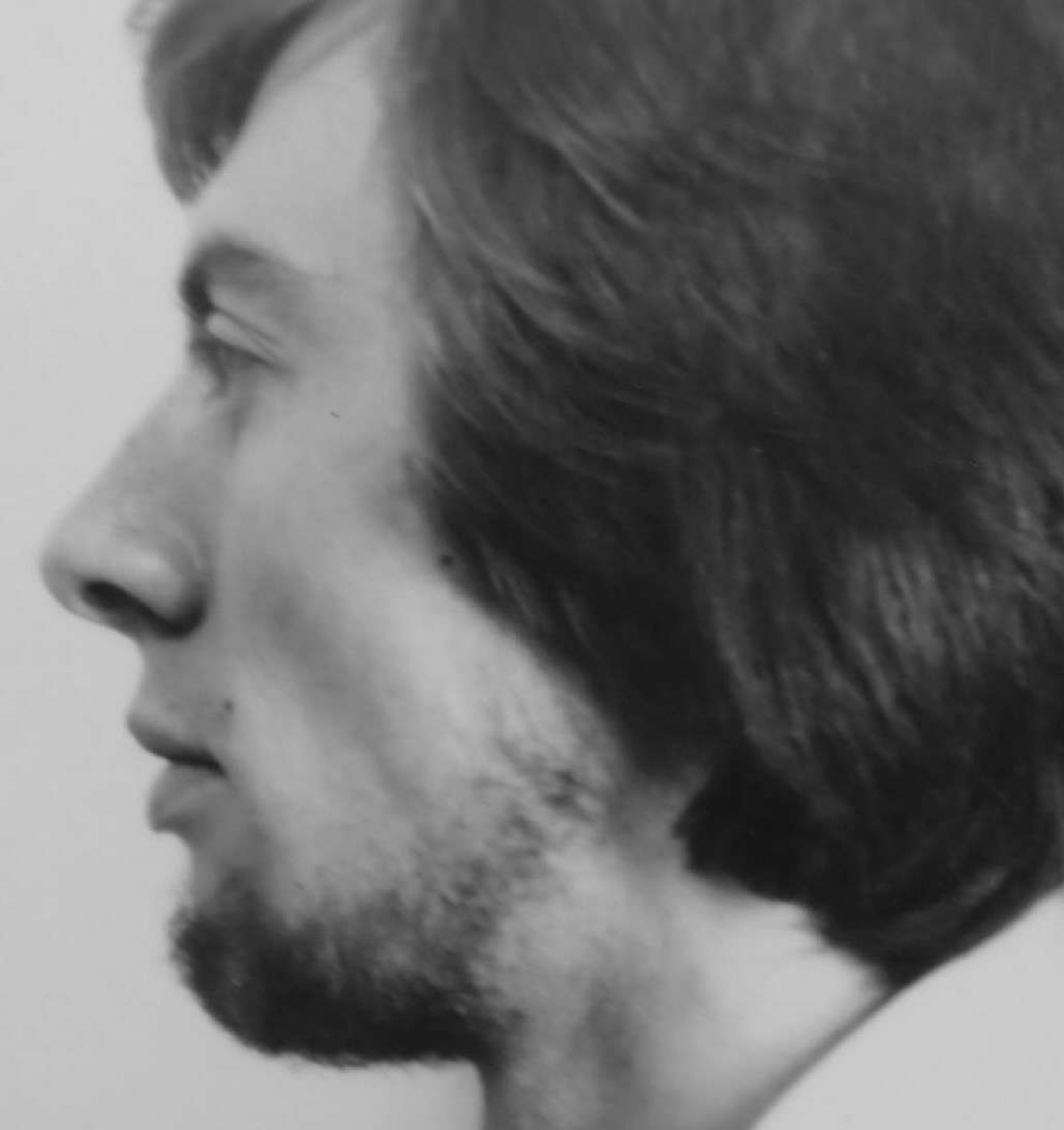

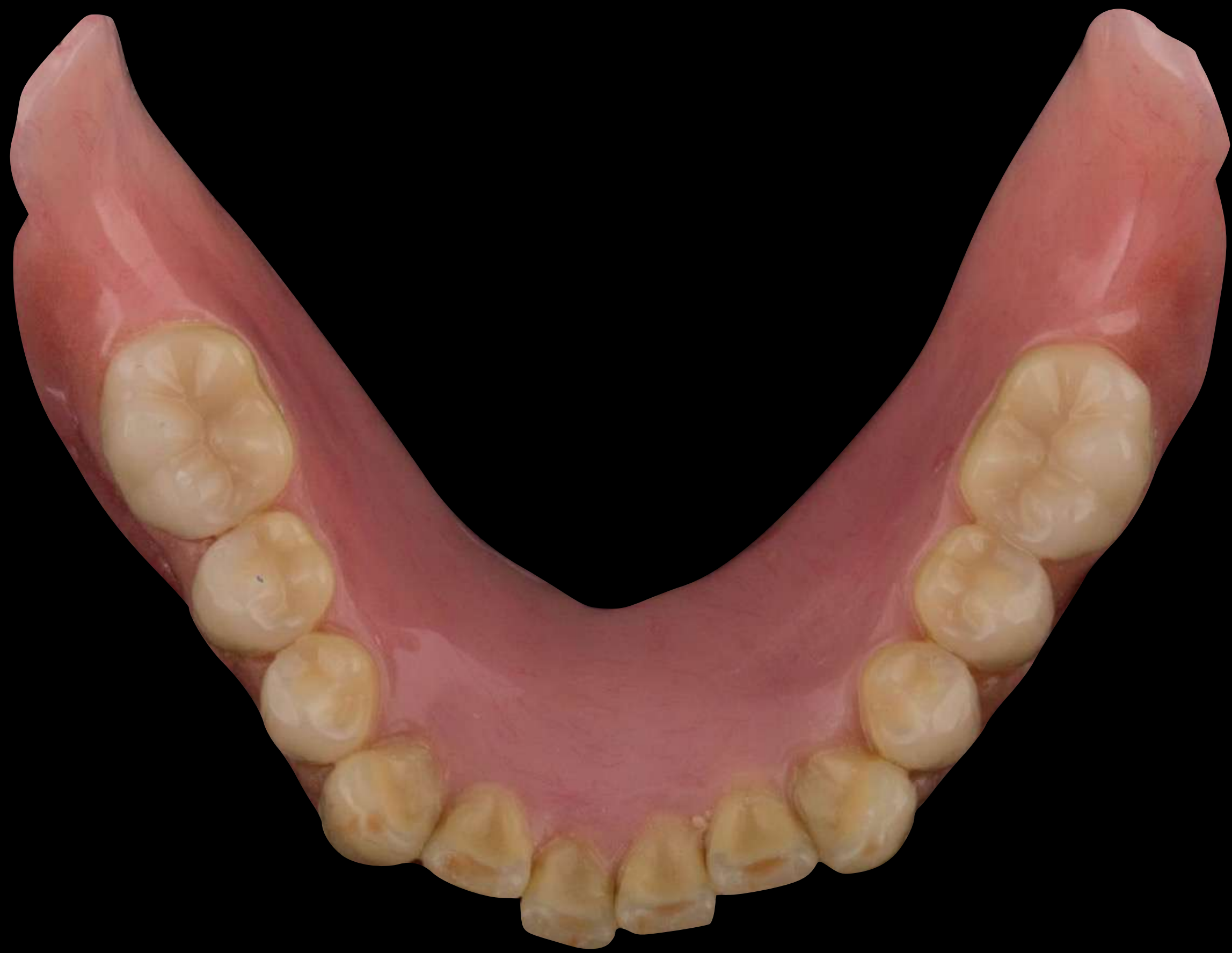Video of Try in Mk 2





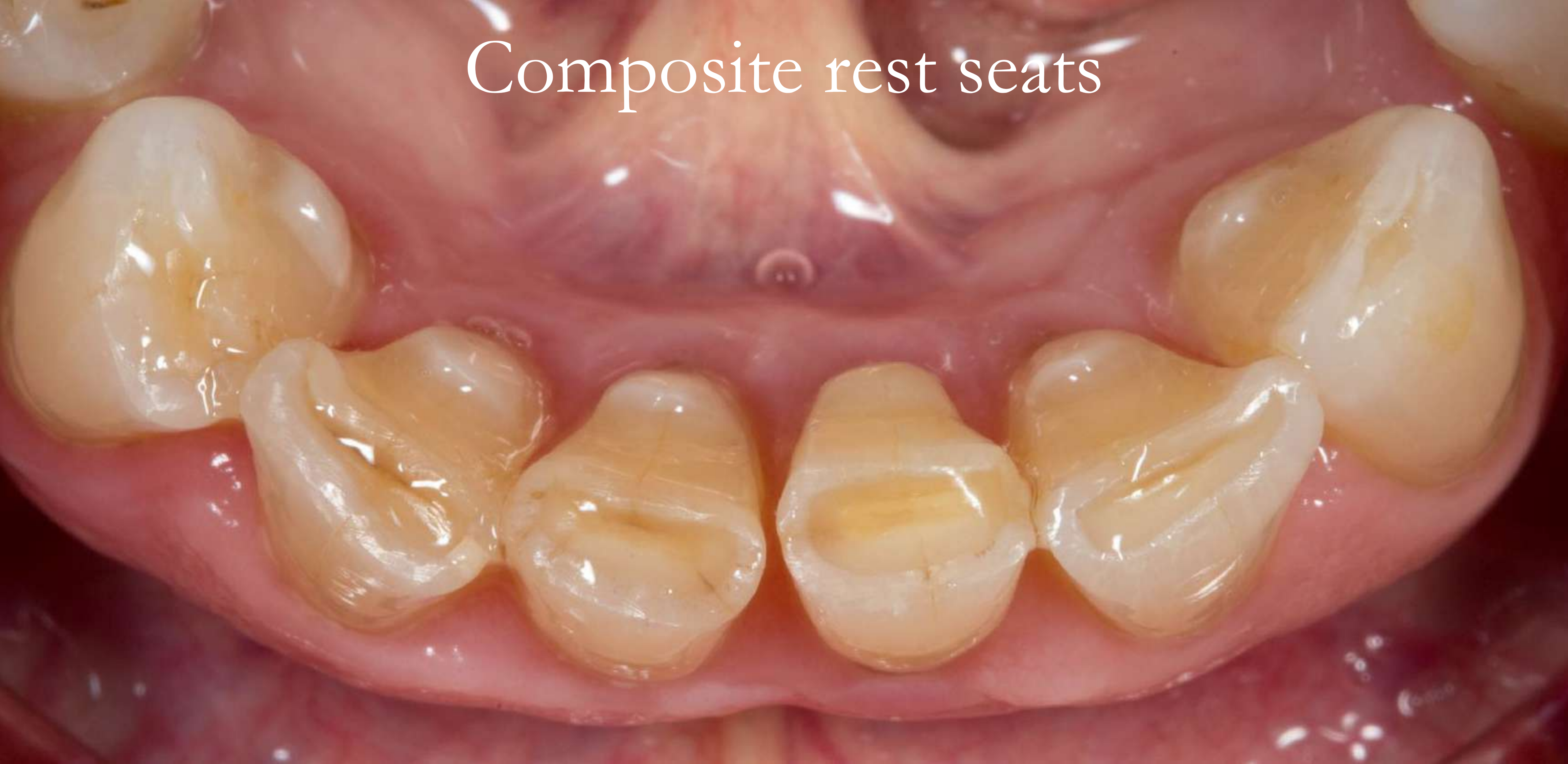Upper lip grows



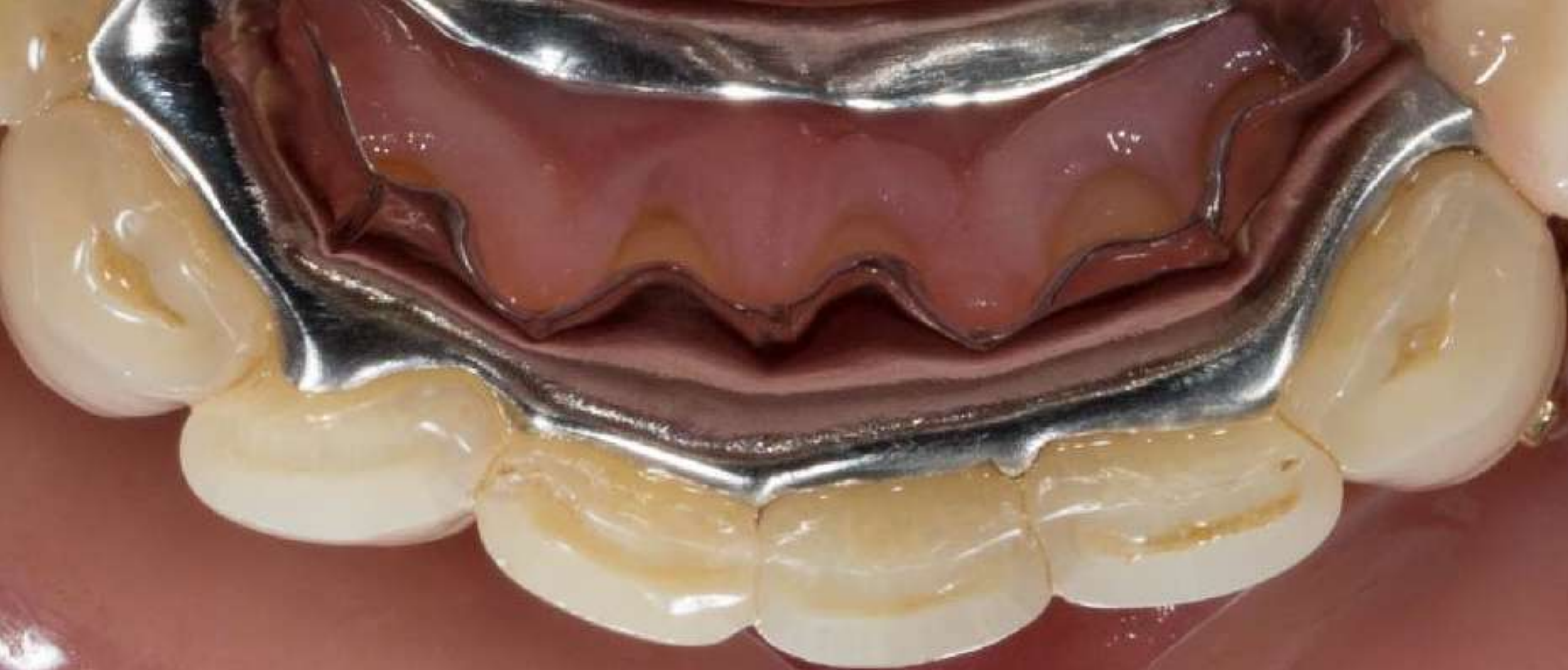

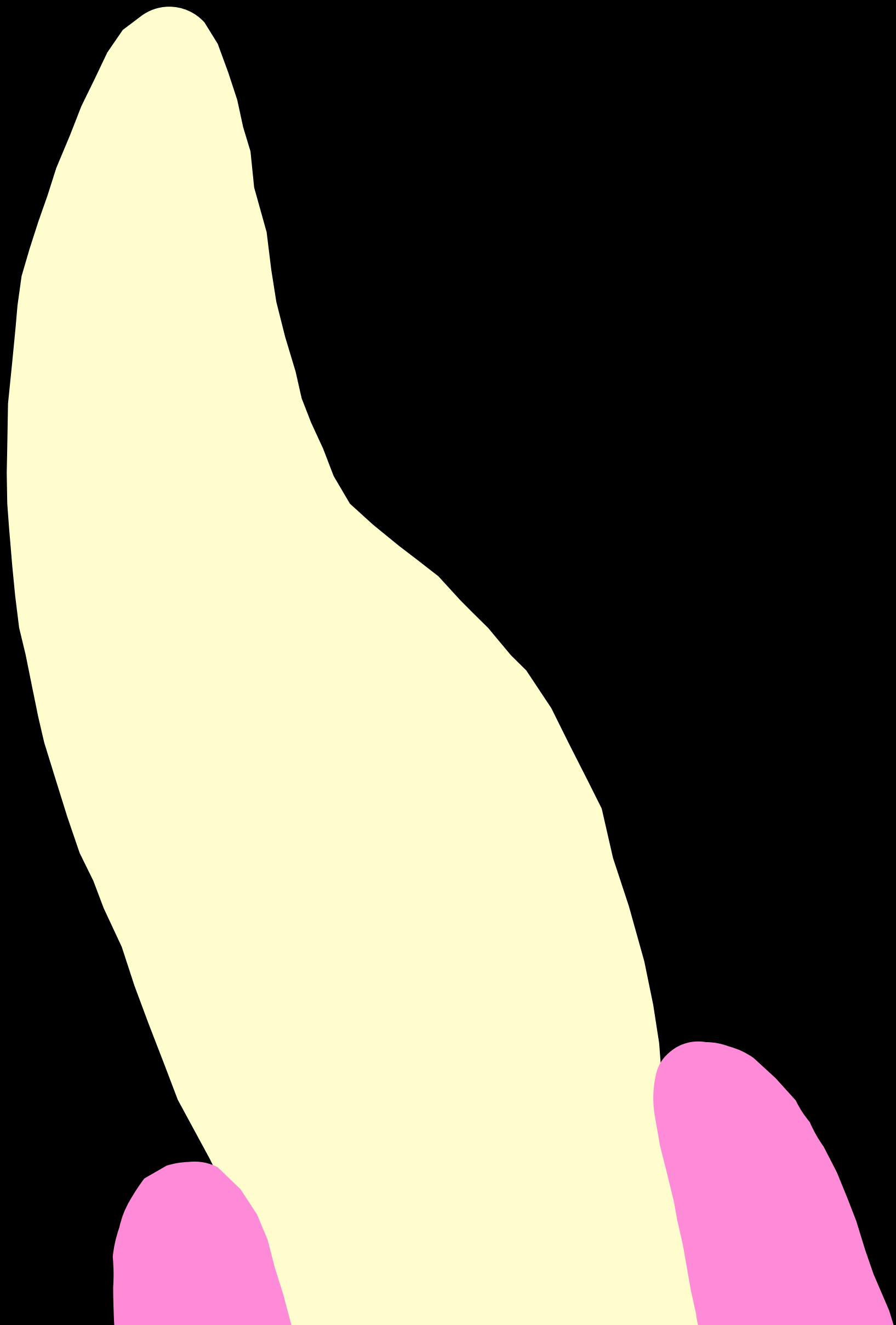
Composite rests


Composite rest seats

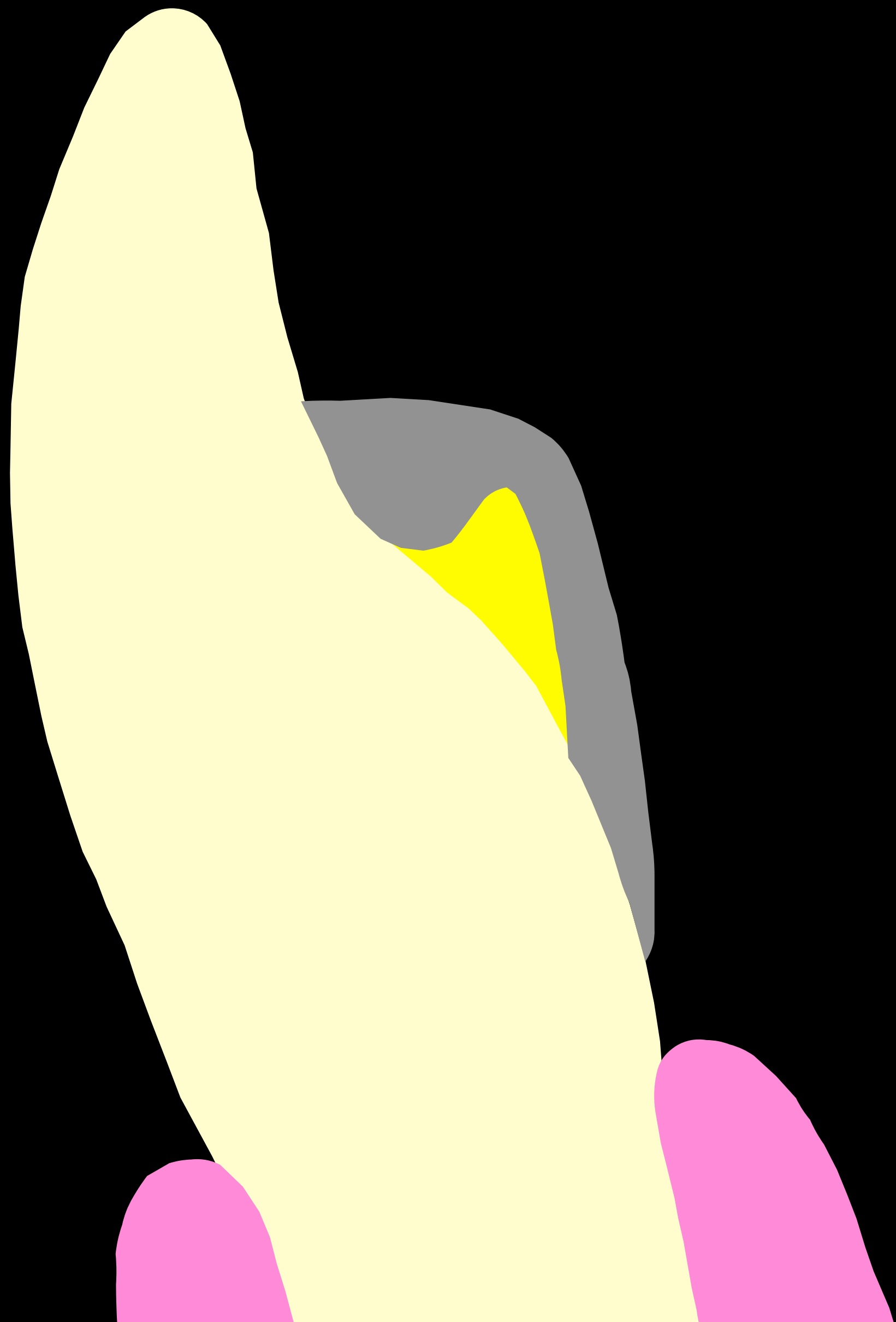


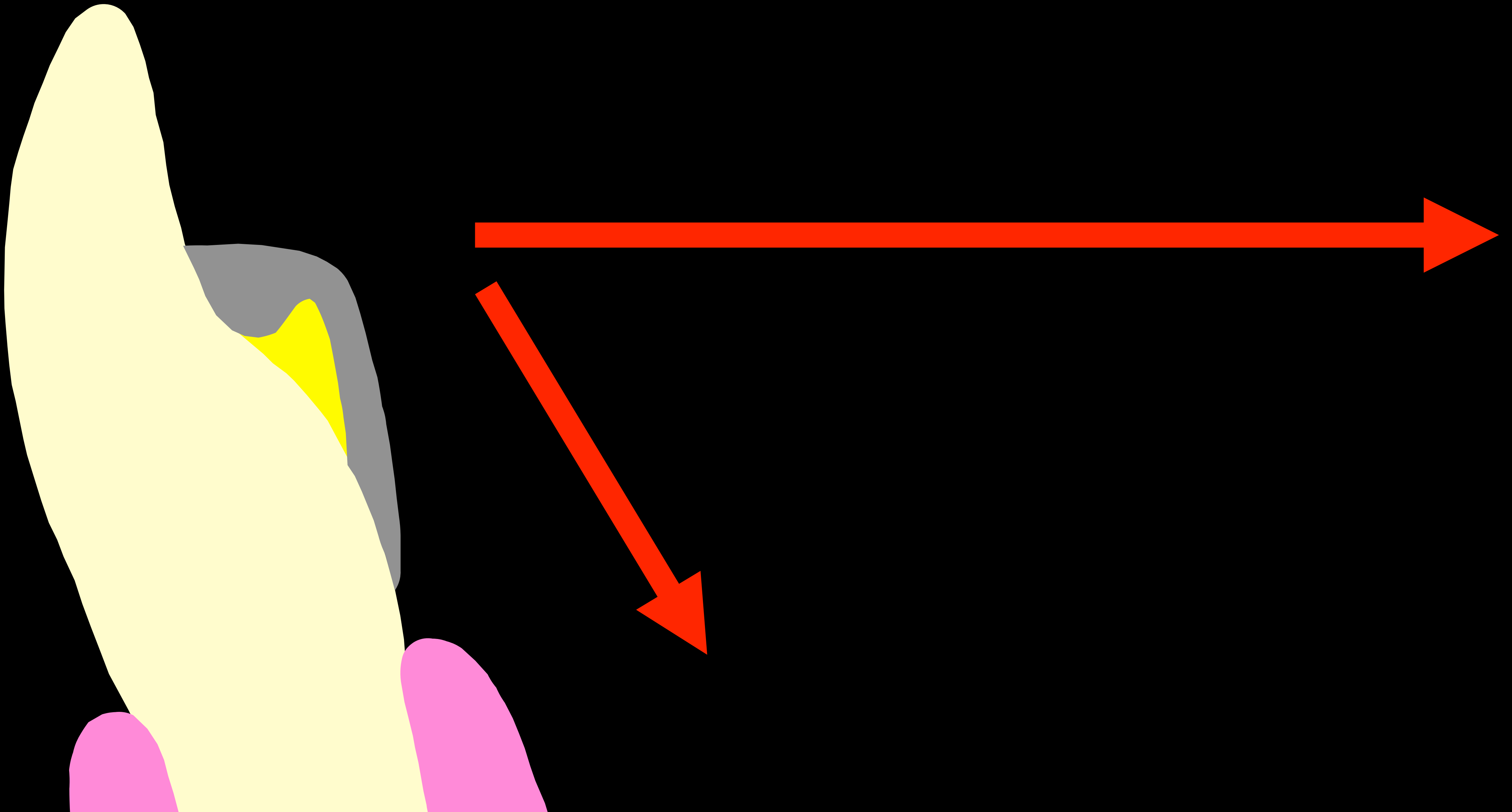
James S Brudvik

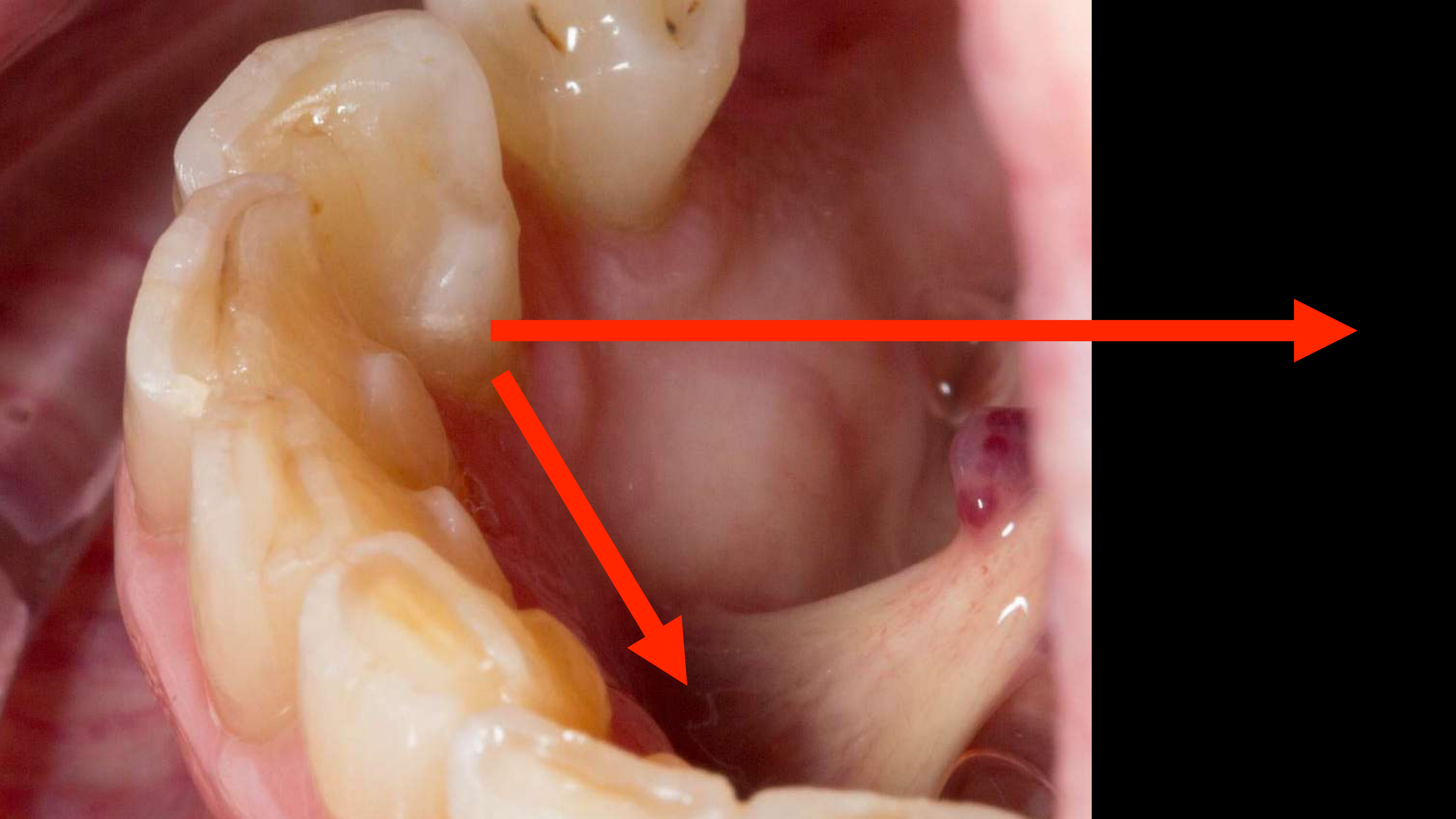


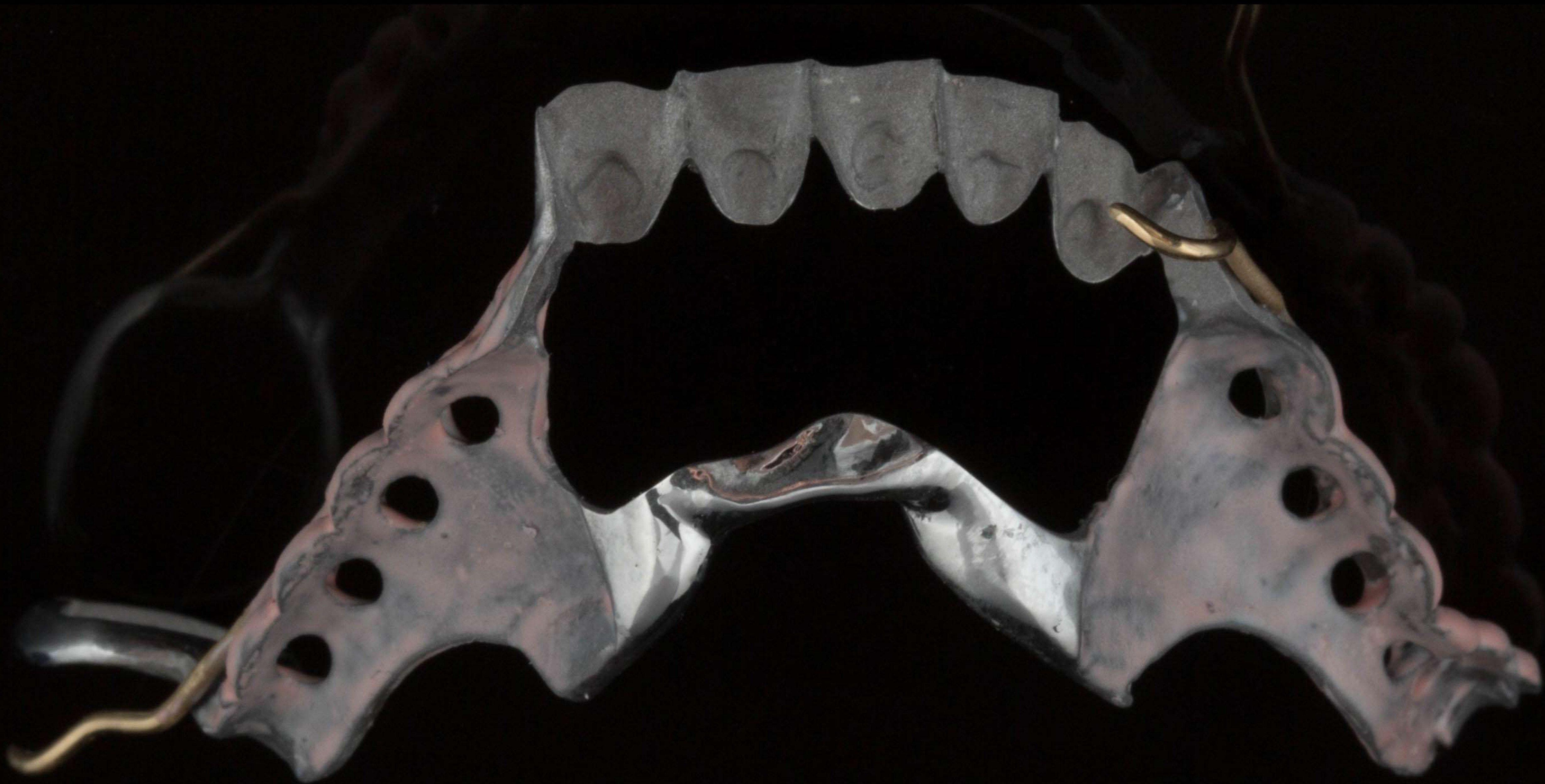


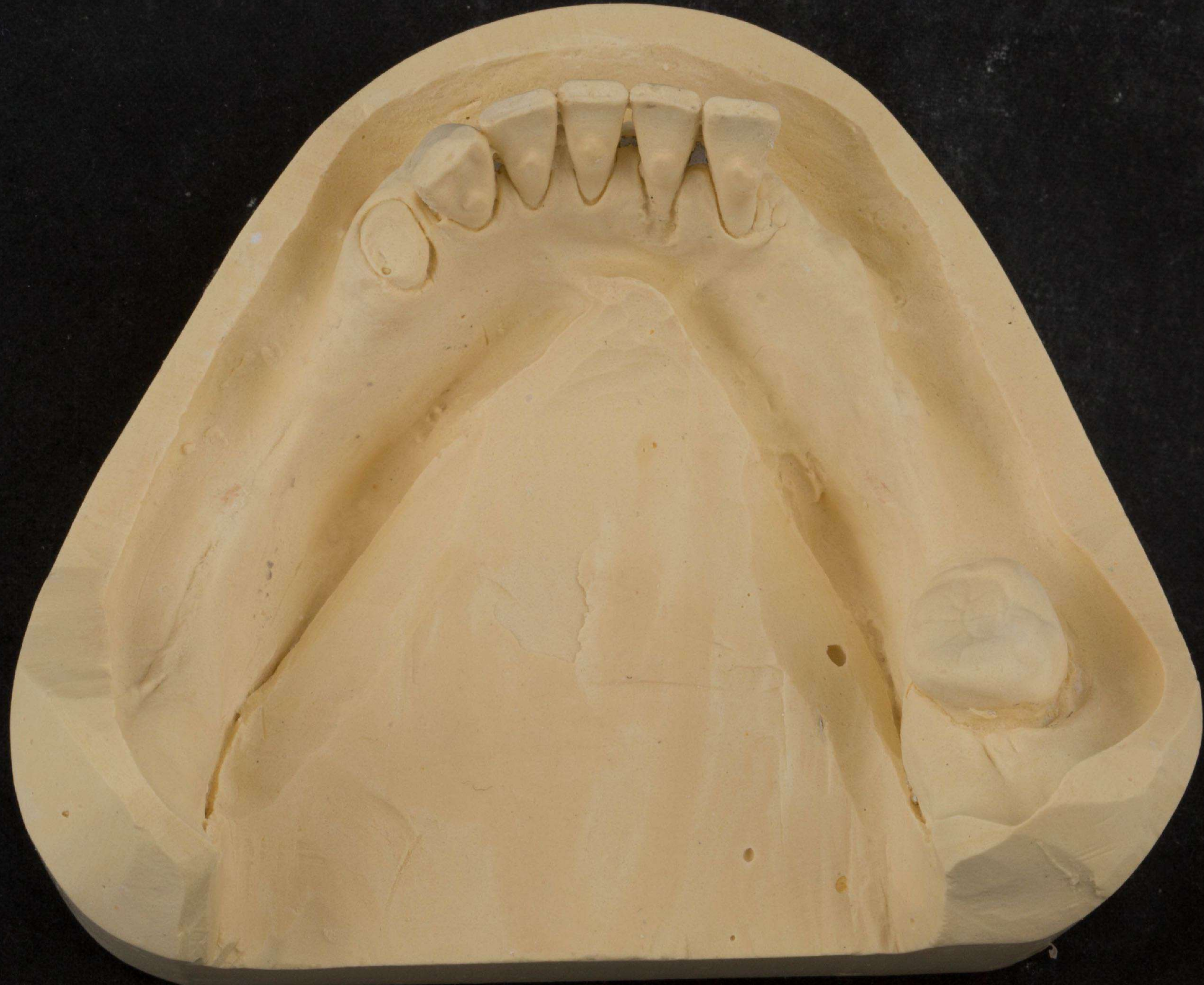


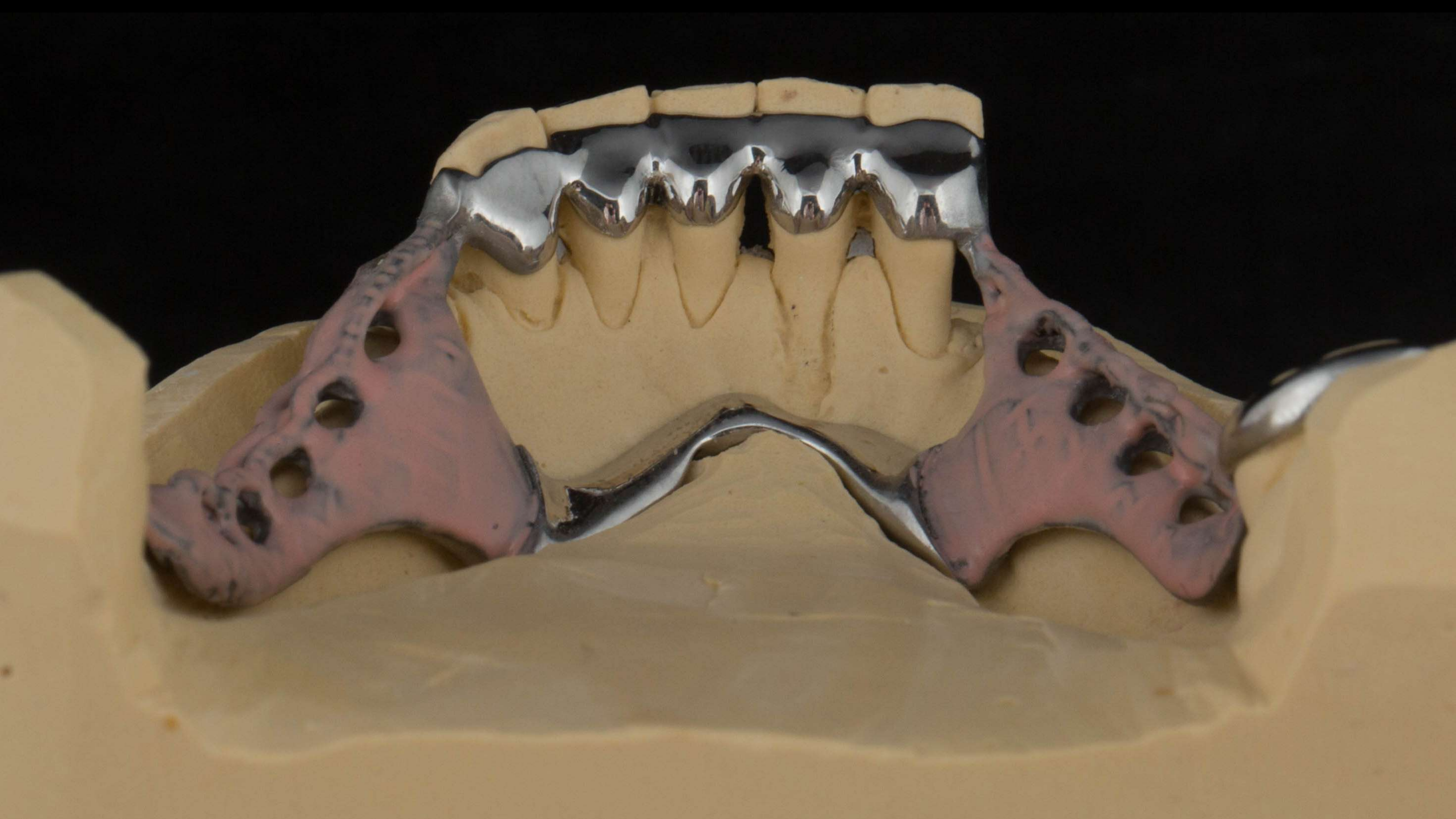




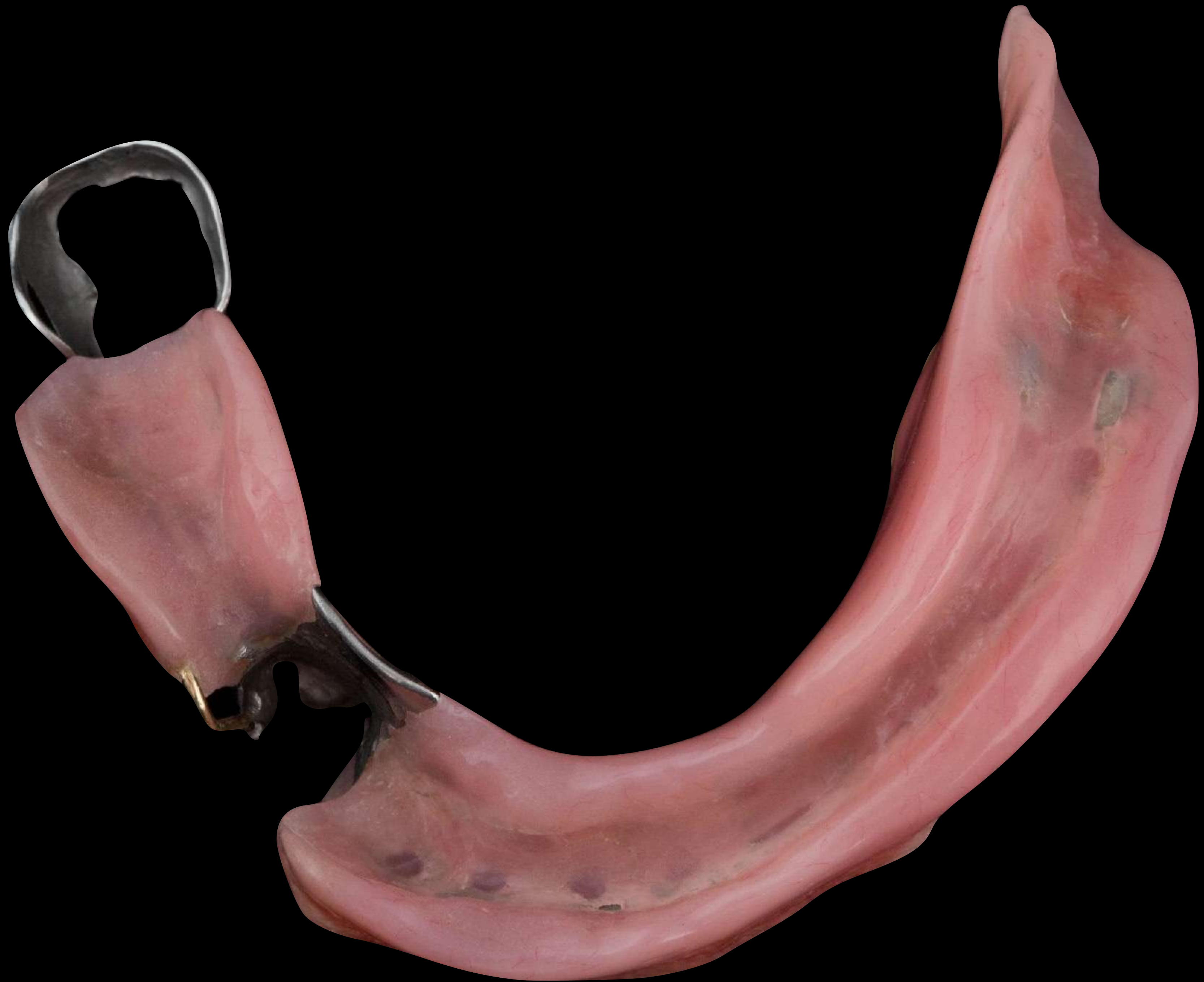


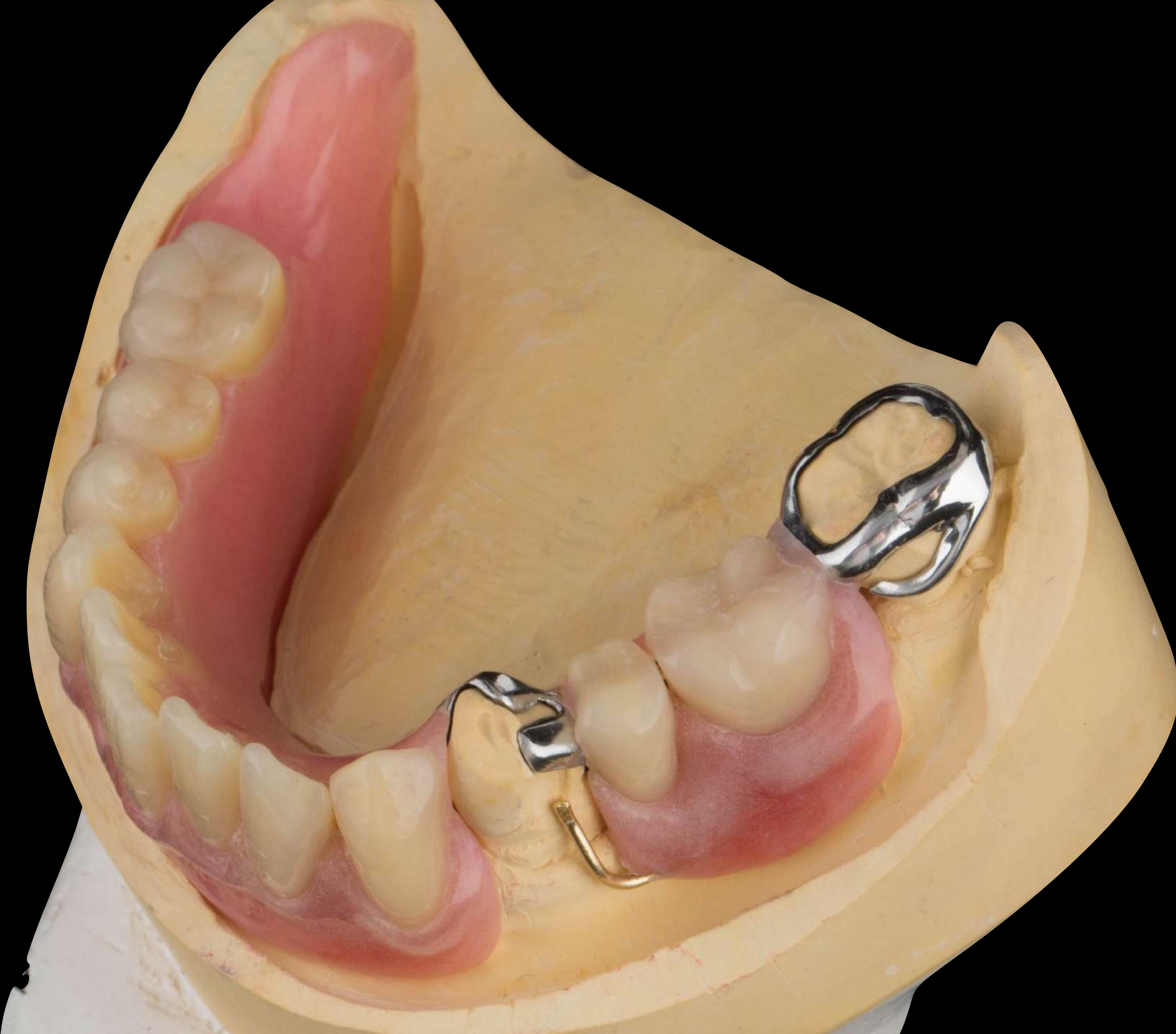


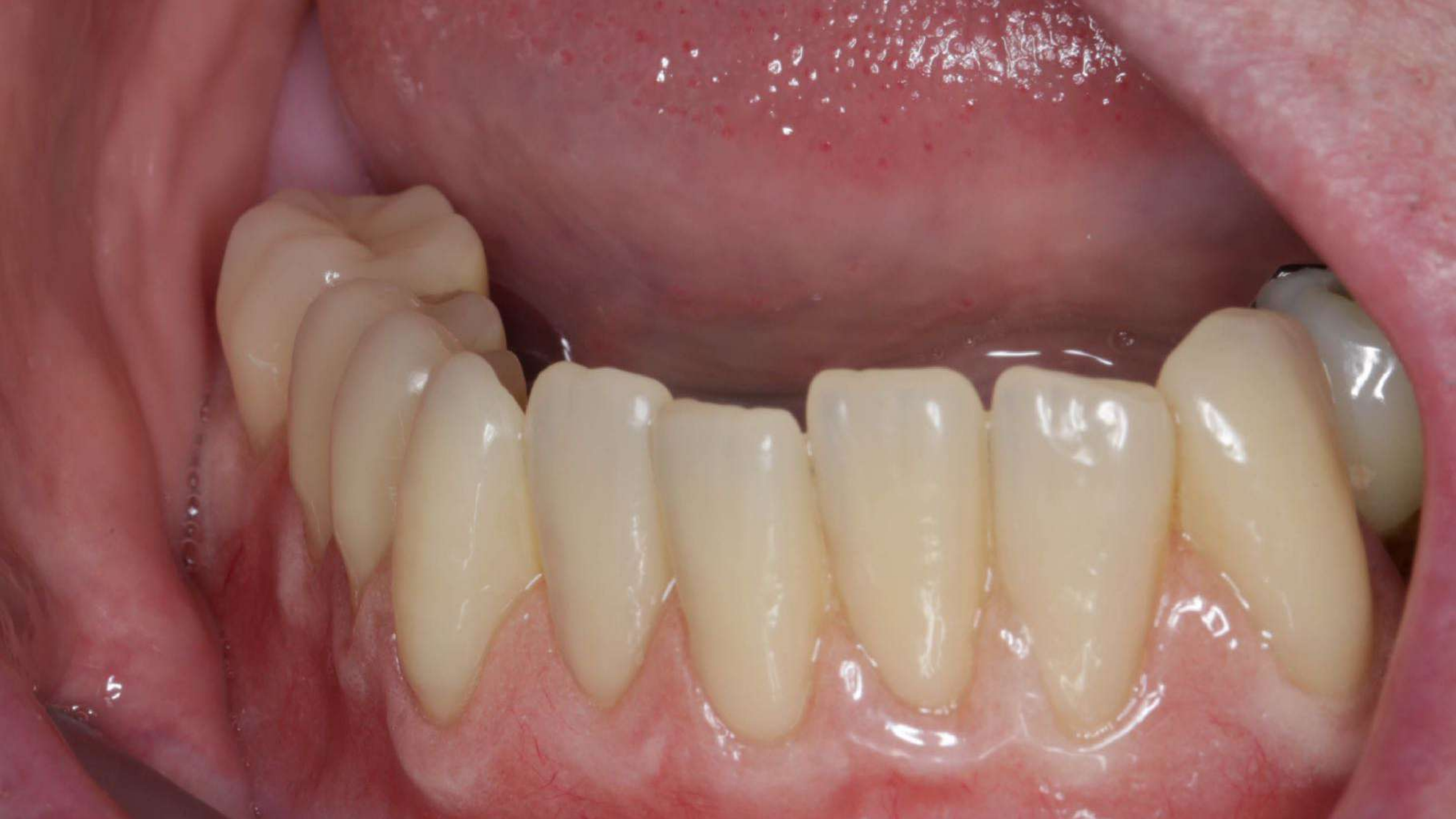Extension of free end saddles

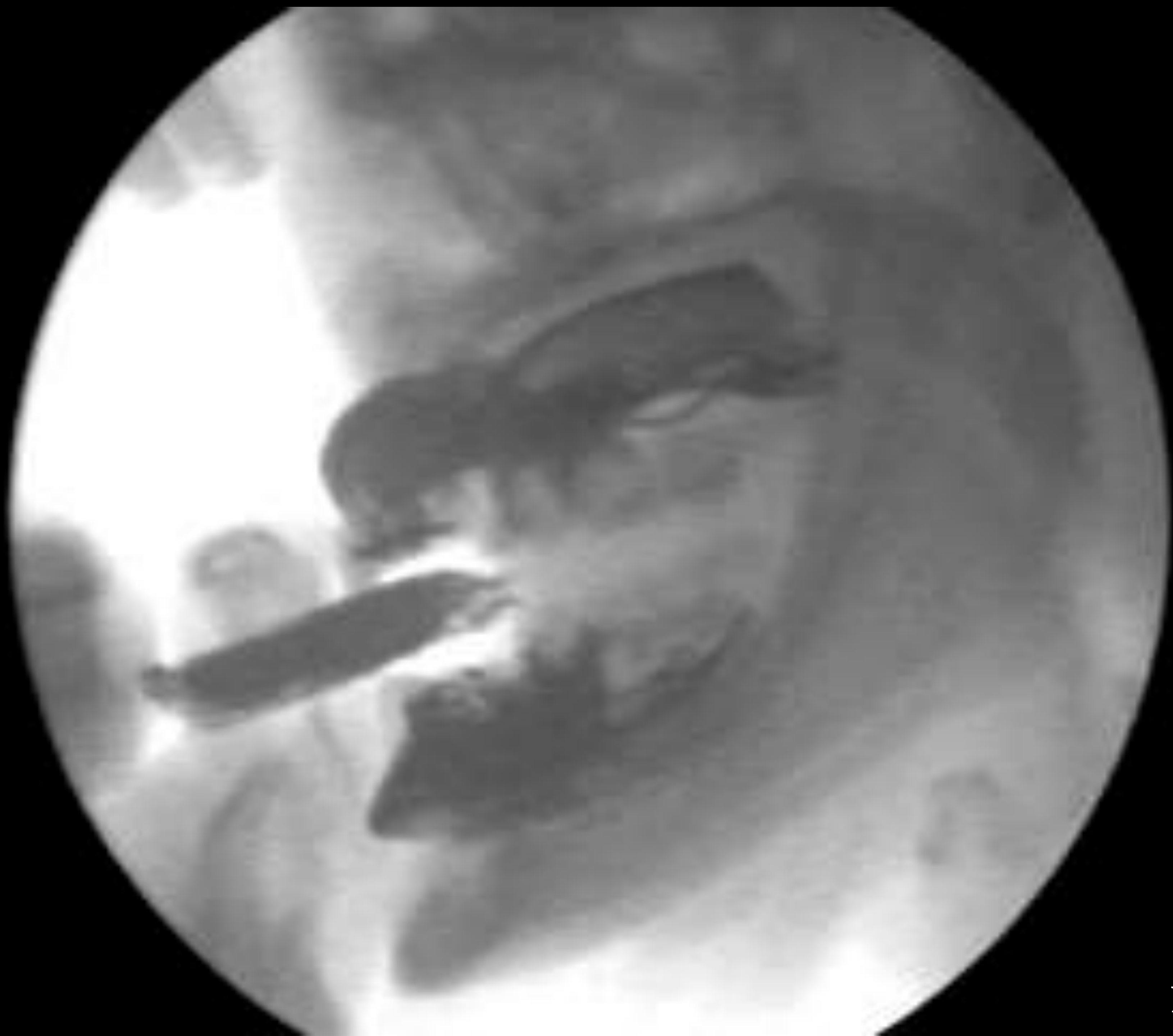




2 clasps
per
denture



Patient communication



Prof Roger Watson



Consultation discussion



Over
promise

Under
promise

Under
deliver

Over
deliver

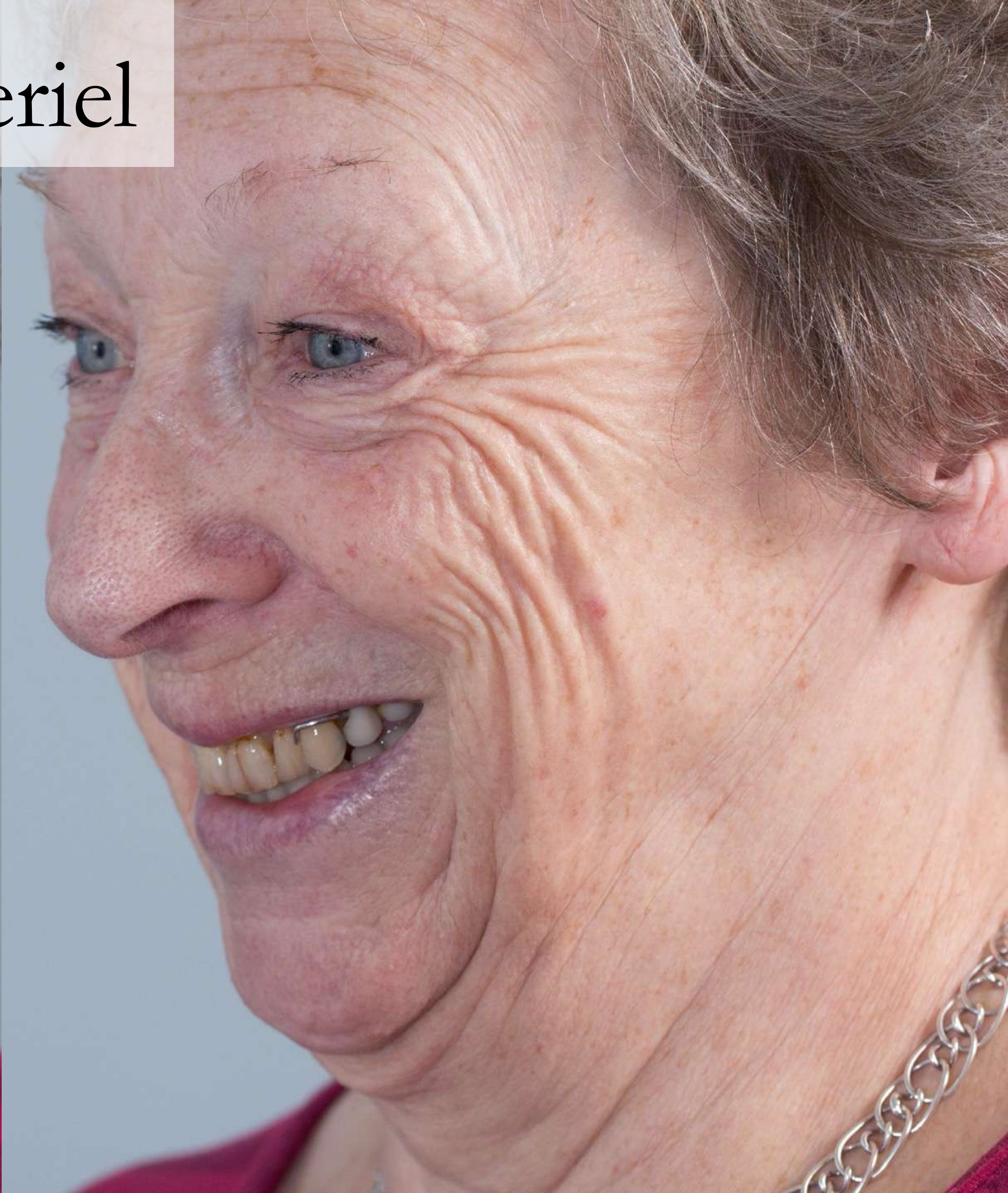
Over
promise

Under
deliver

Under
promise

Over
deliver

Meriel

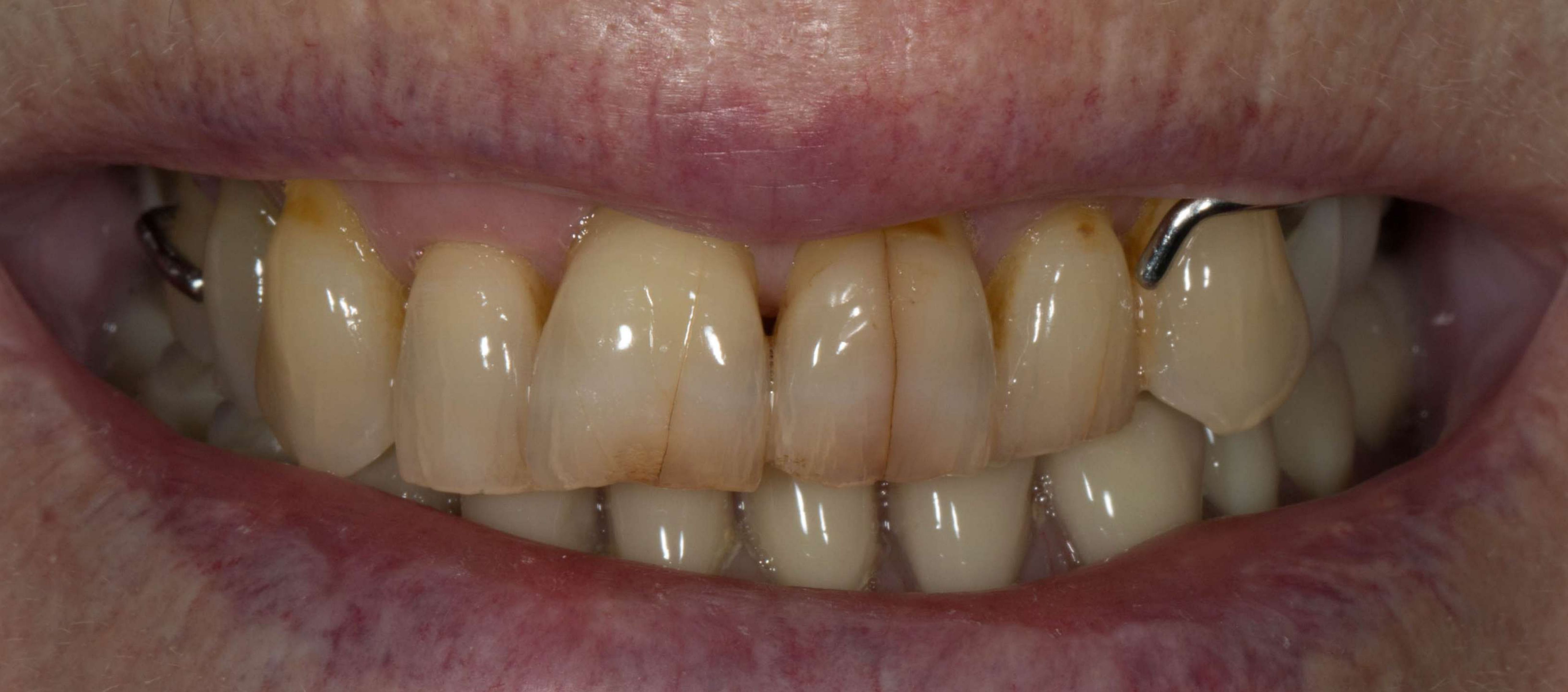



Meriel

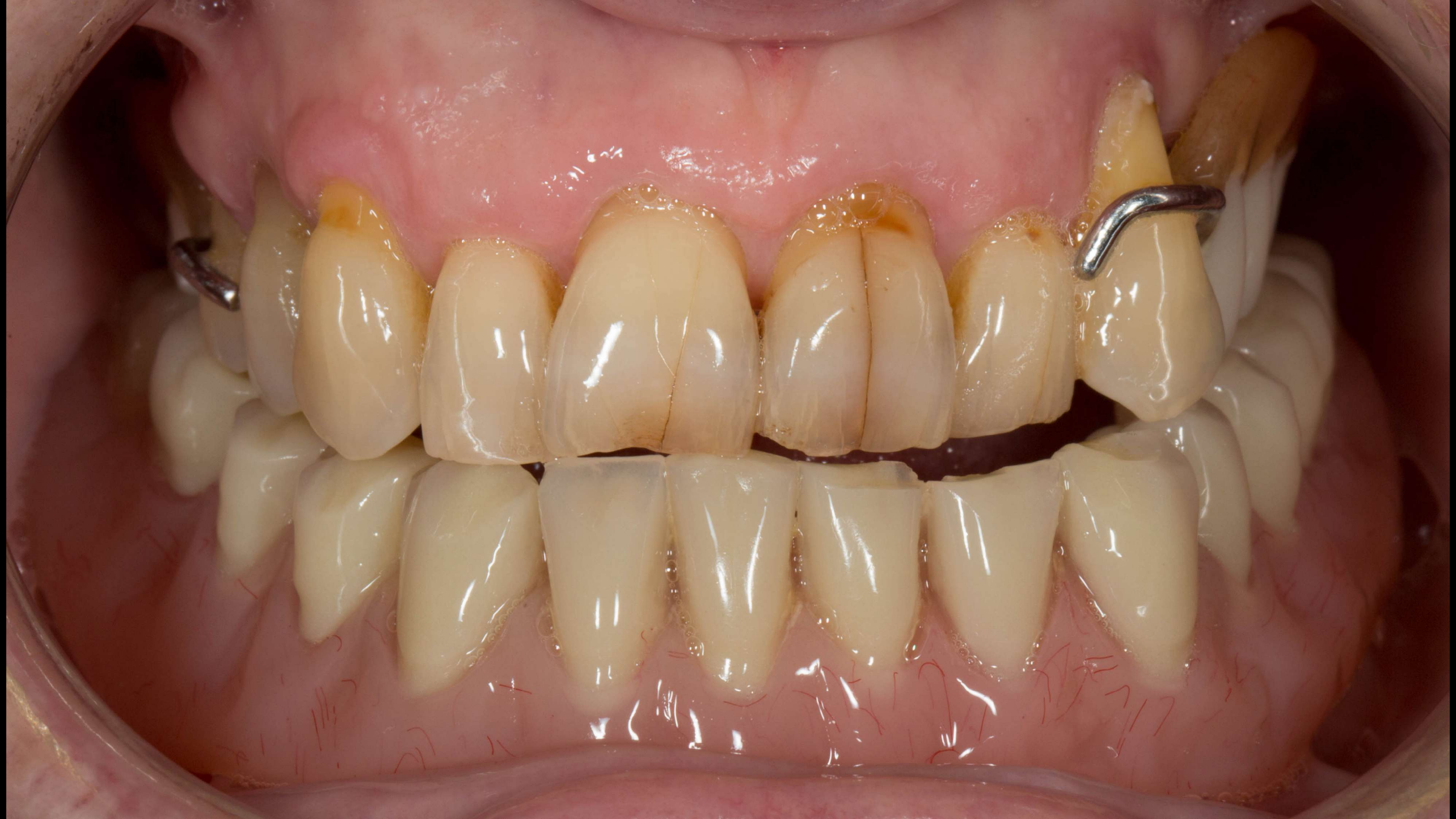Upper - partial denture

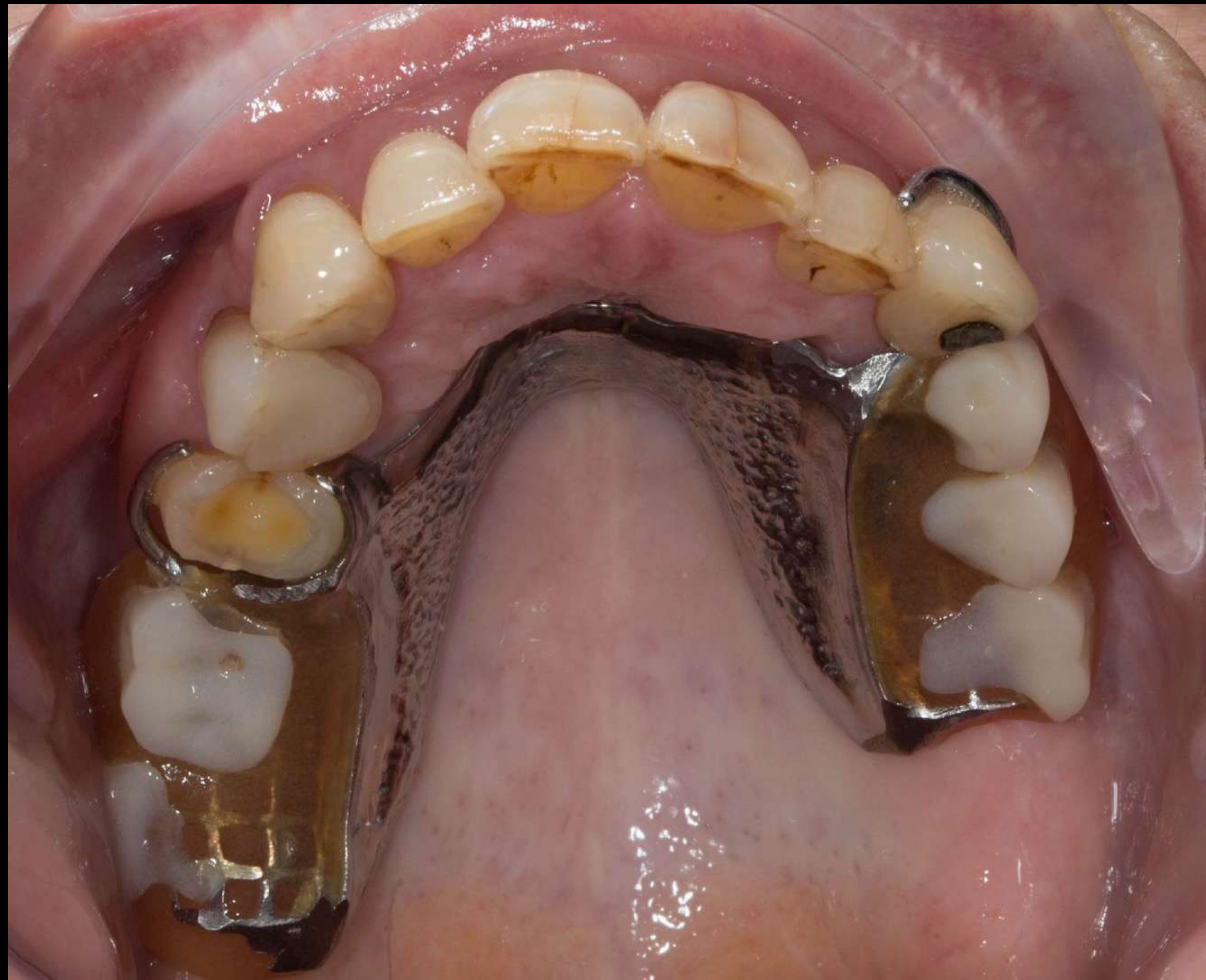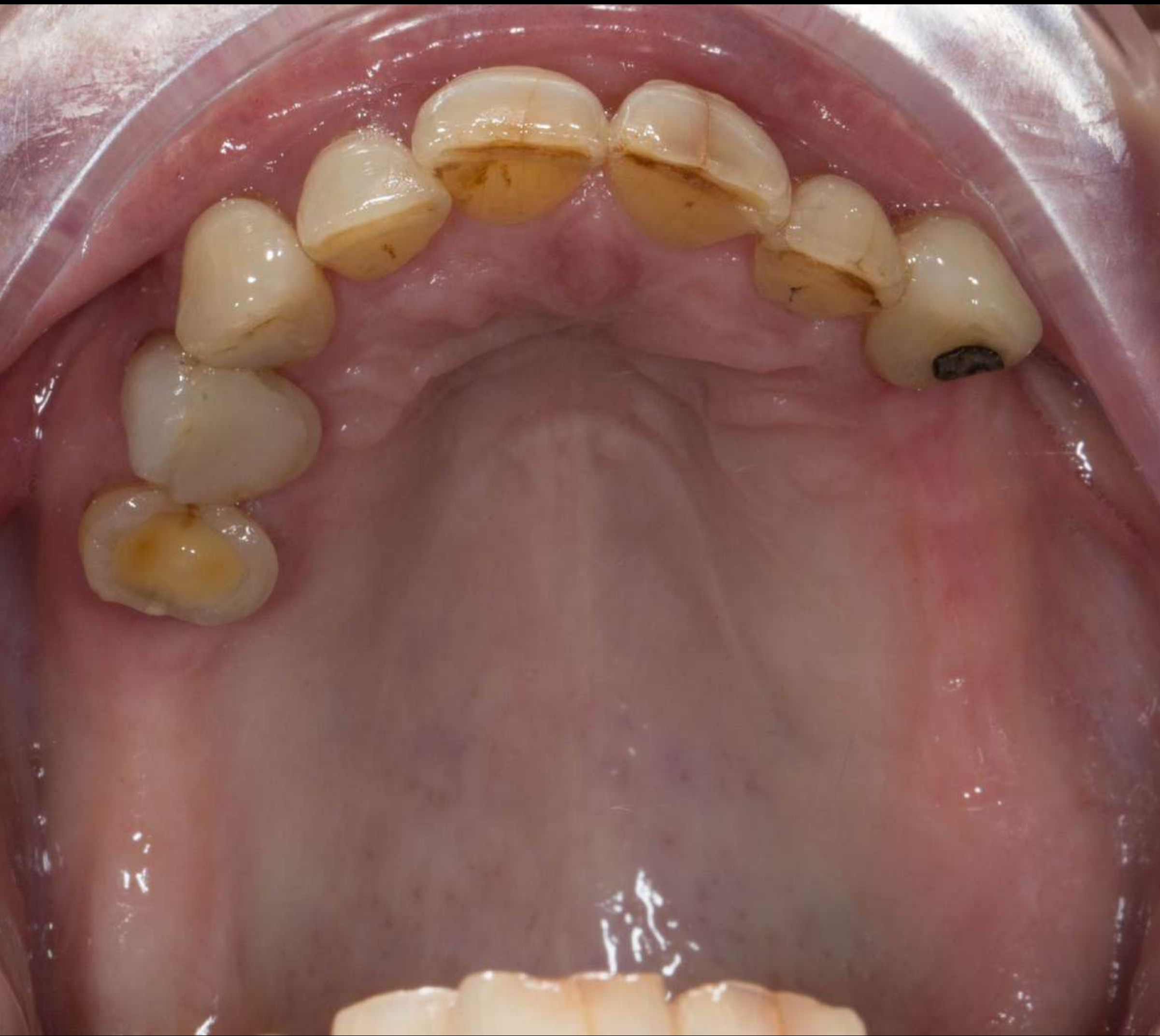Lower - implant supported complete denture

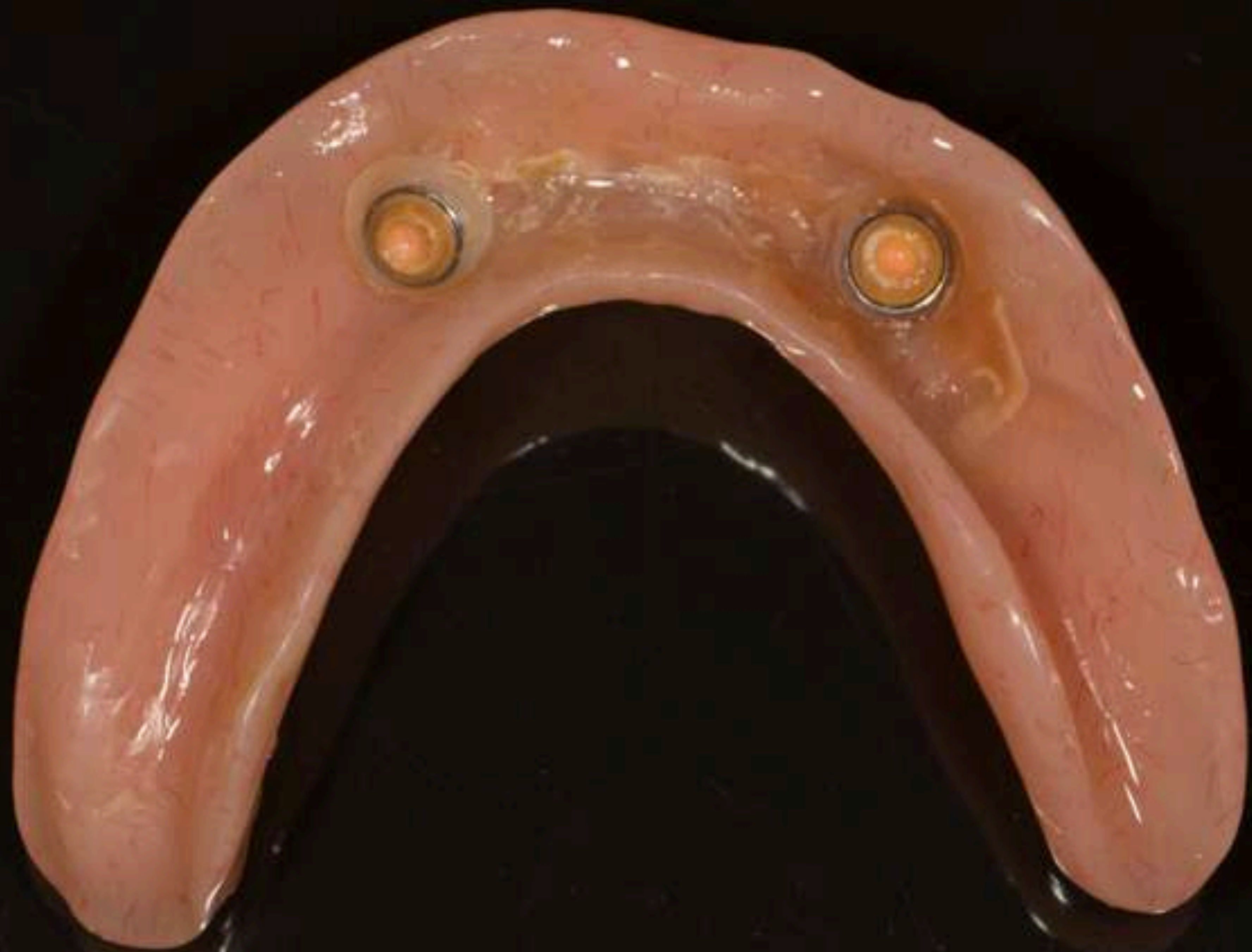

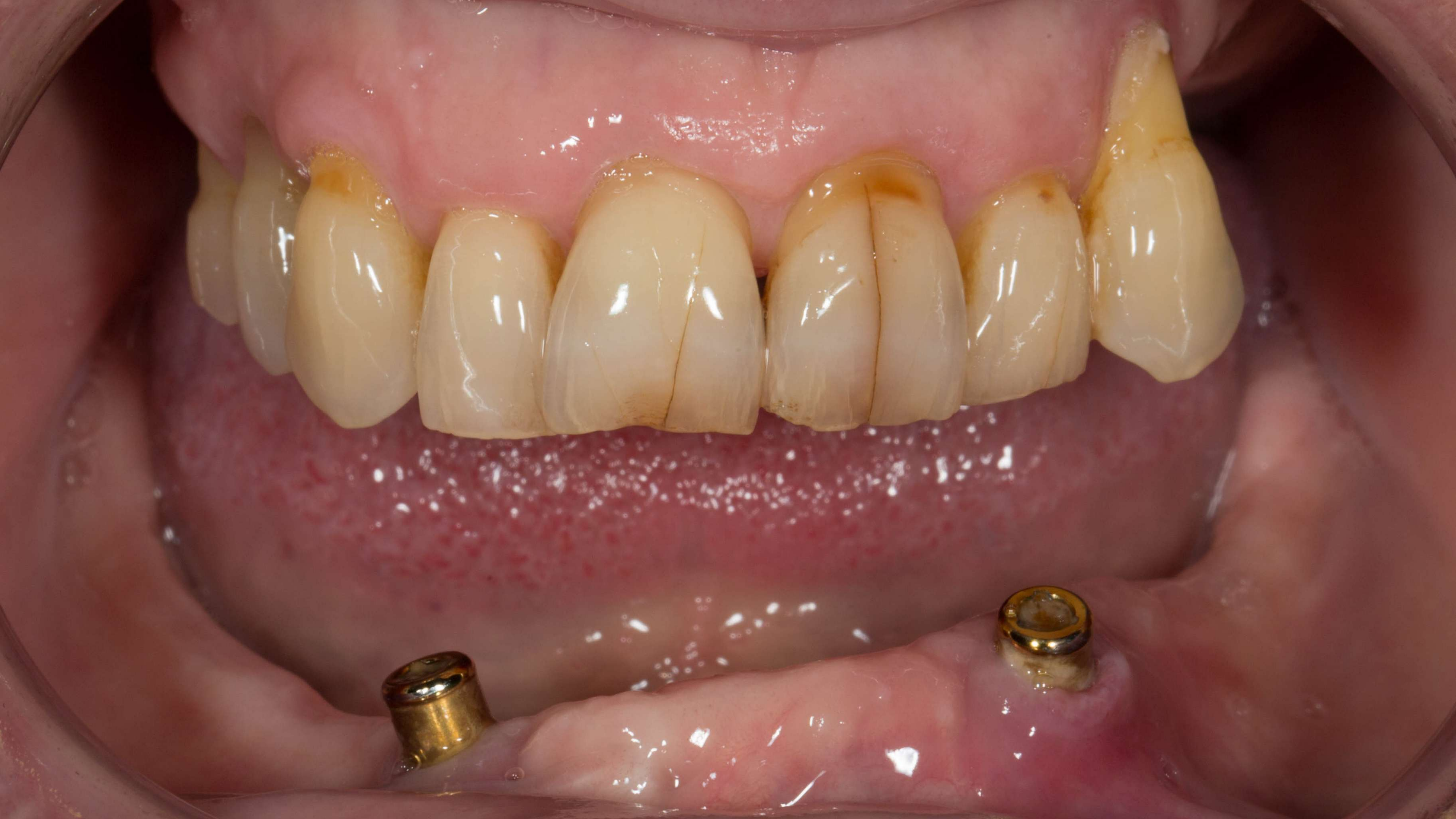Upper - partial denture

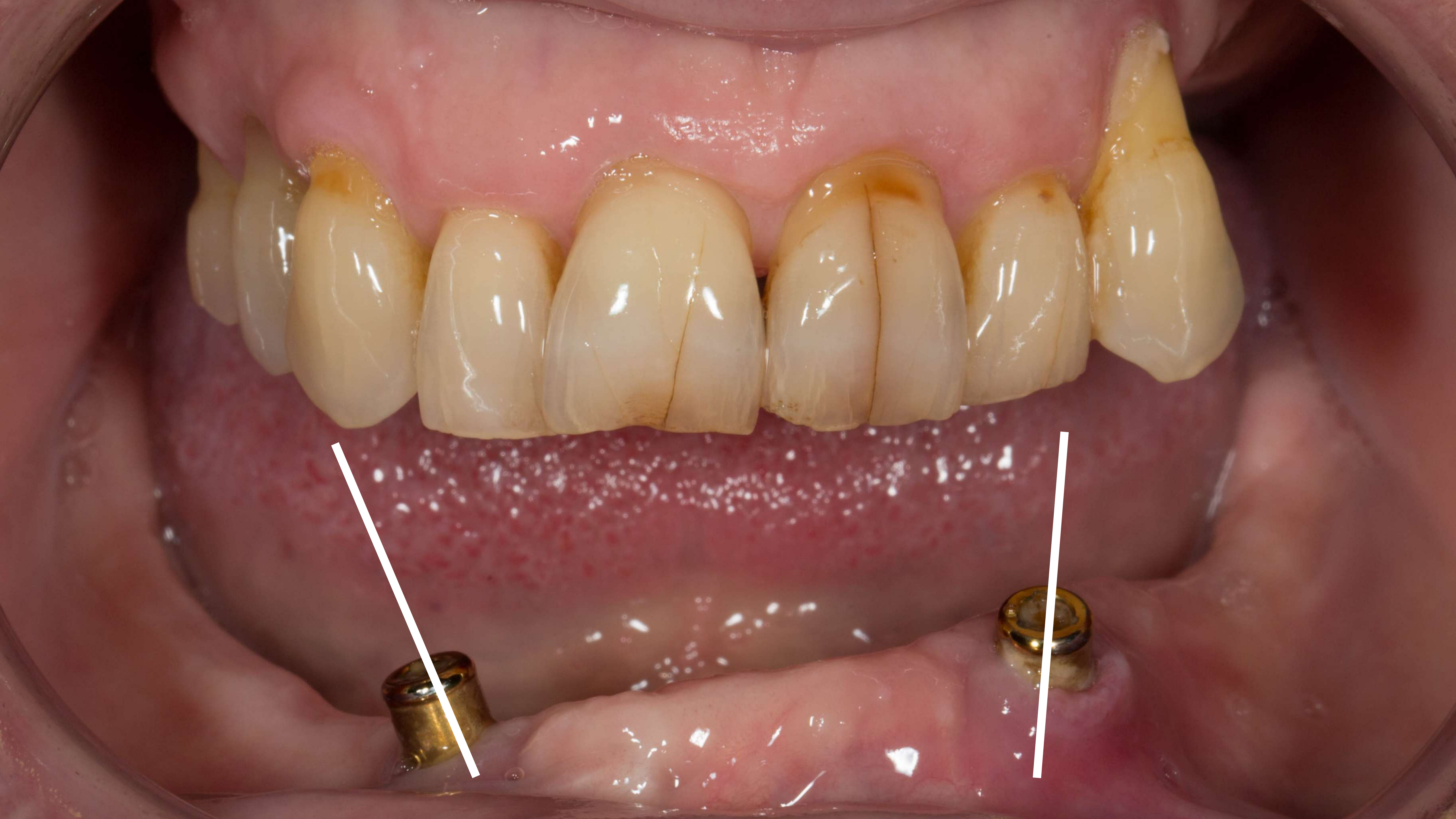Lower - implant supported complete denture

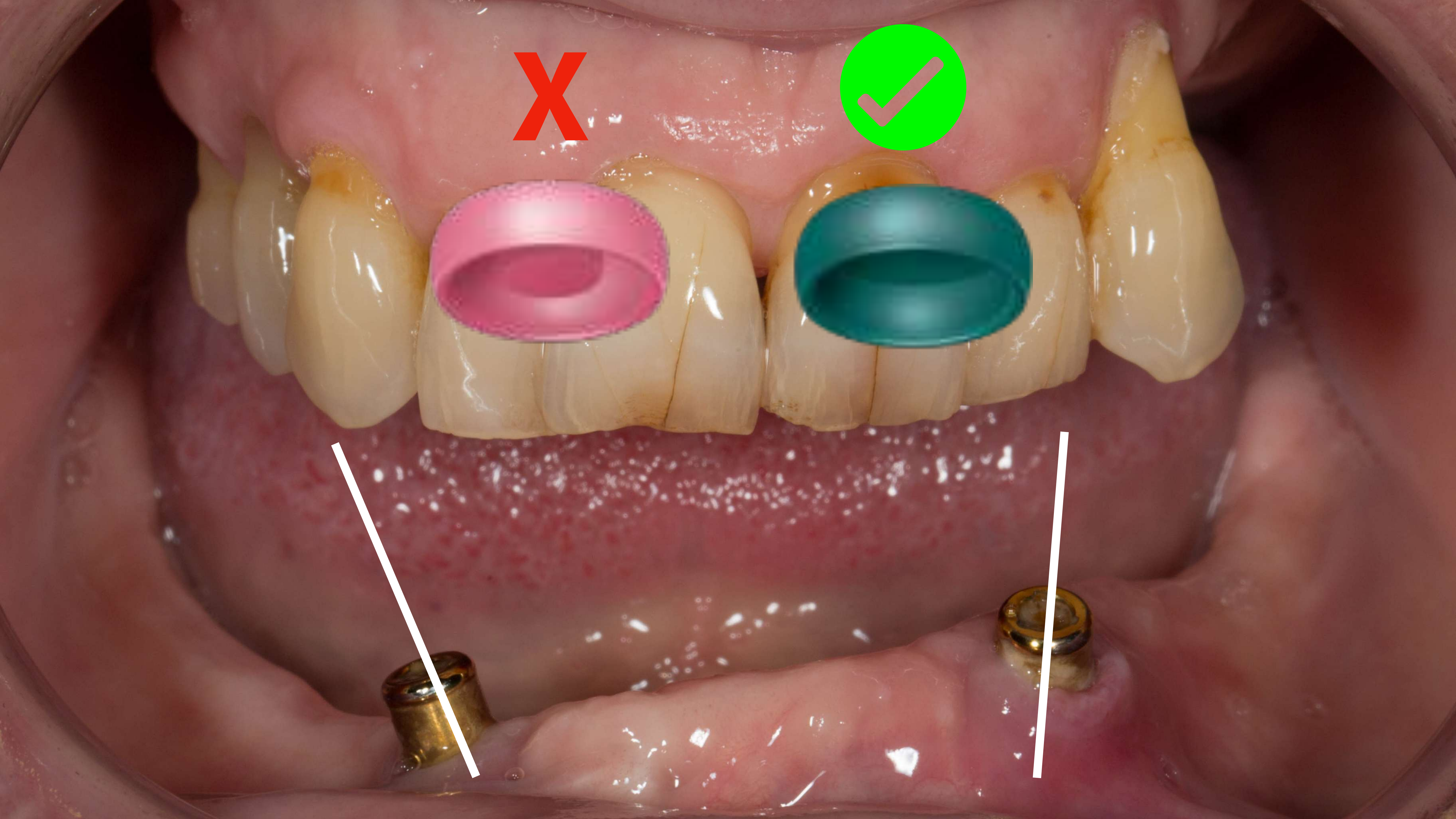




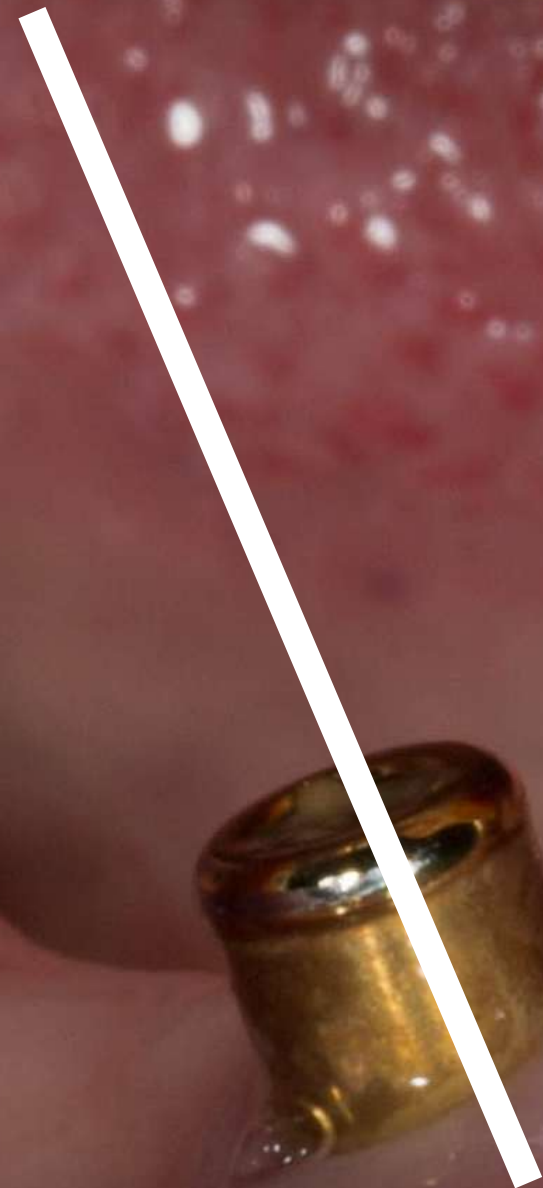



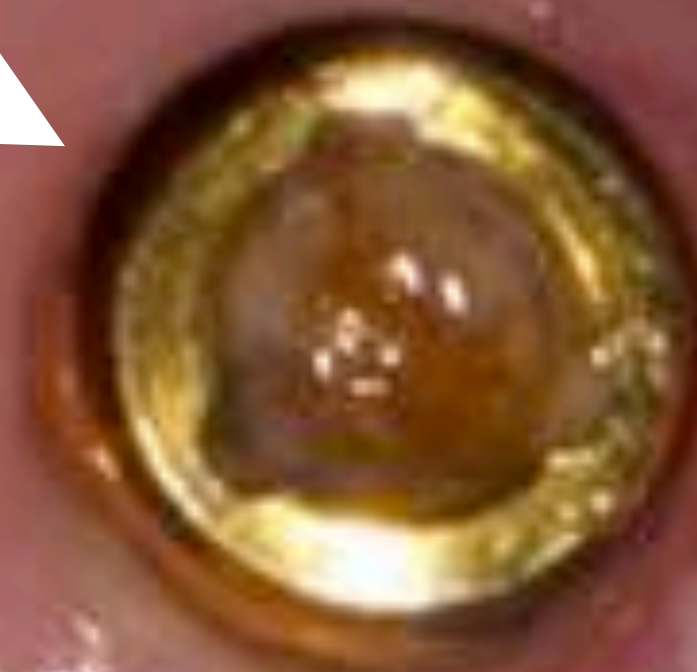
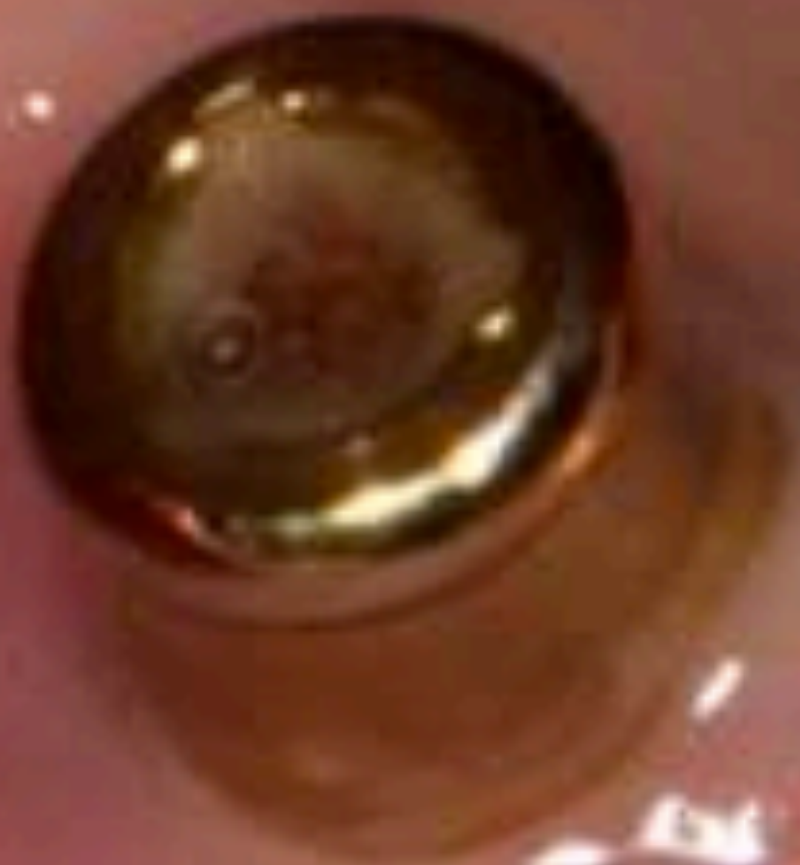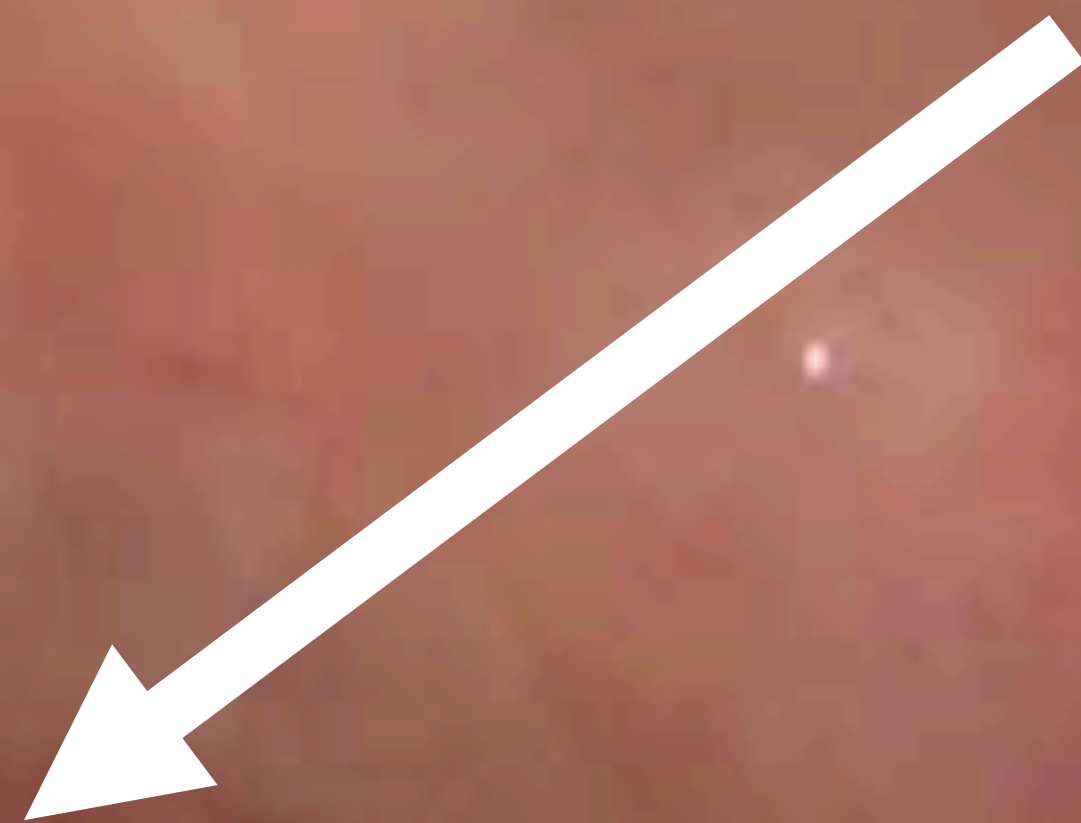


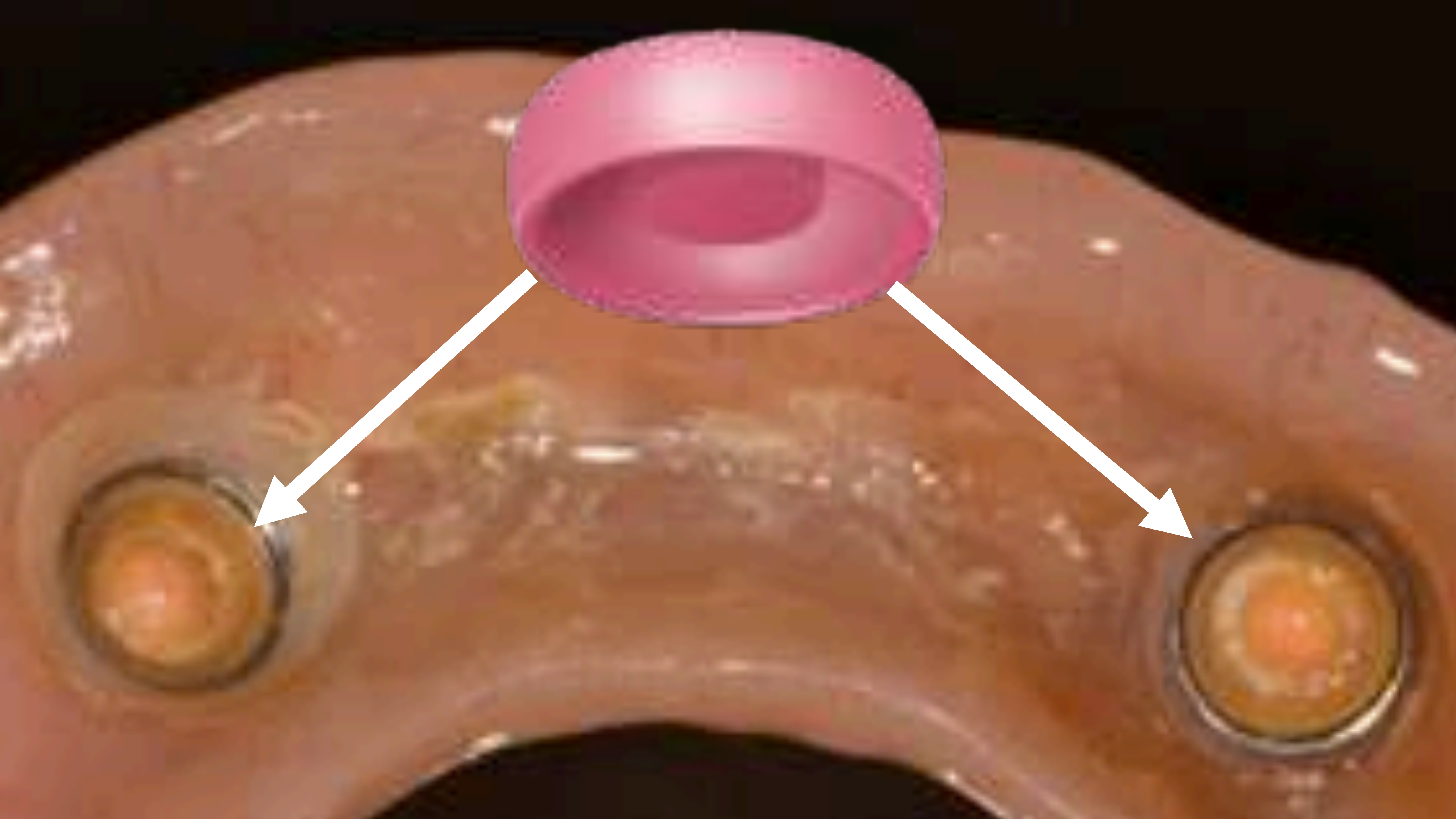


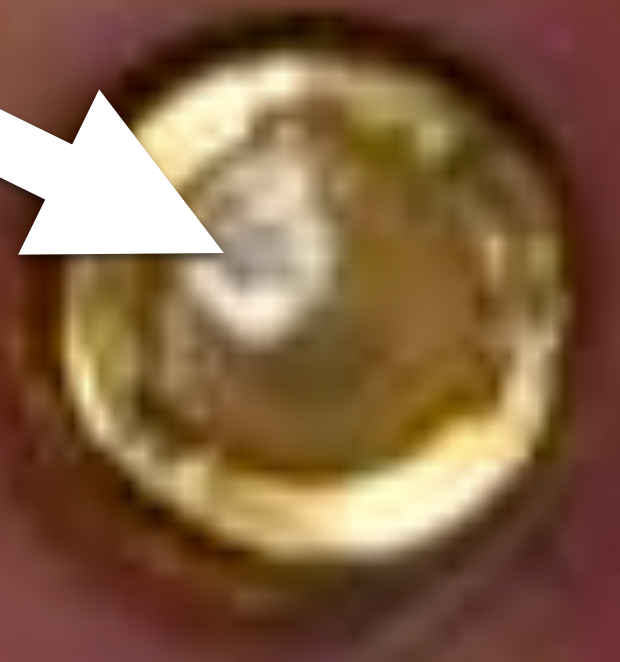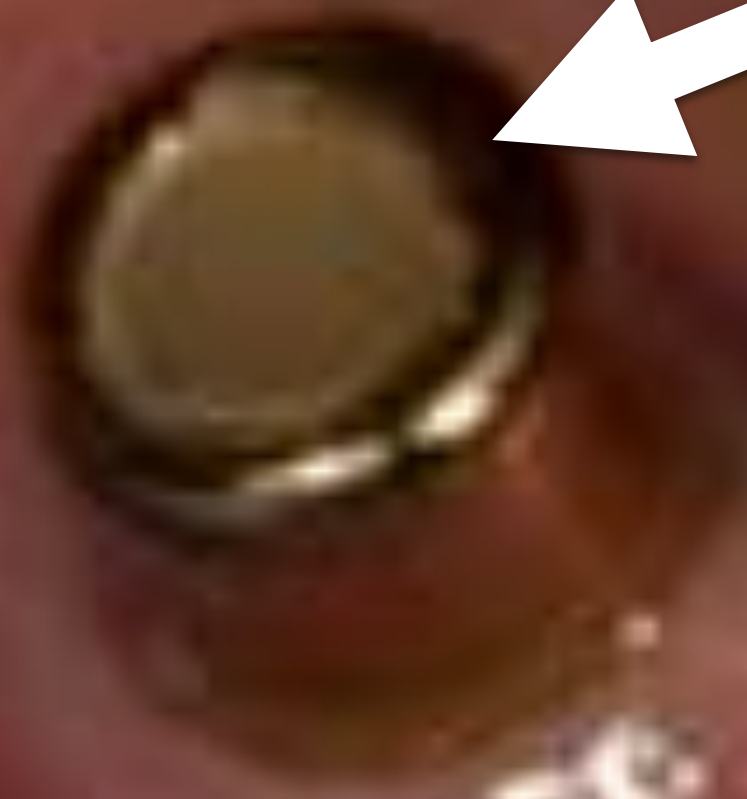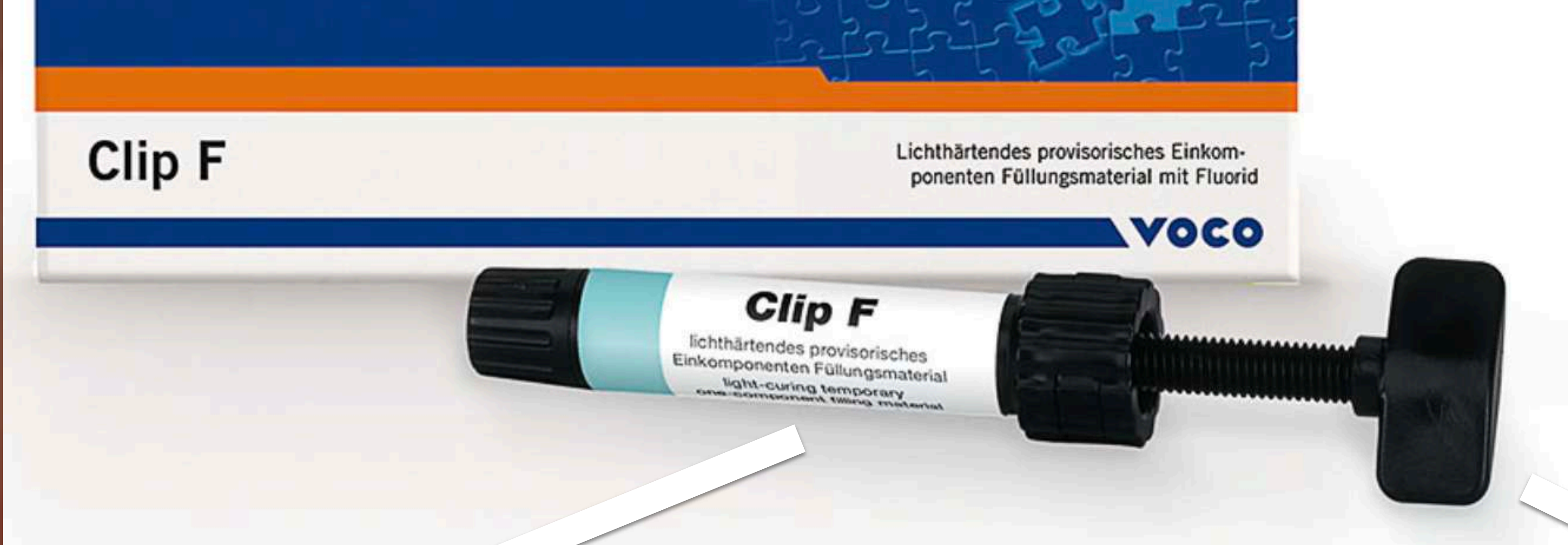X

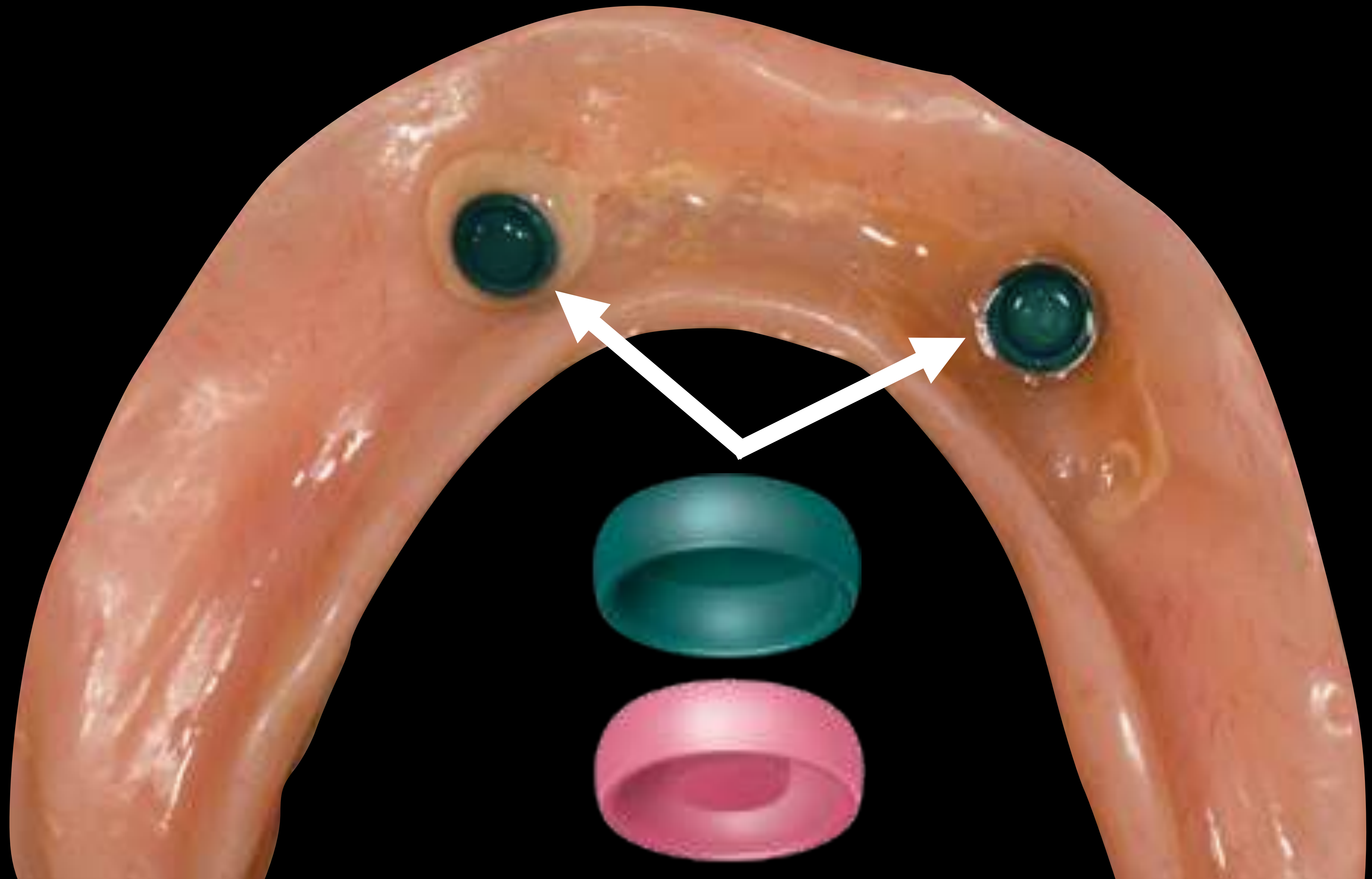


Food

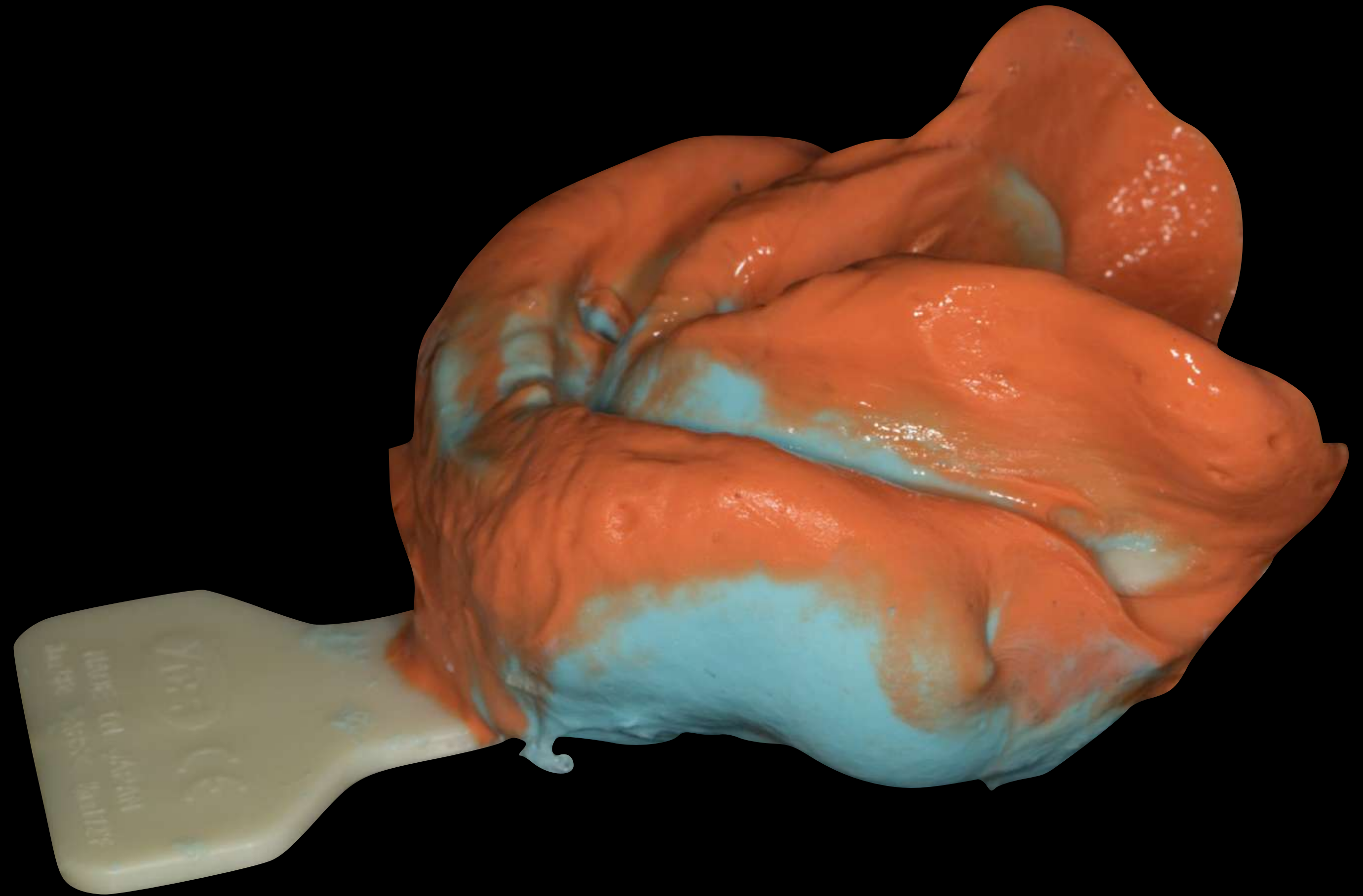
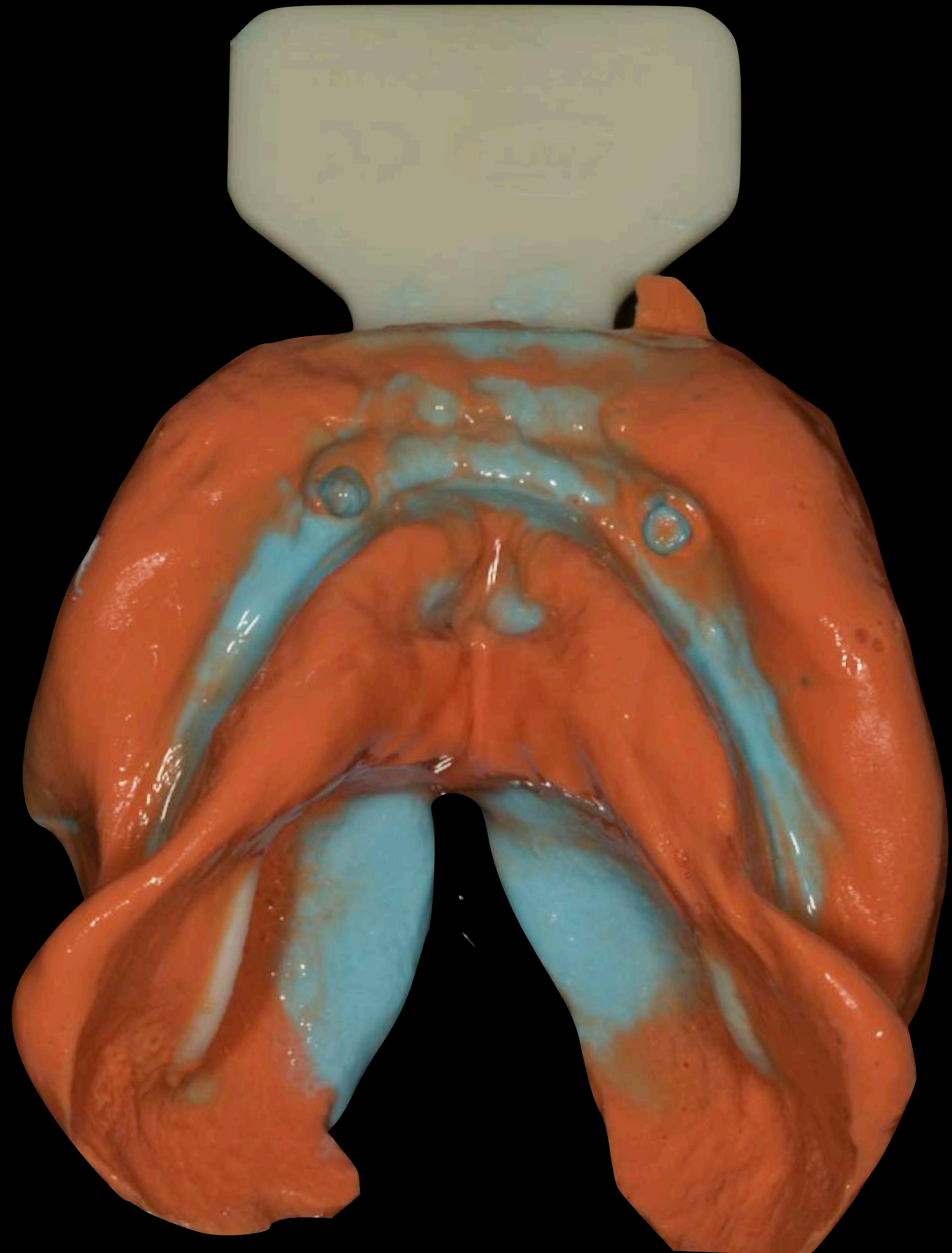




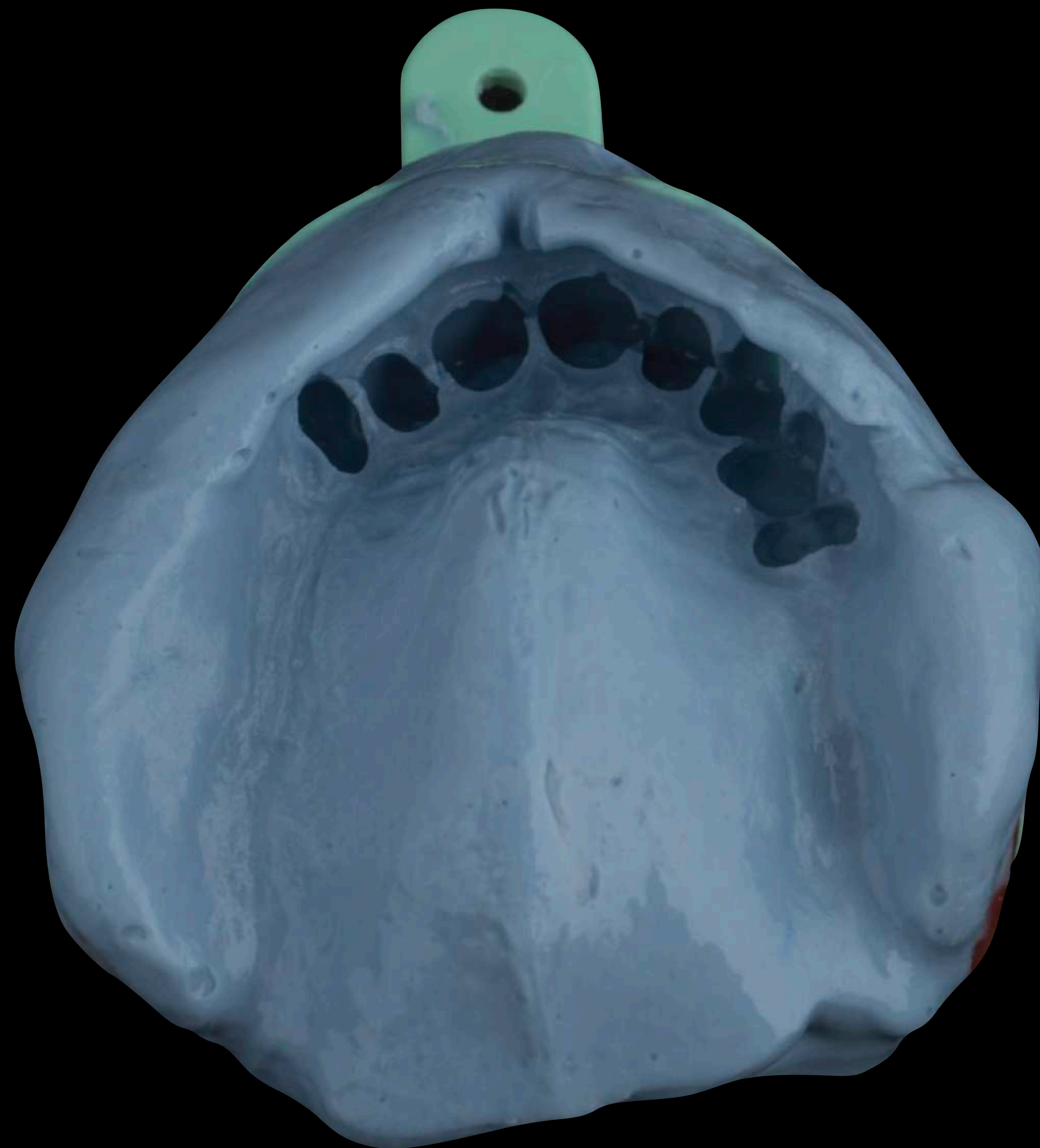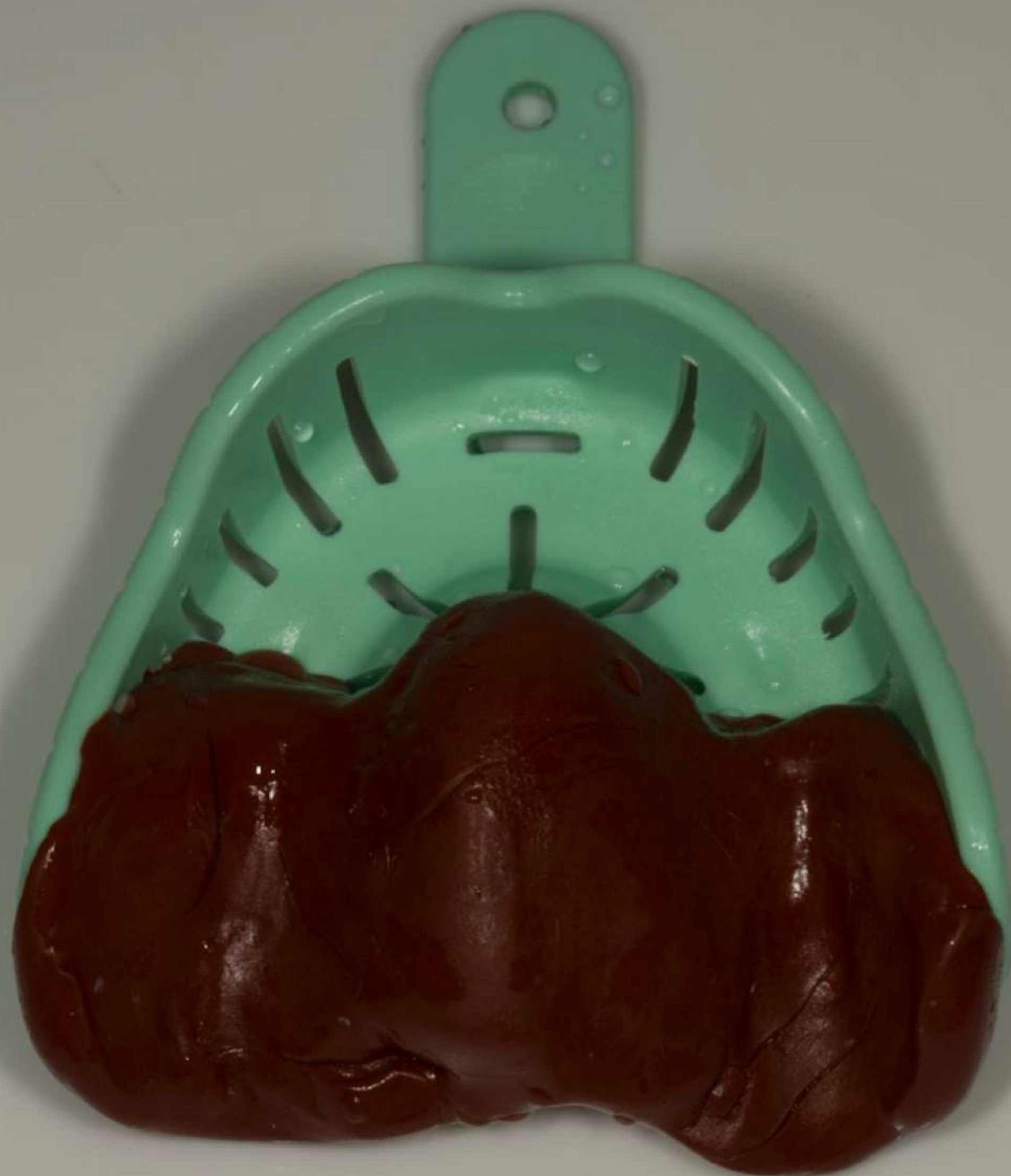




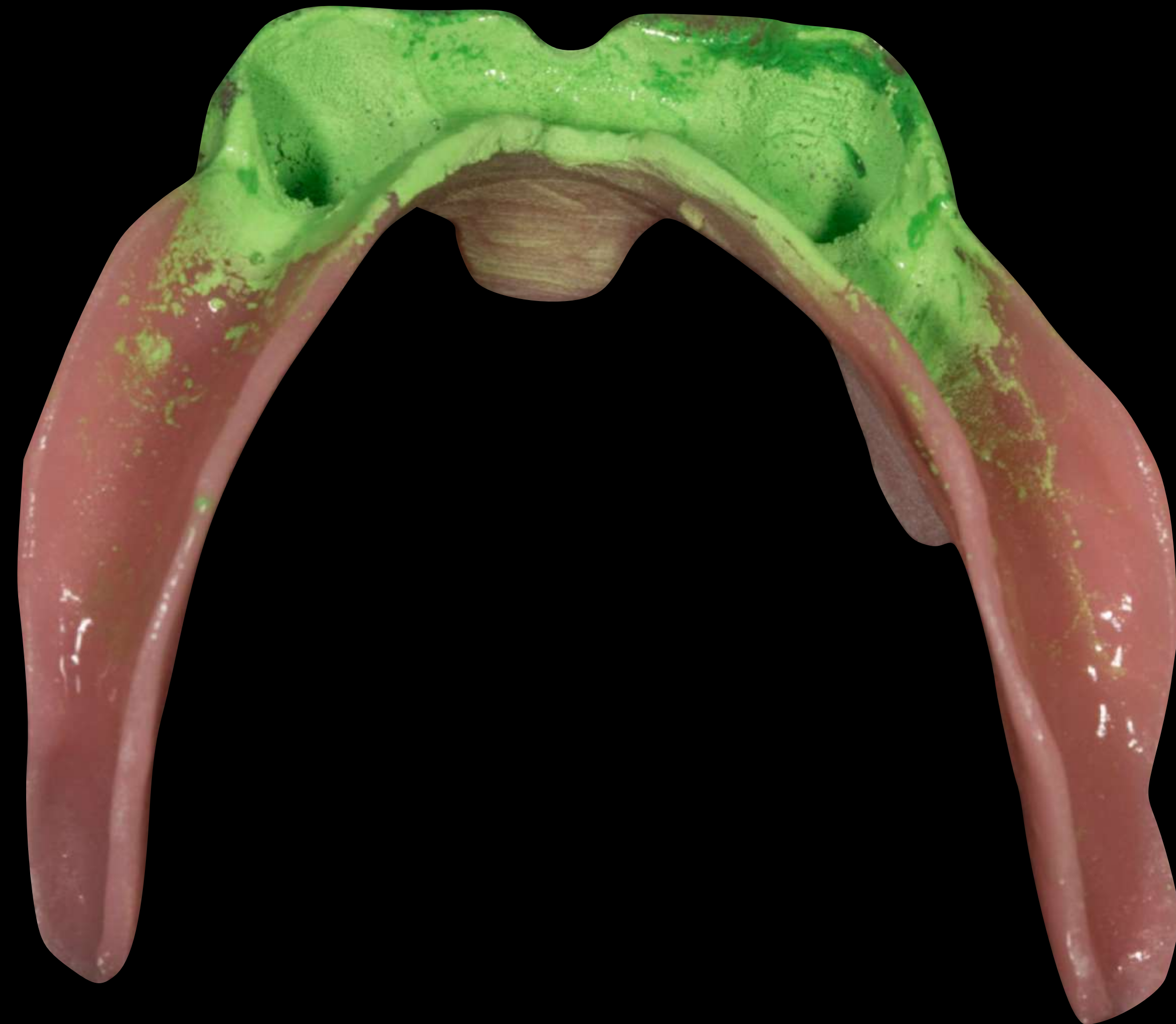
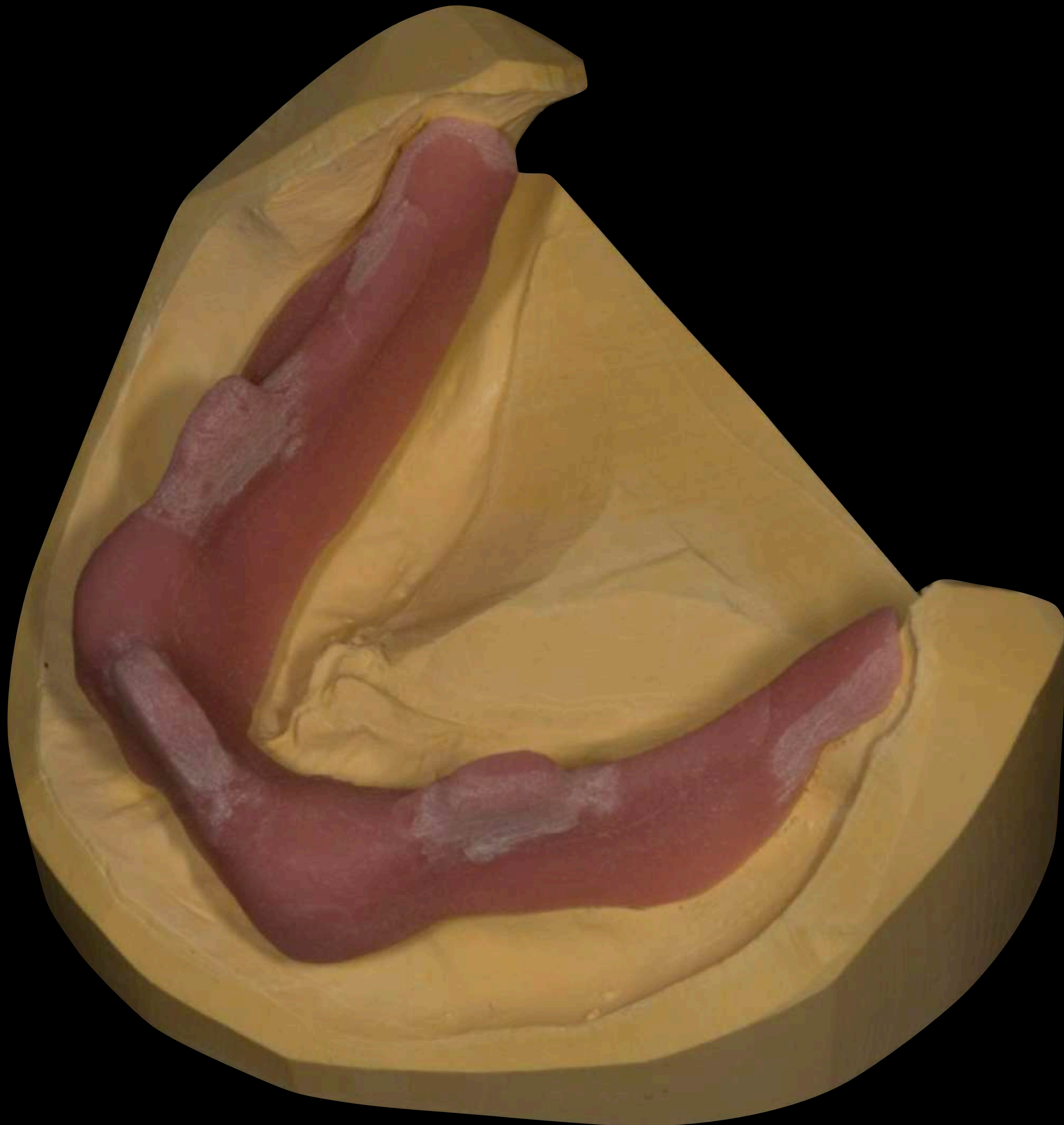
Primary impression



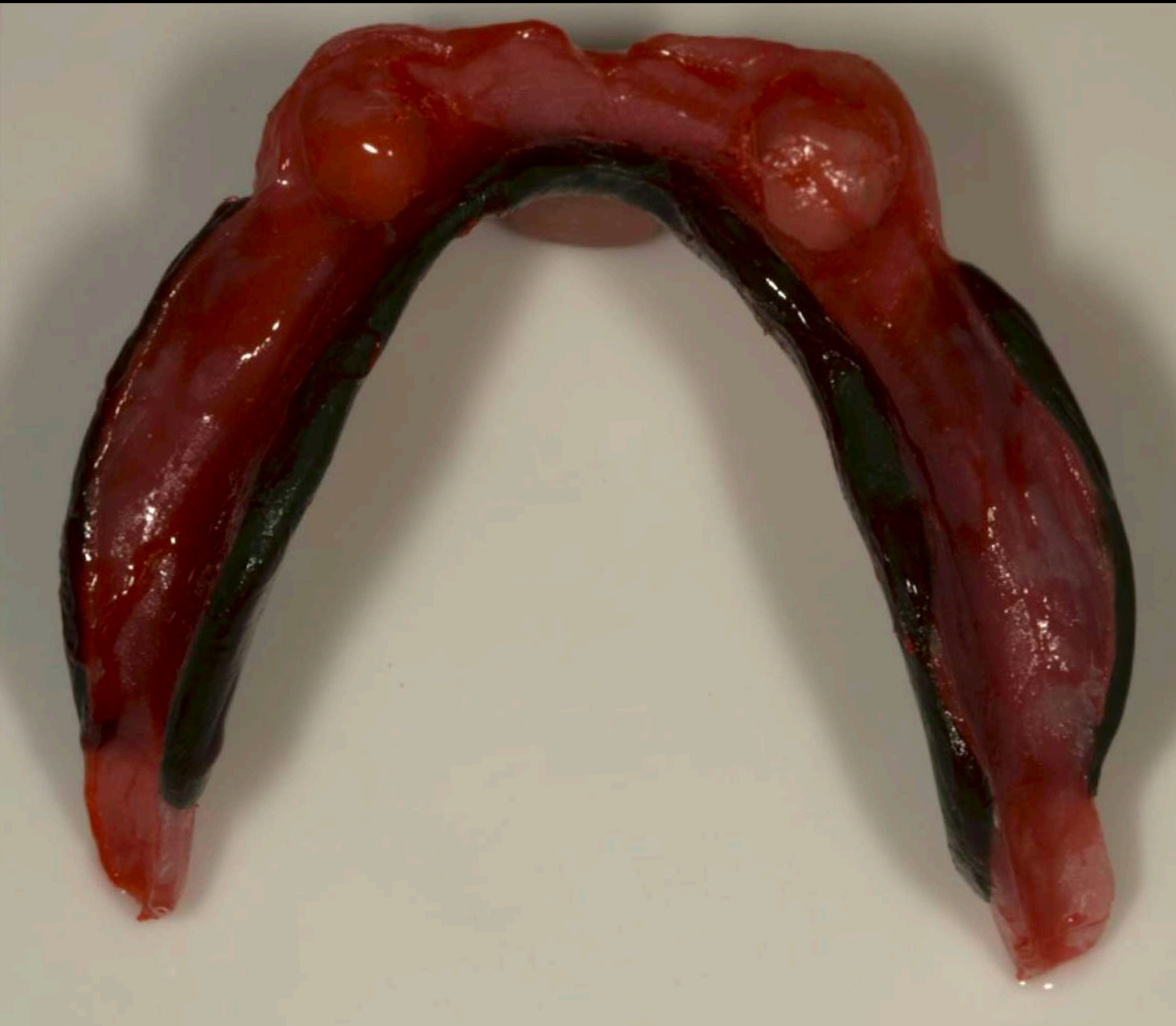Primary impression



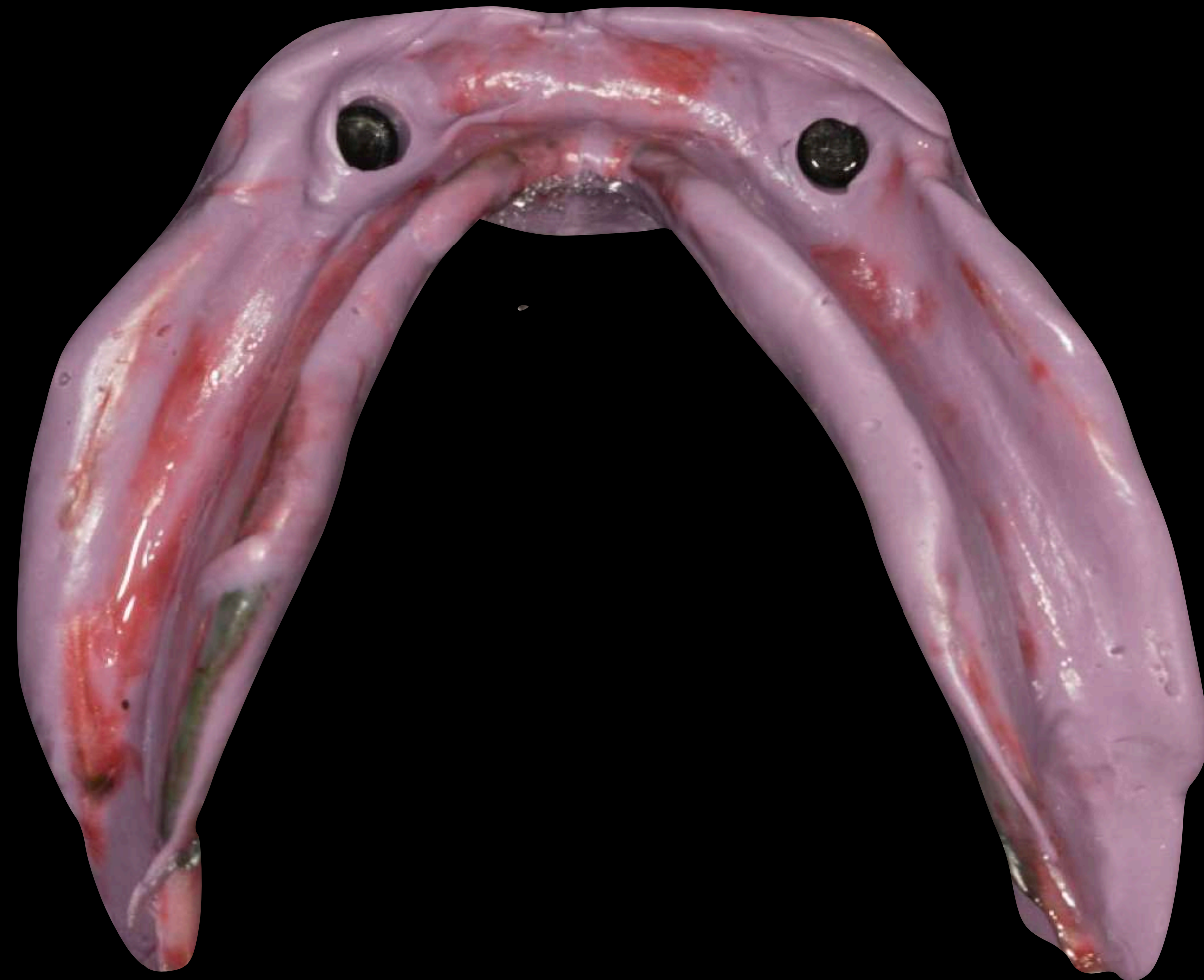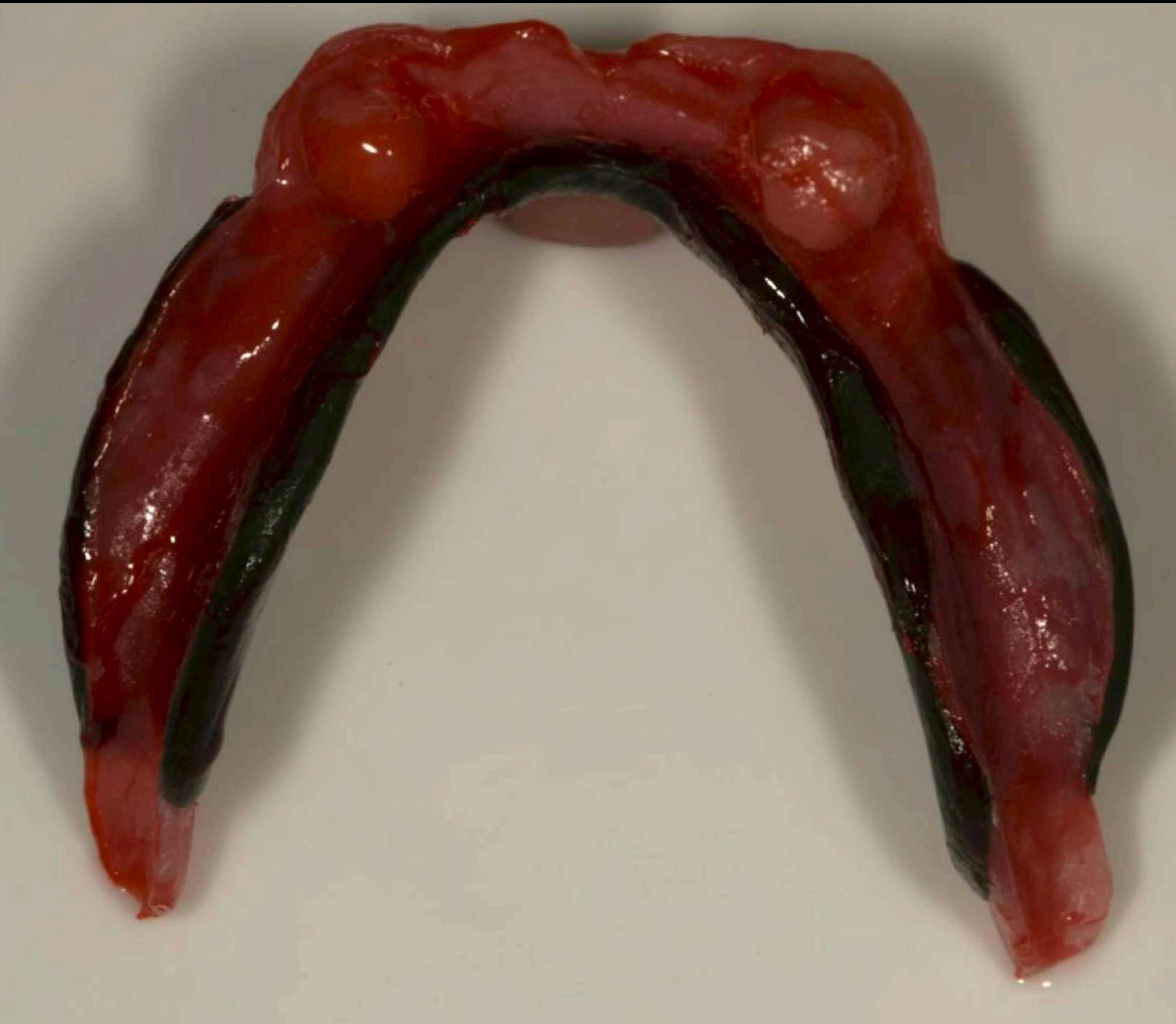Custom tray



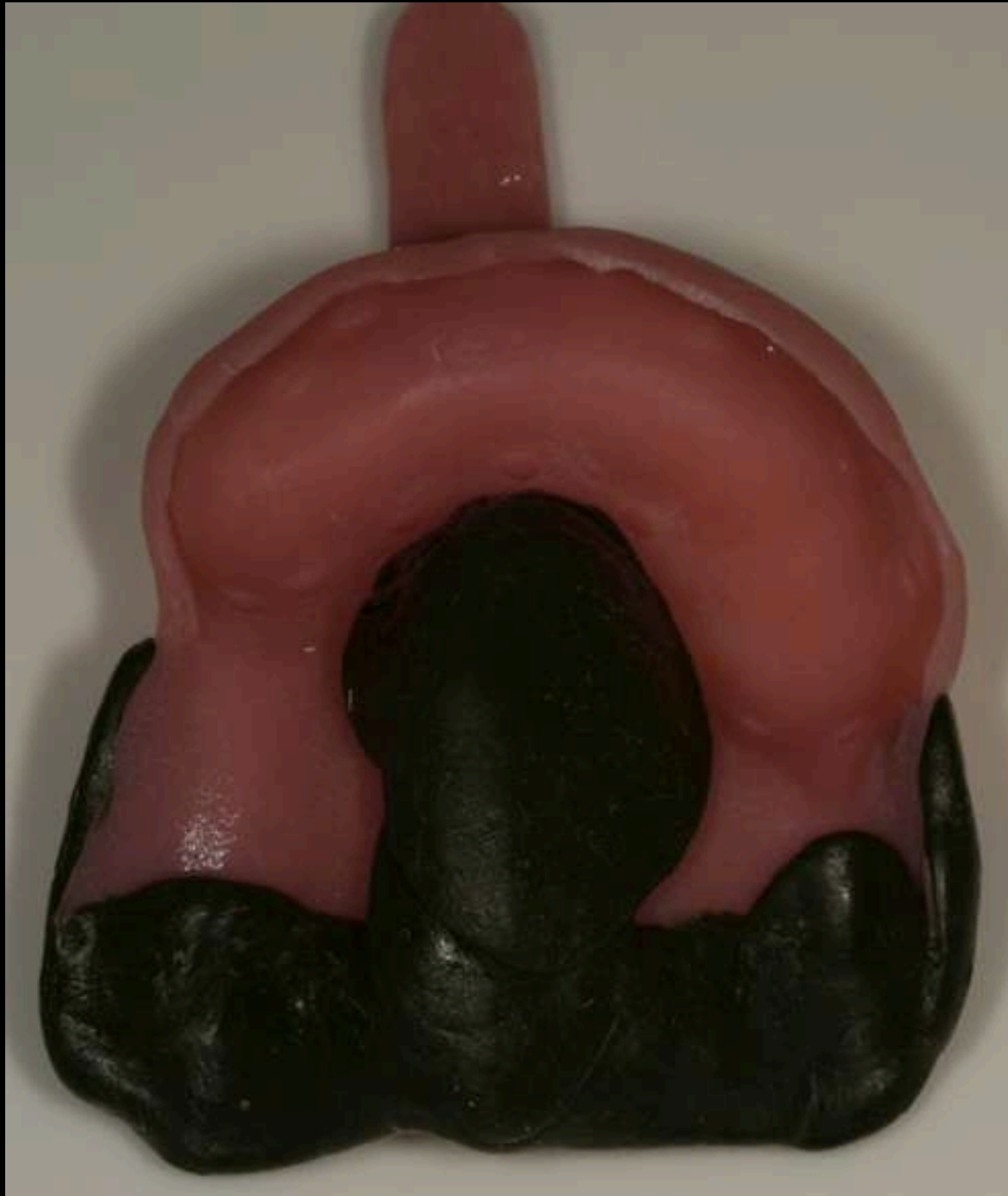Working impression



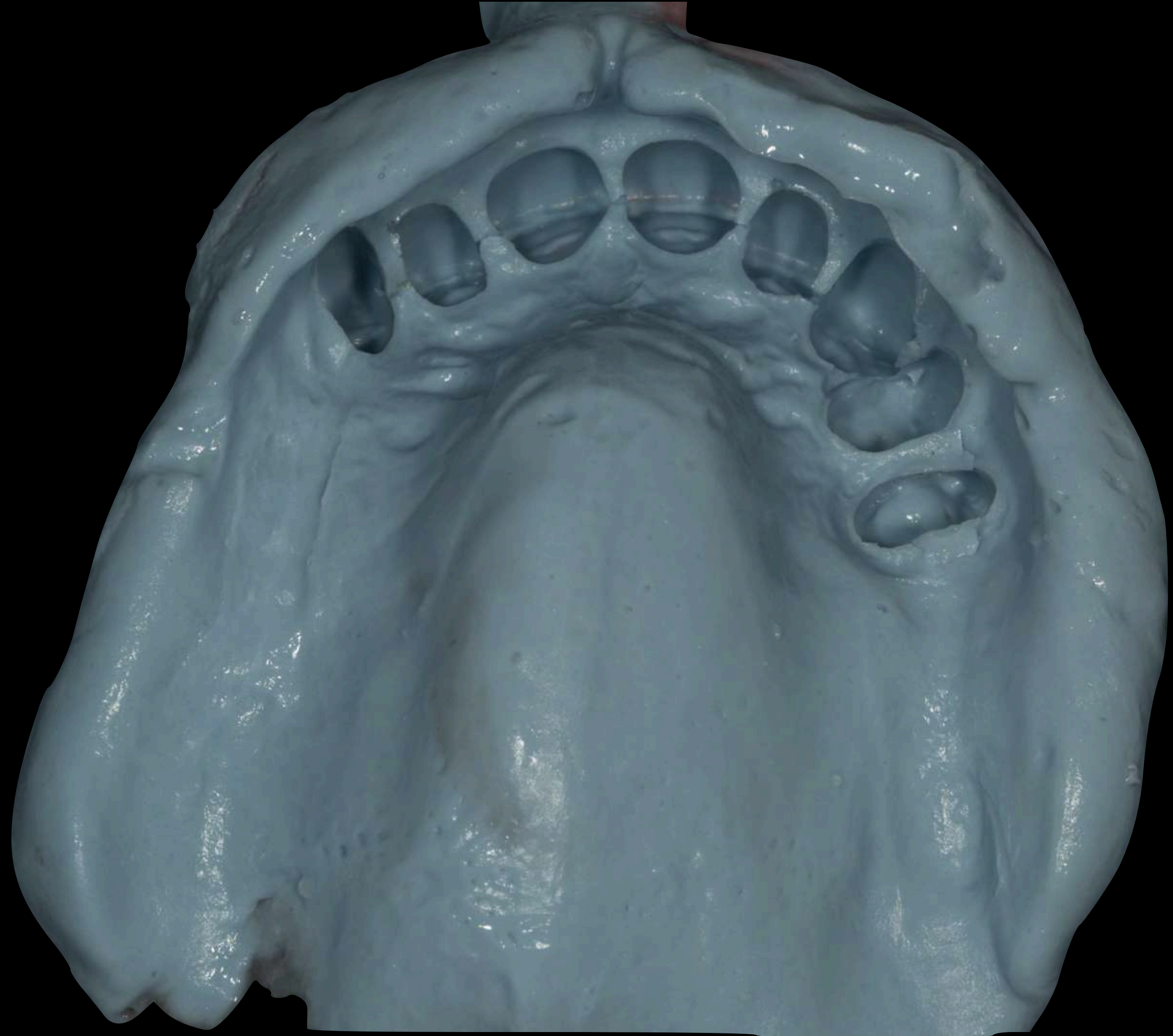
Working impression



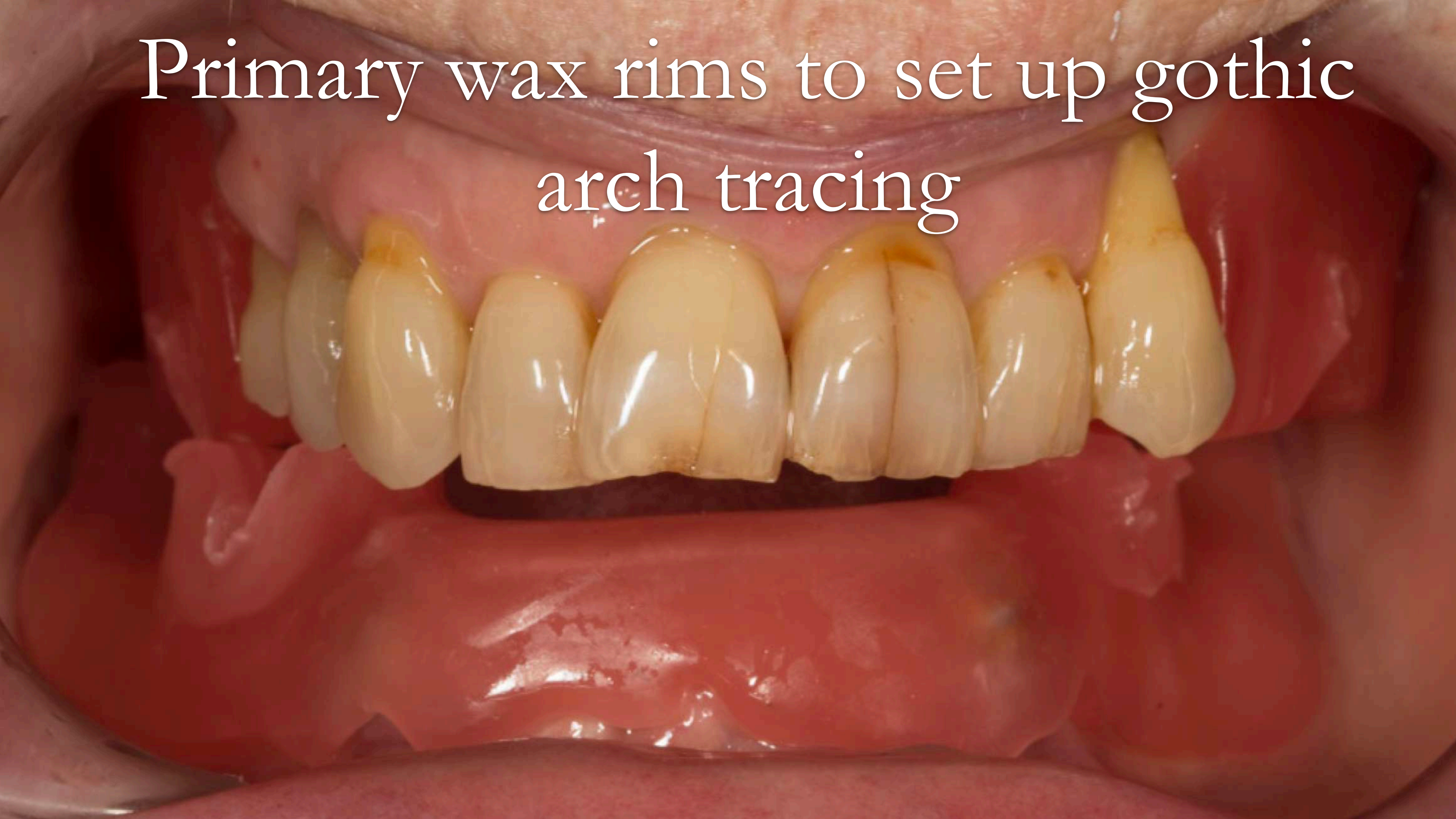Working impression



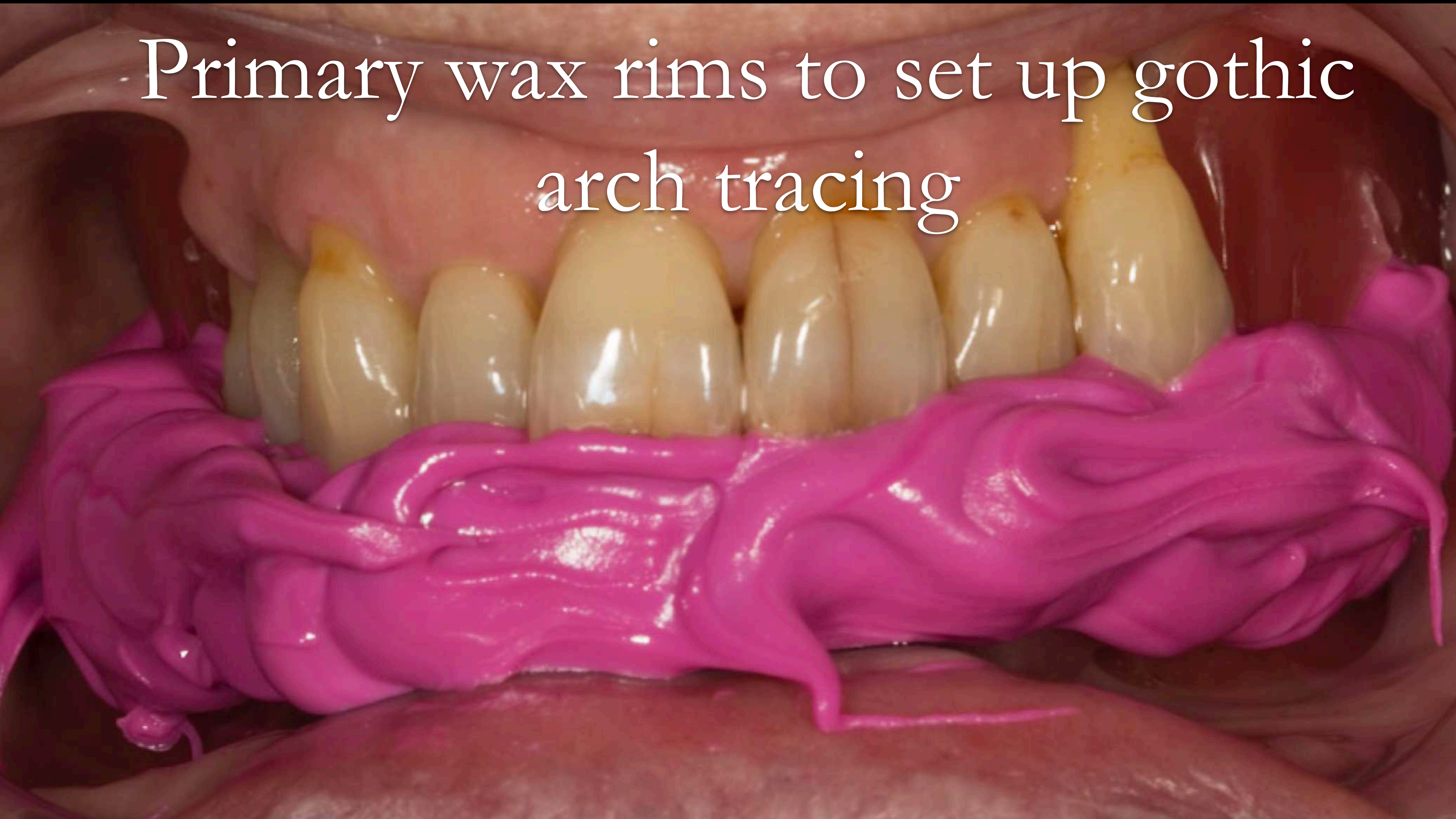Working impression



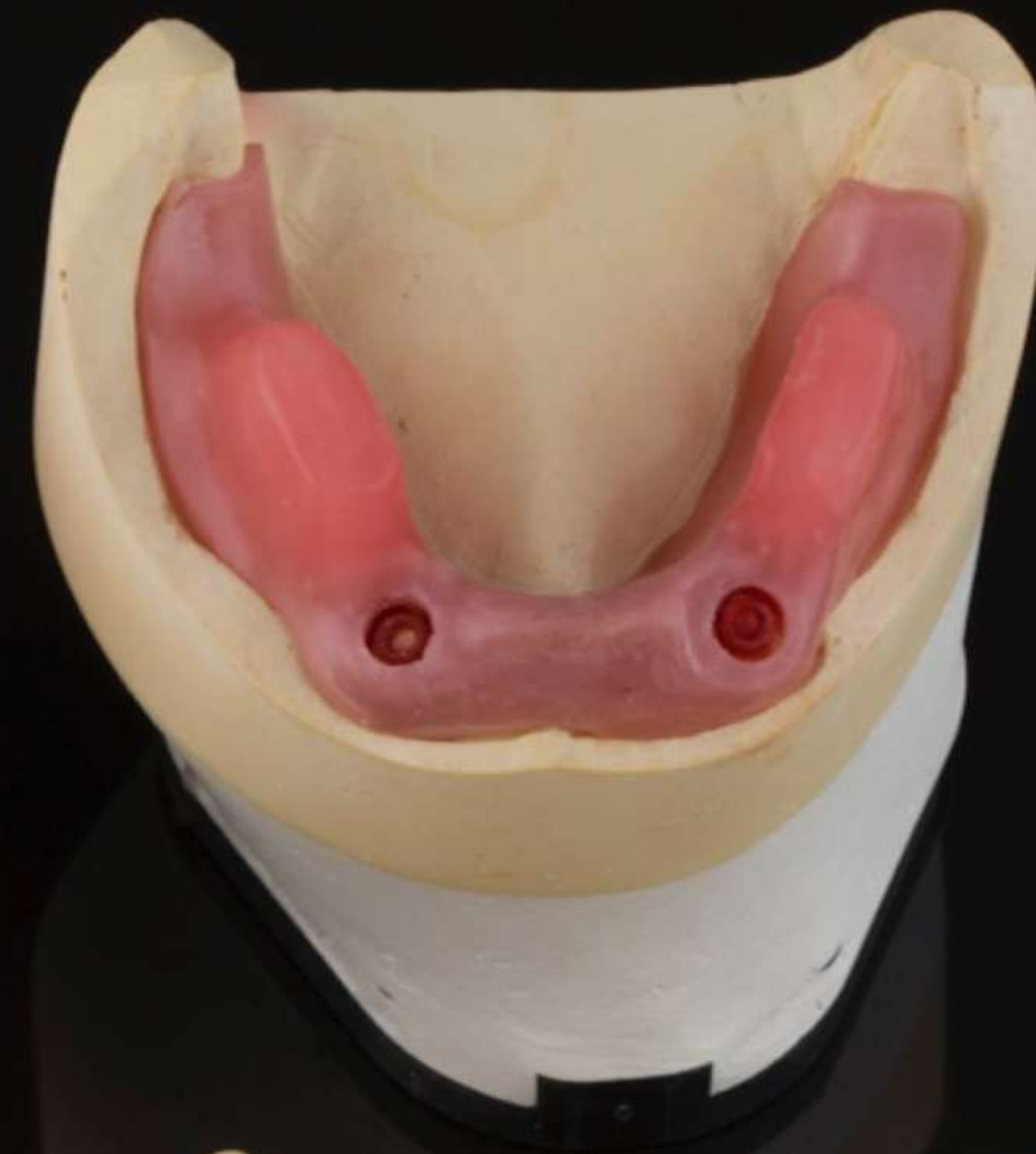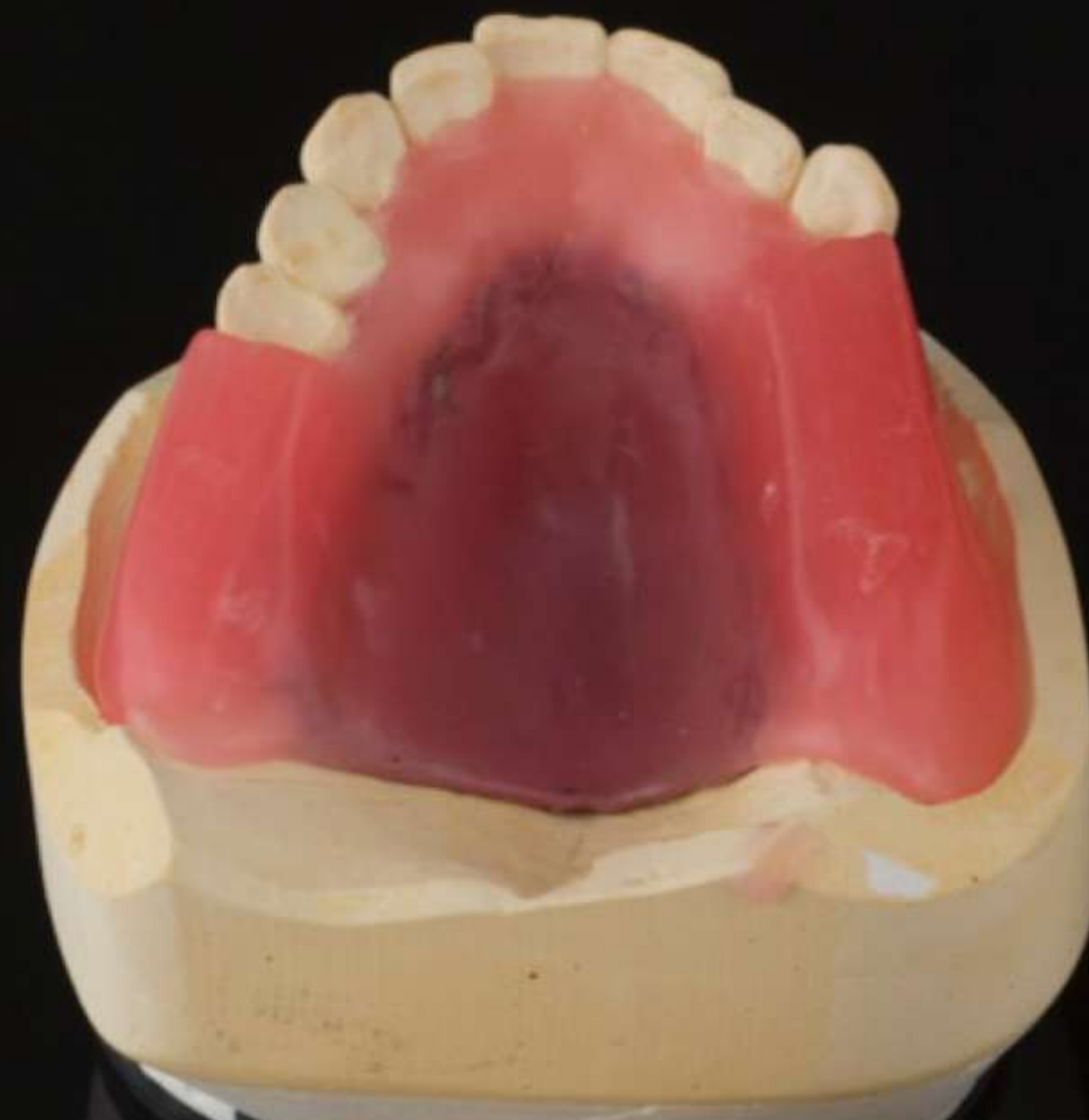Primary wax rims to set up gothic
arch tracing



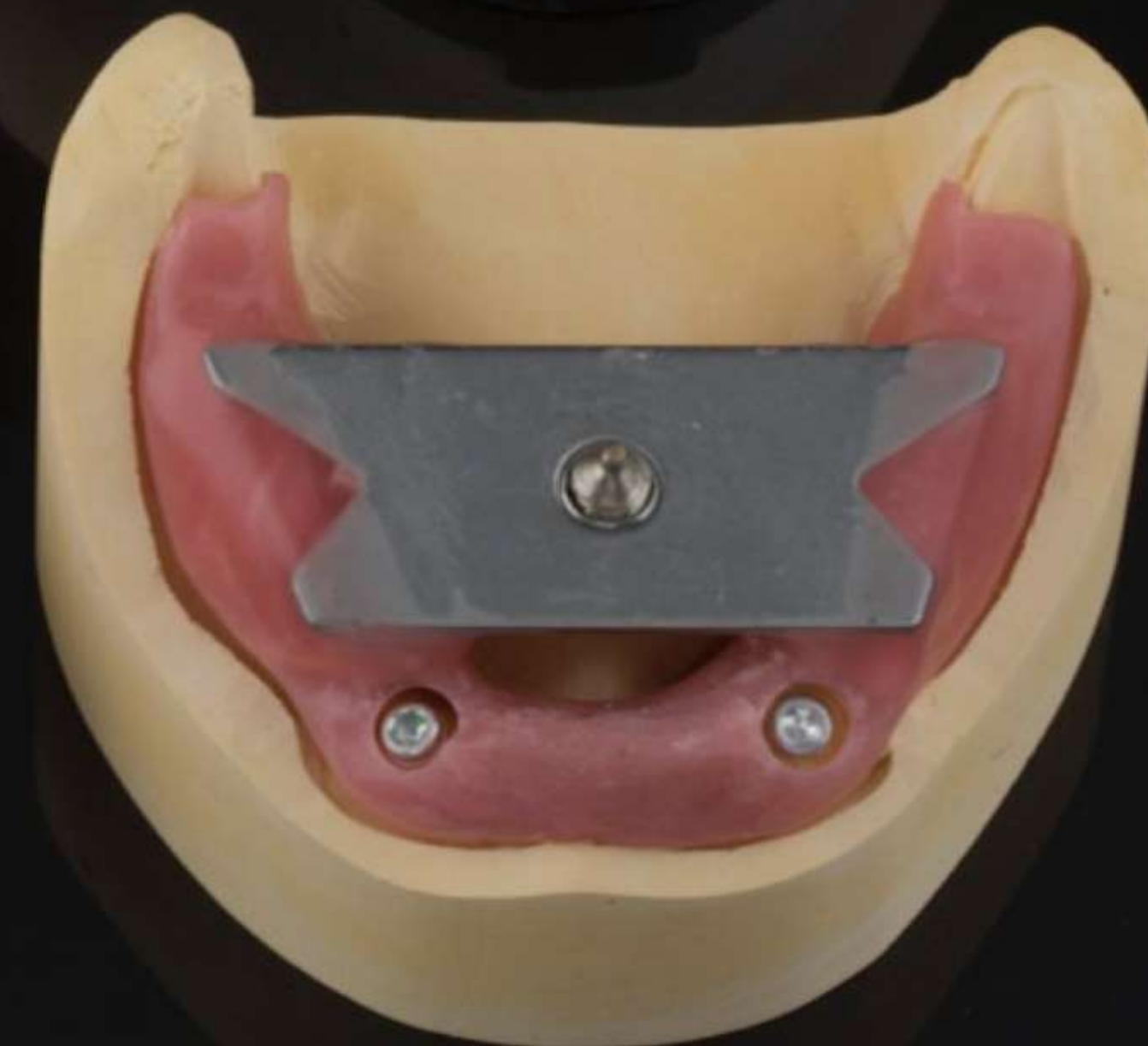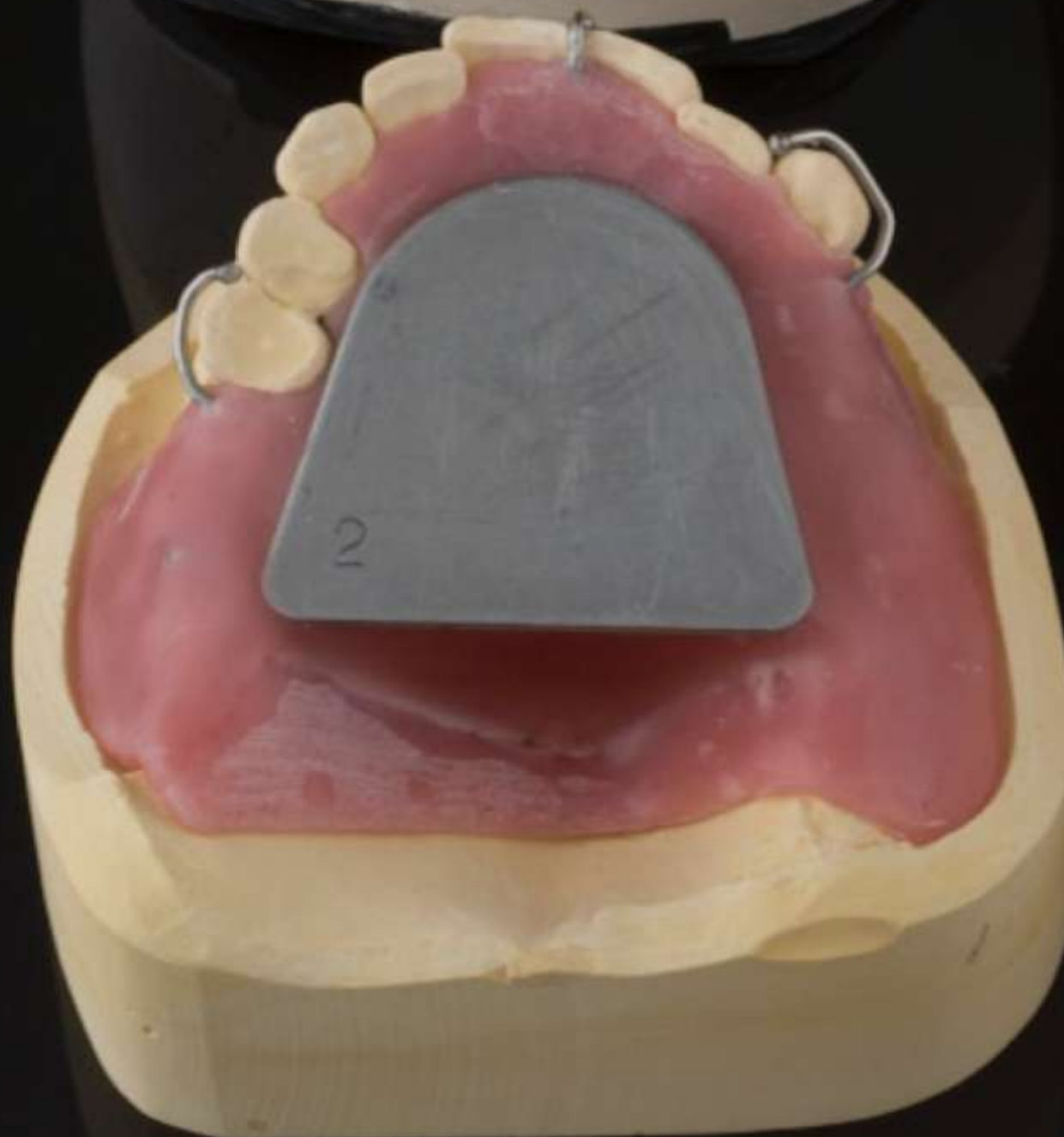Primary wax rims to set up gothic
arch tracing



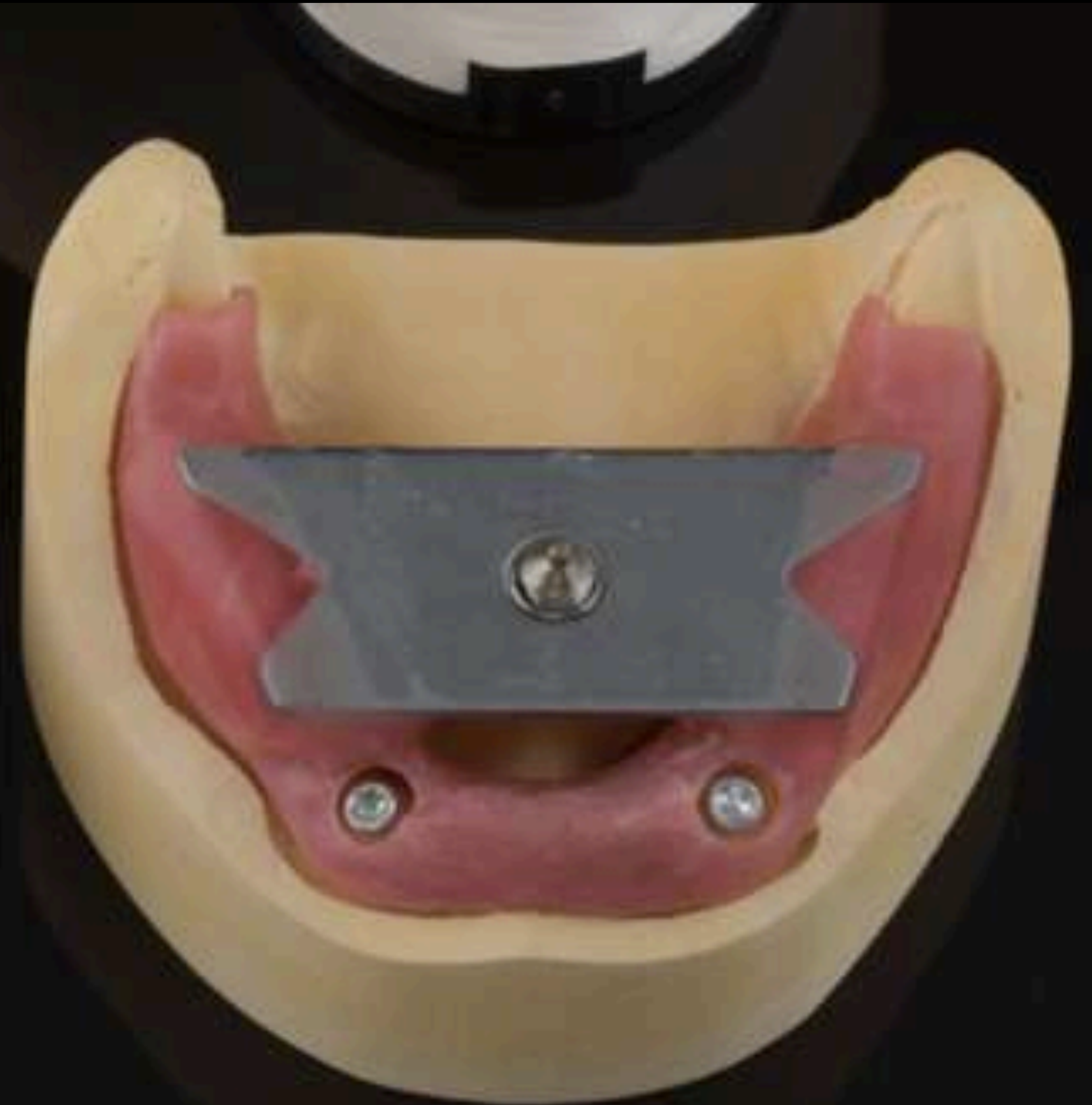
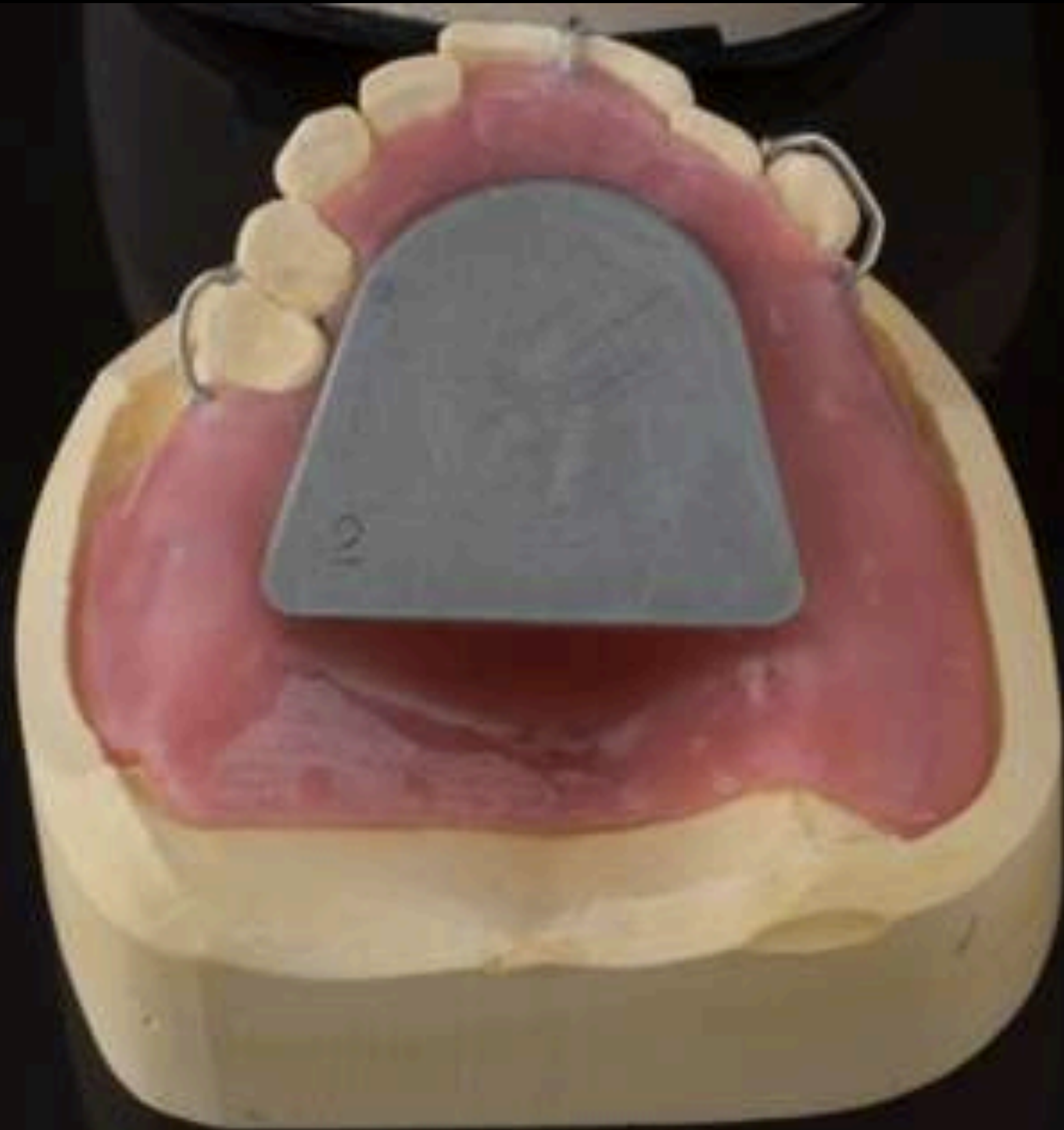Wax rims
for OVD



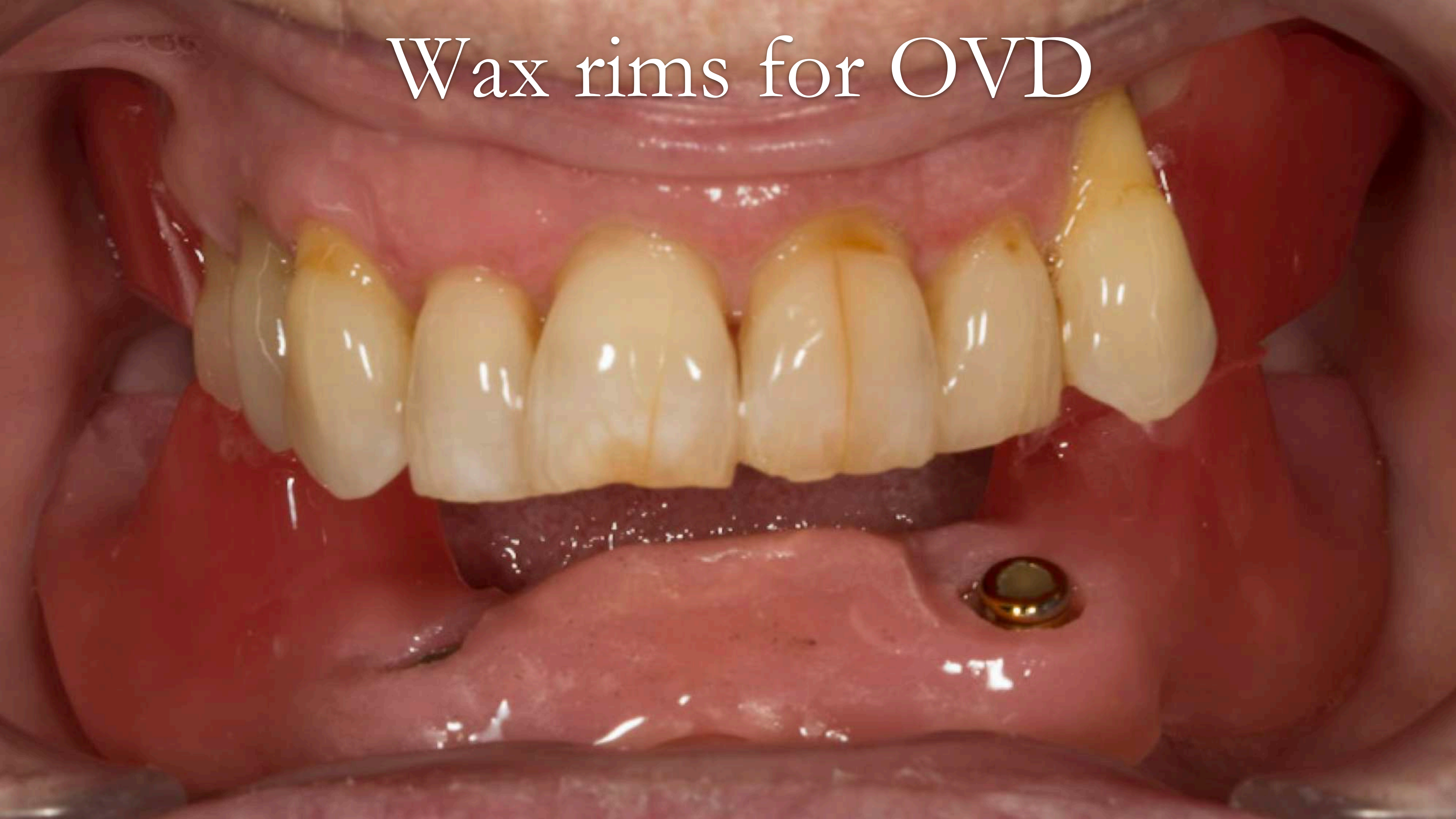Central bearing
appliance
“Gothic arch
tracing”
for CR



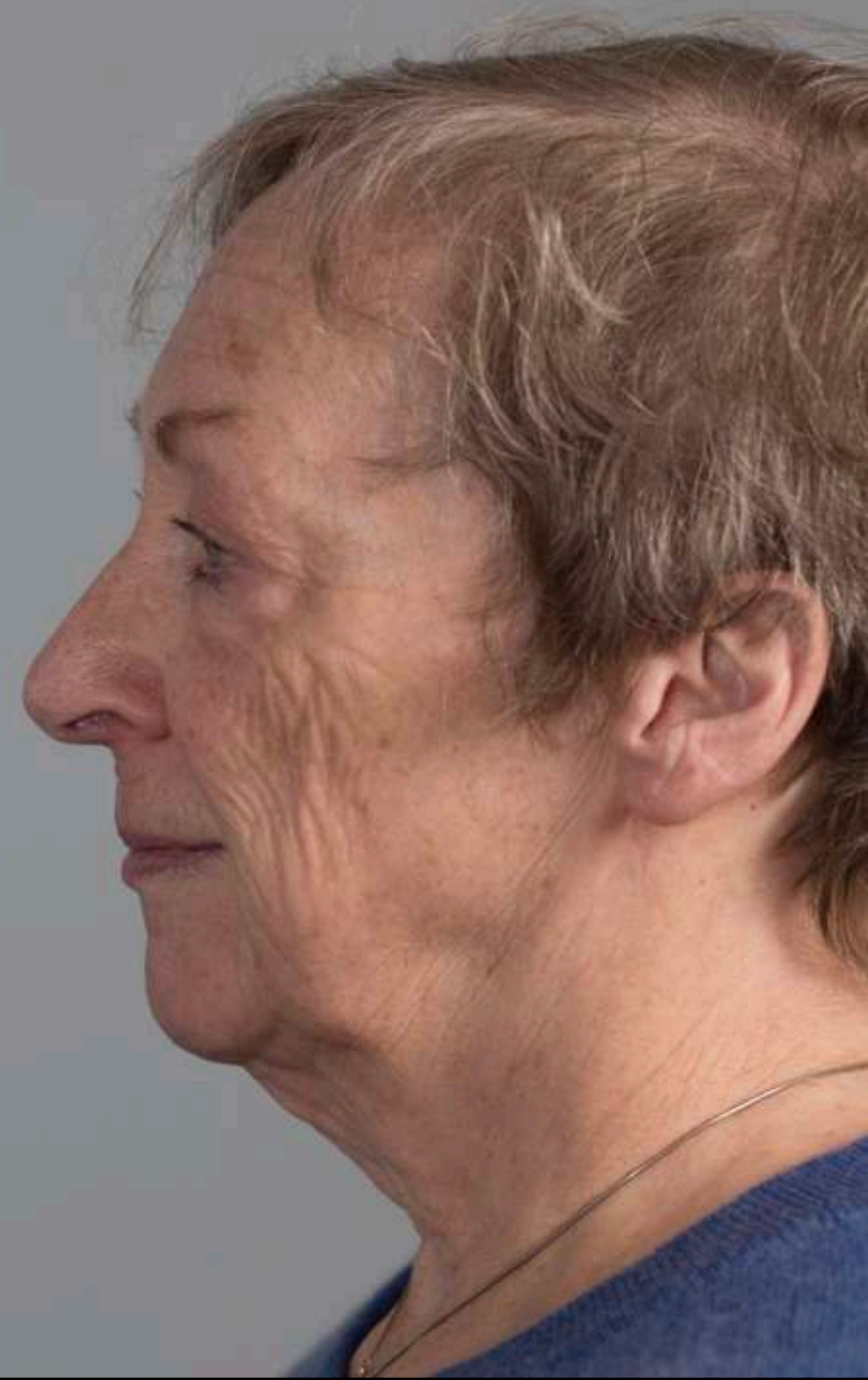Gothic arch tracing/Central bearing apparatus



Wax rims for OVD

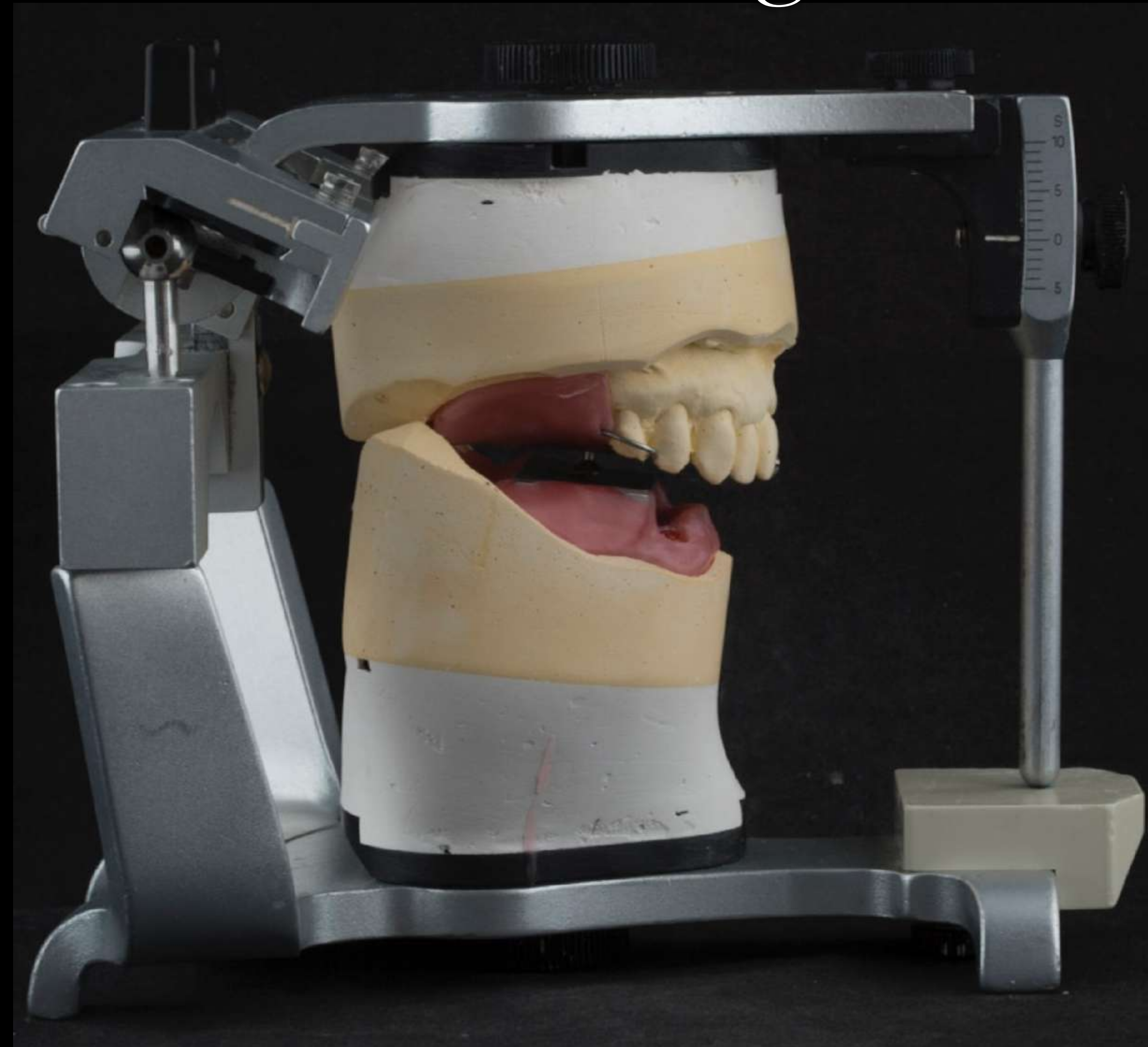
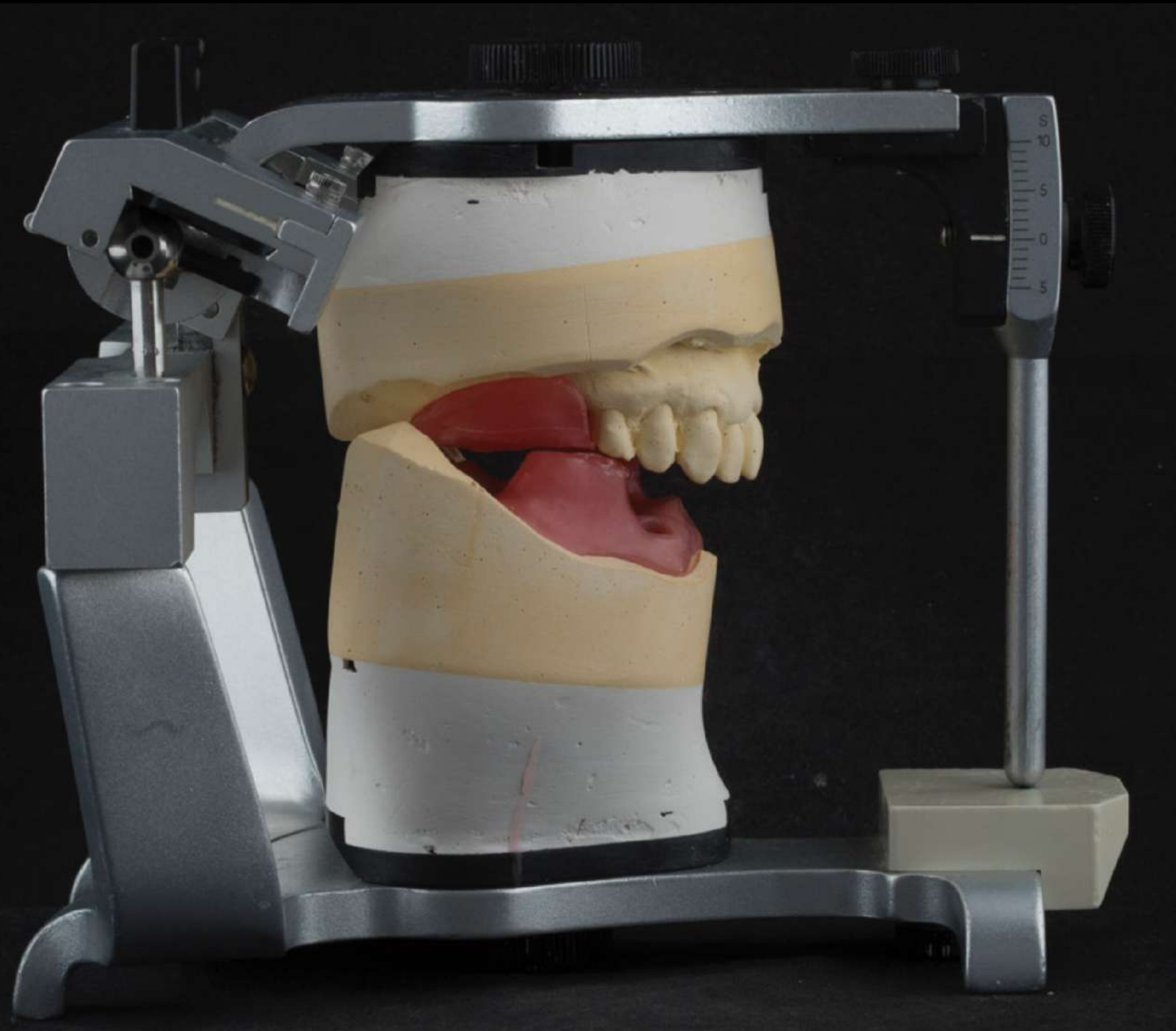
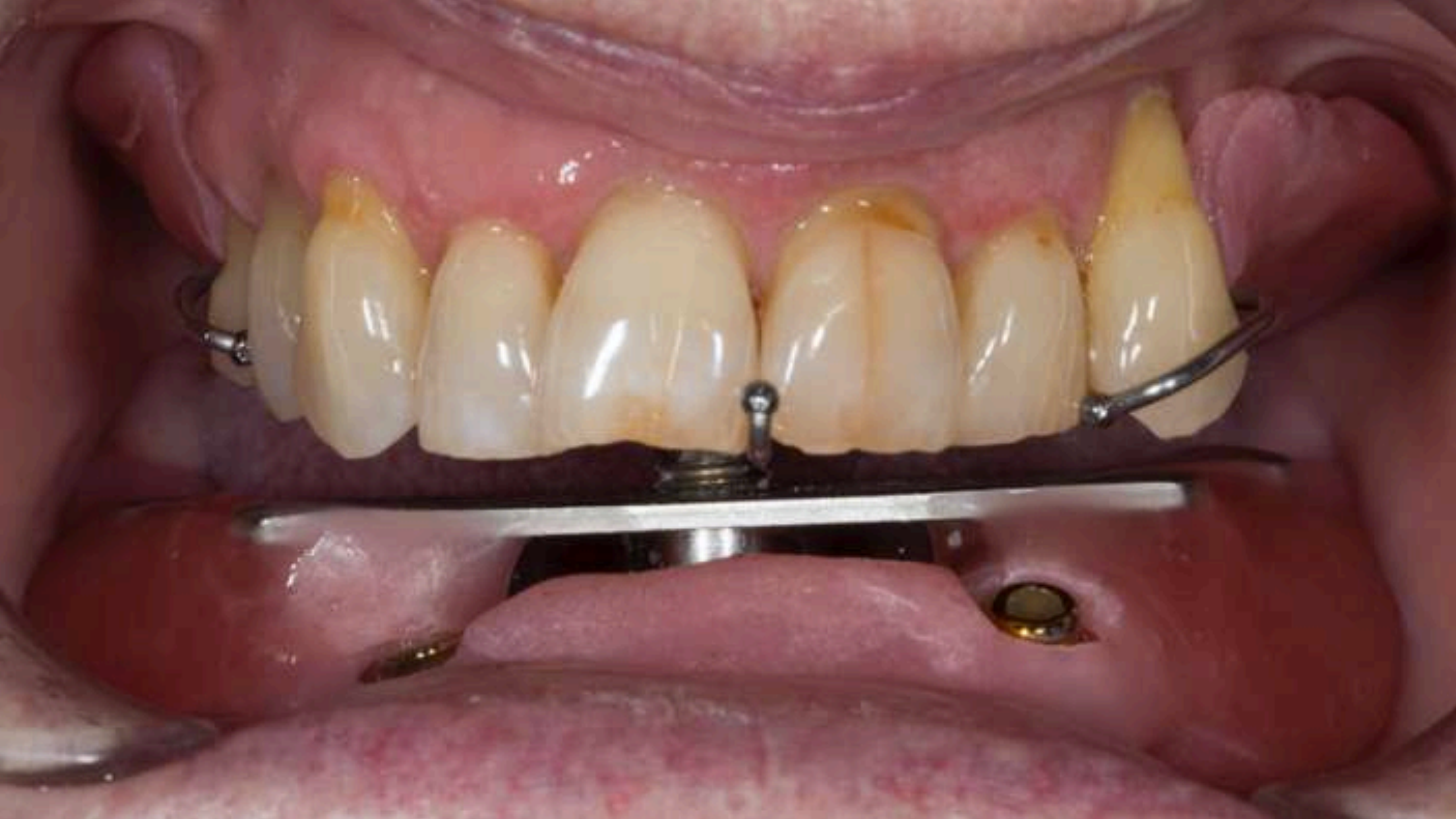OVD with Rims

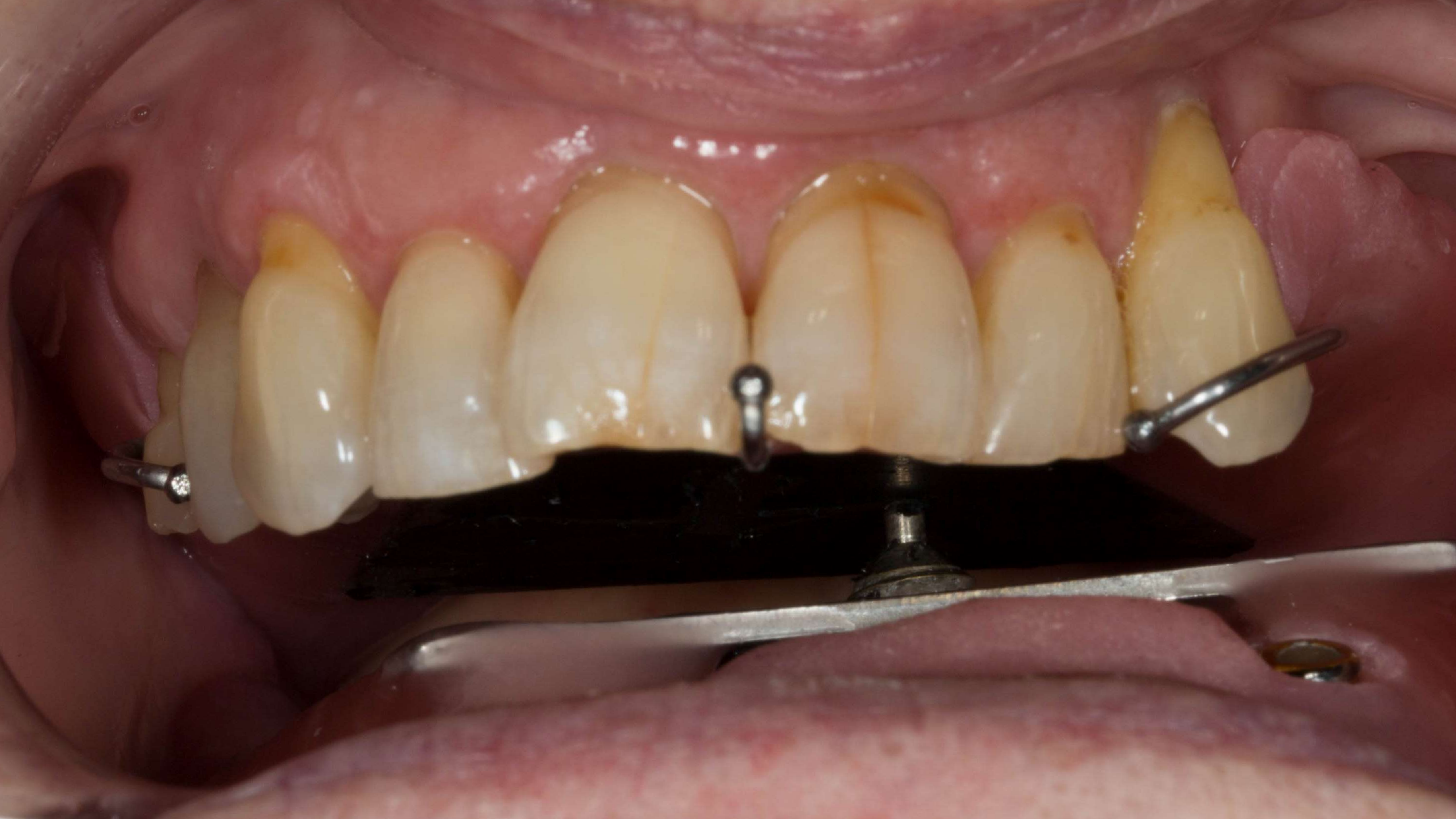

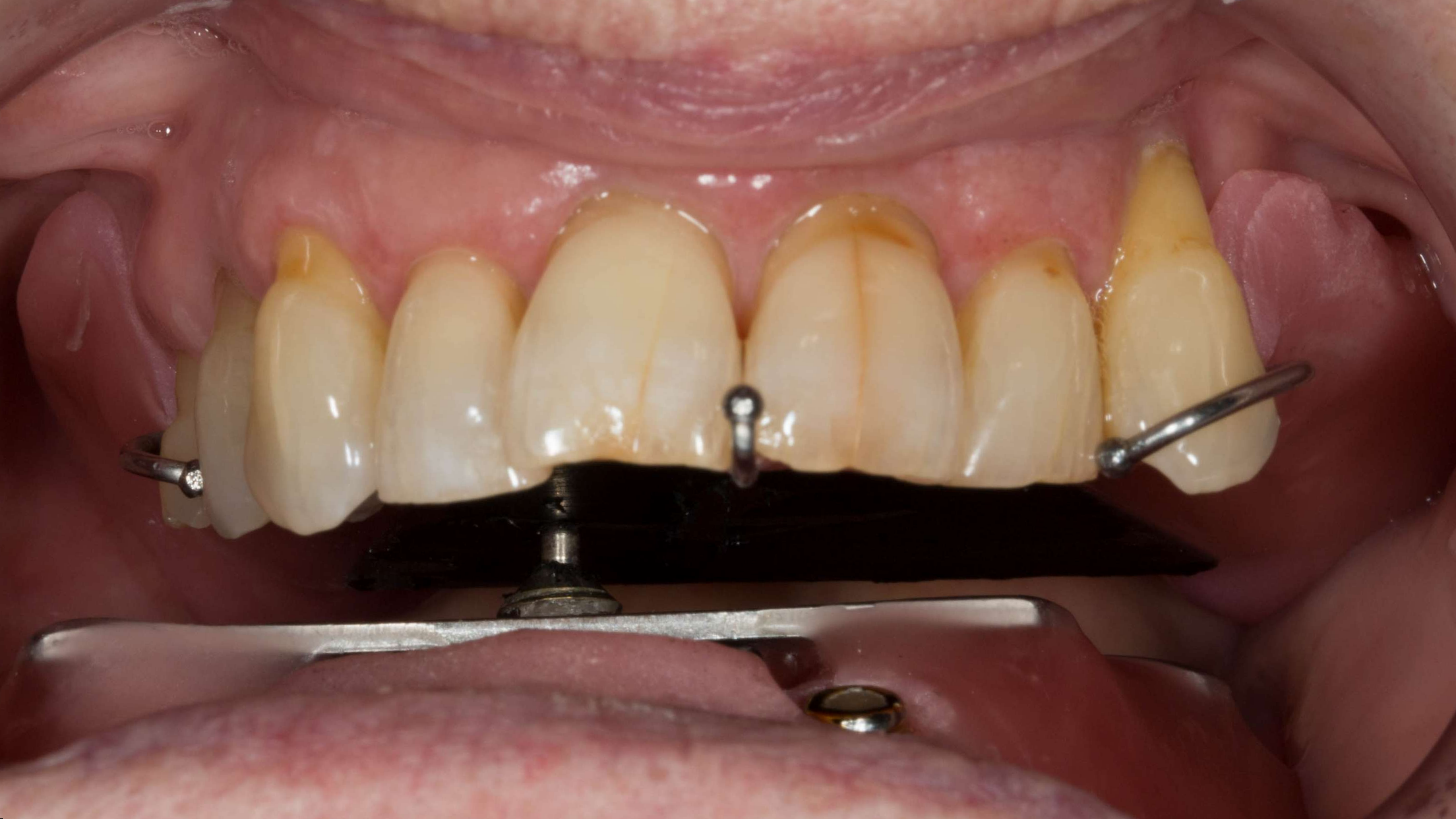“If the patient looks right - they are right”

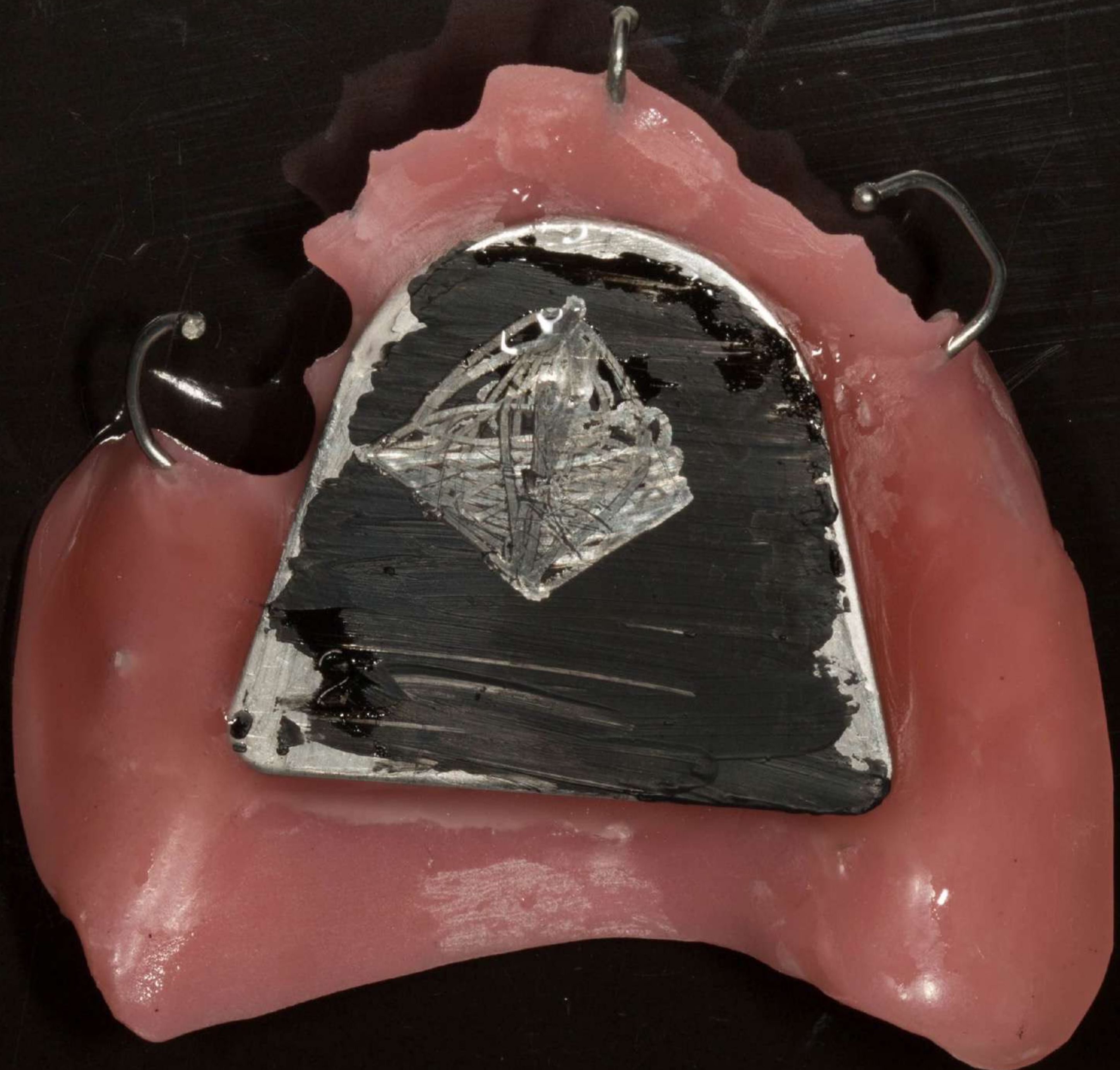OVD of Rims = OVD of Central Bearing Point

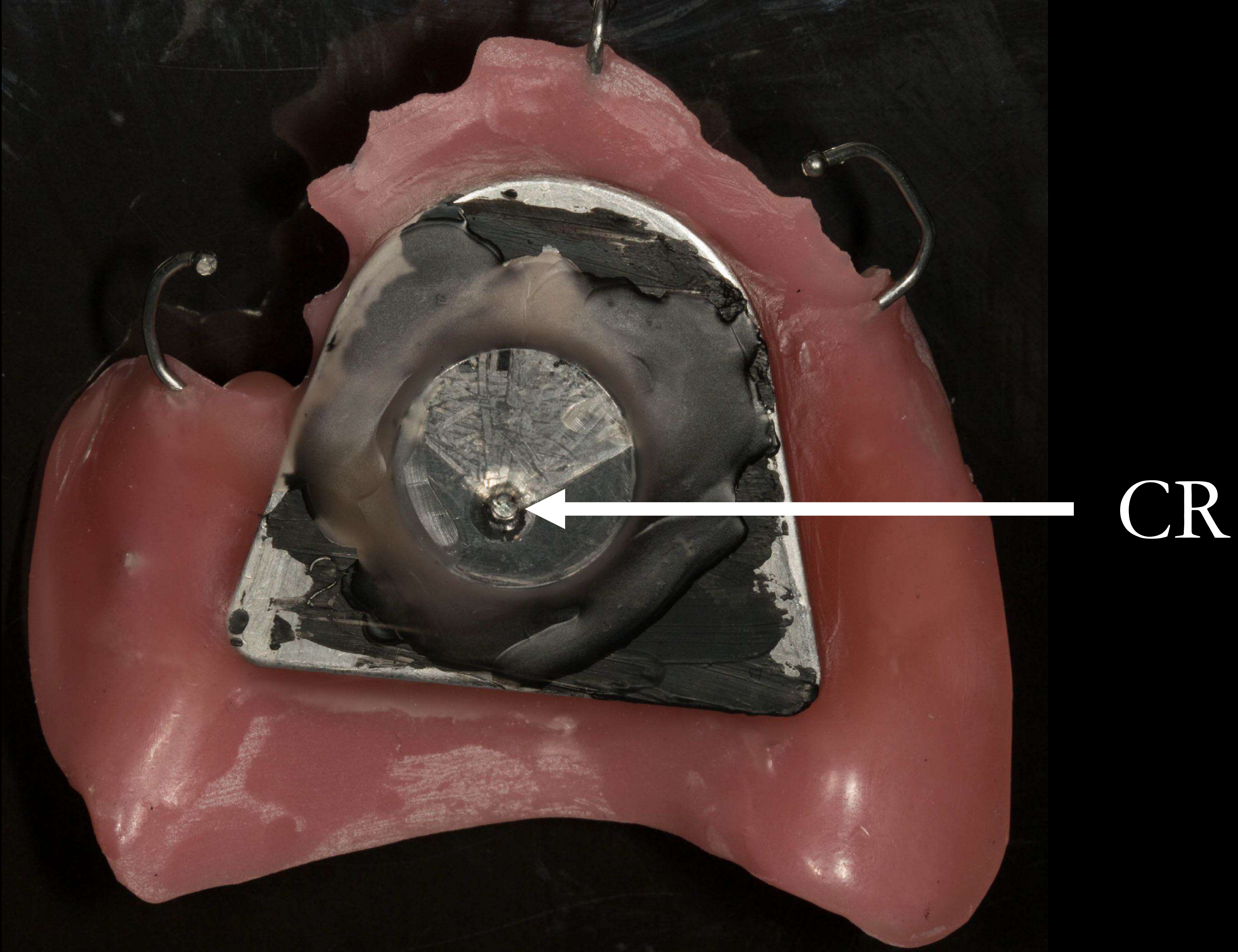




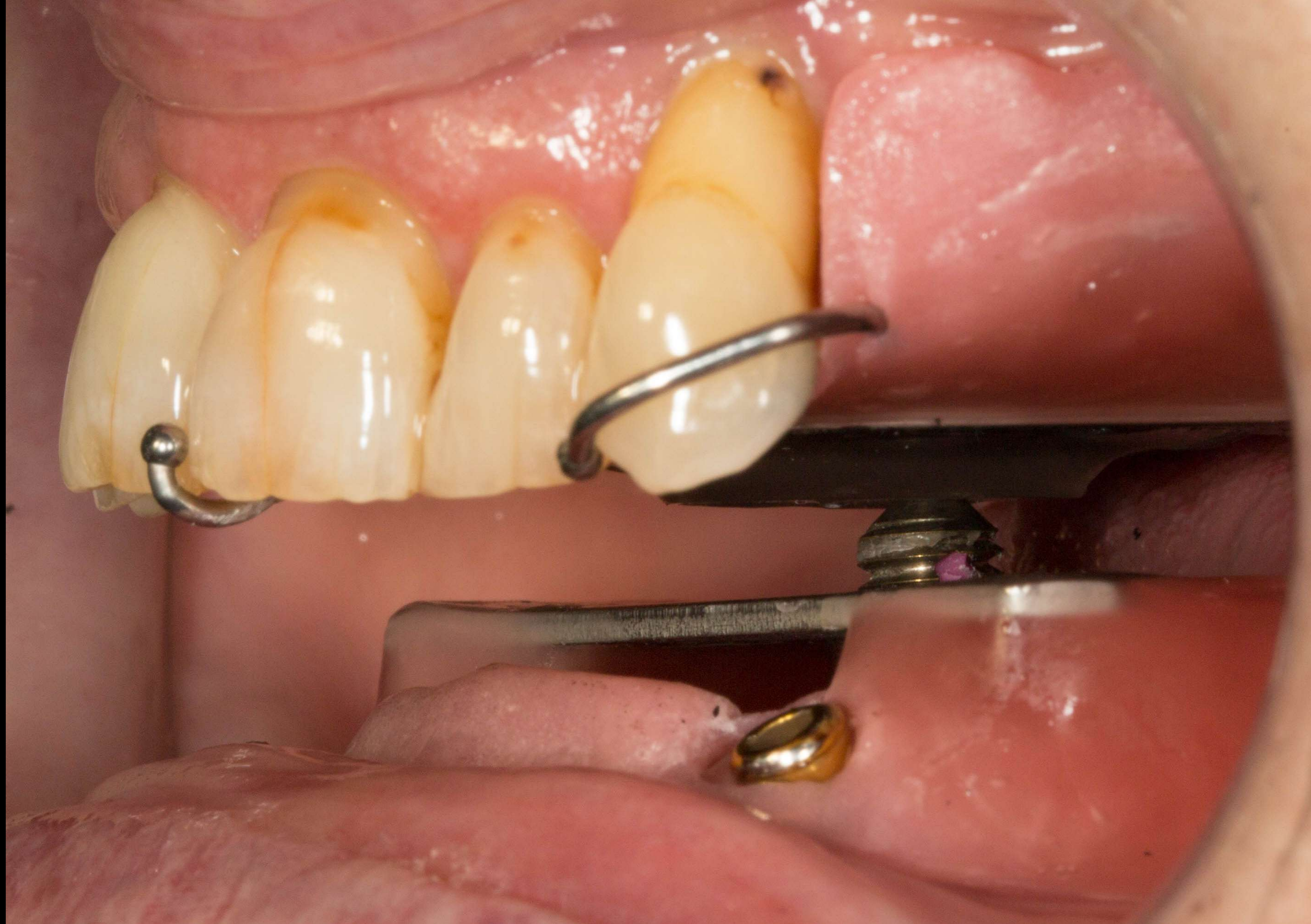


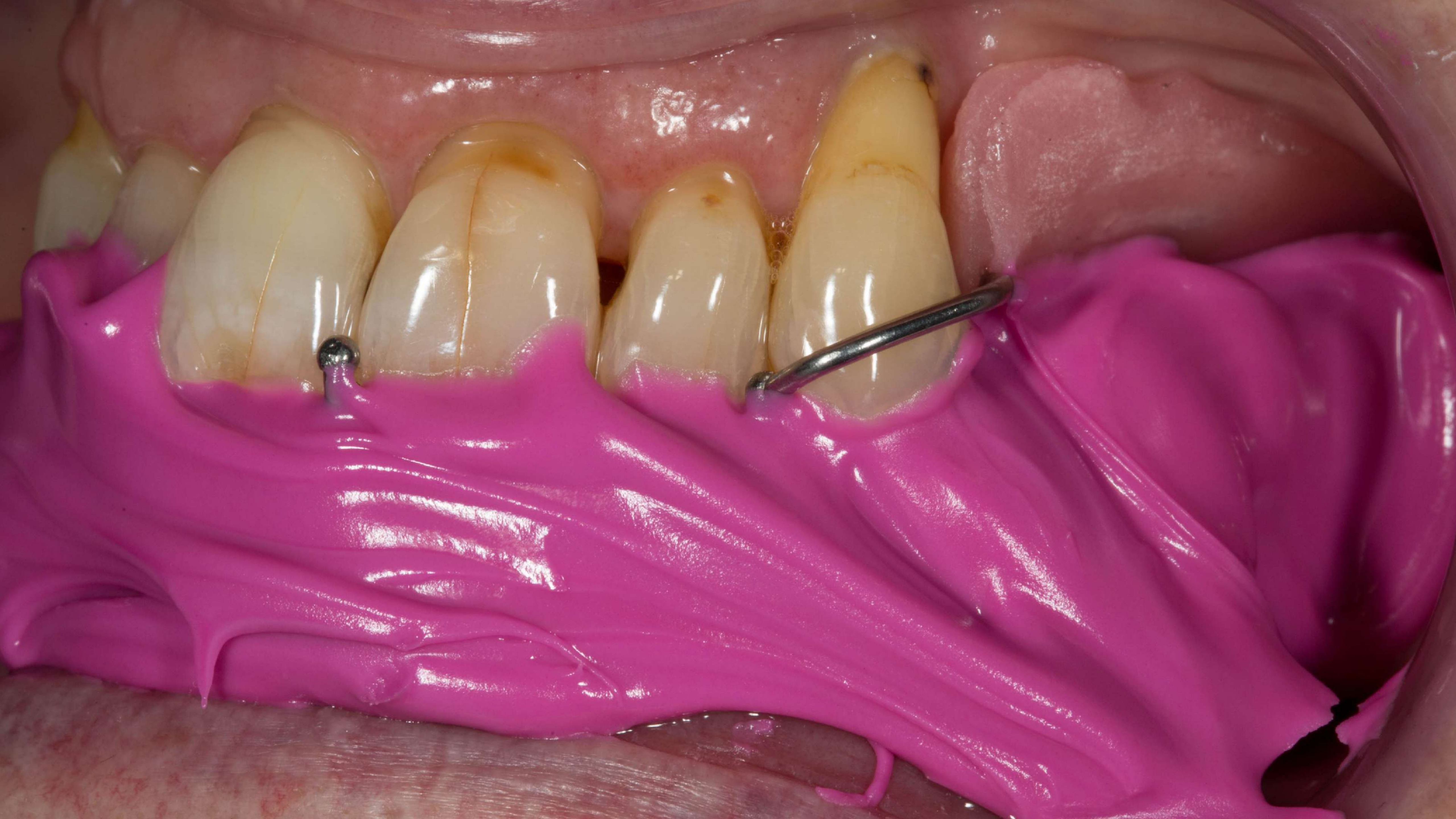
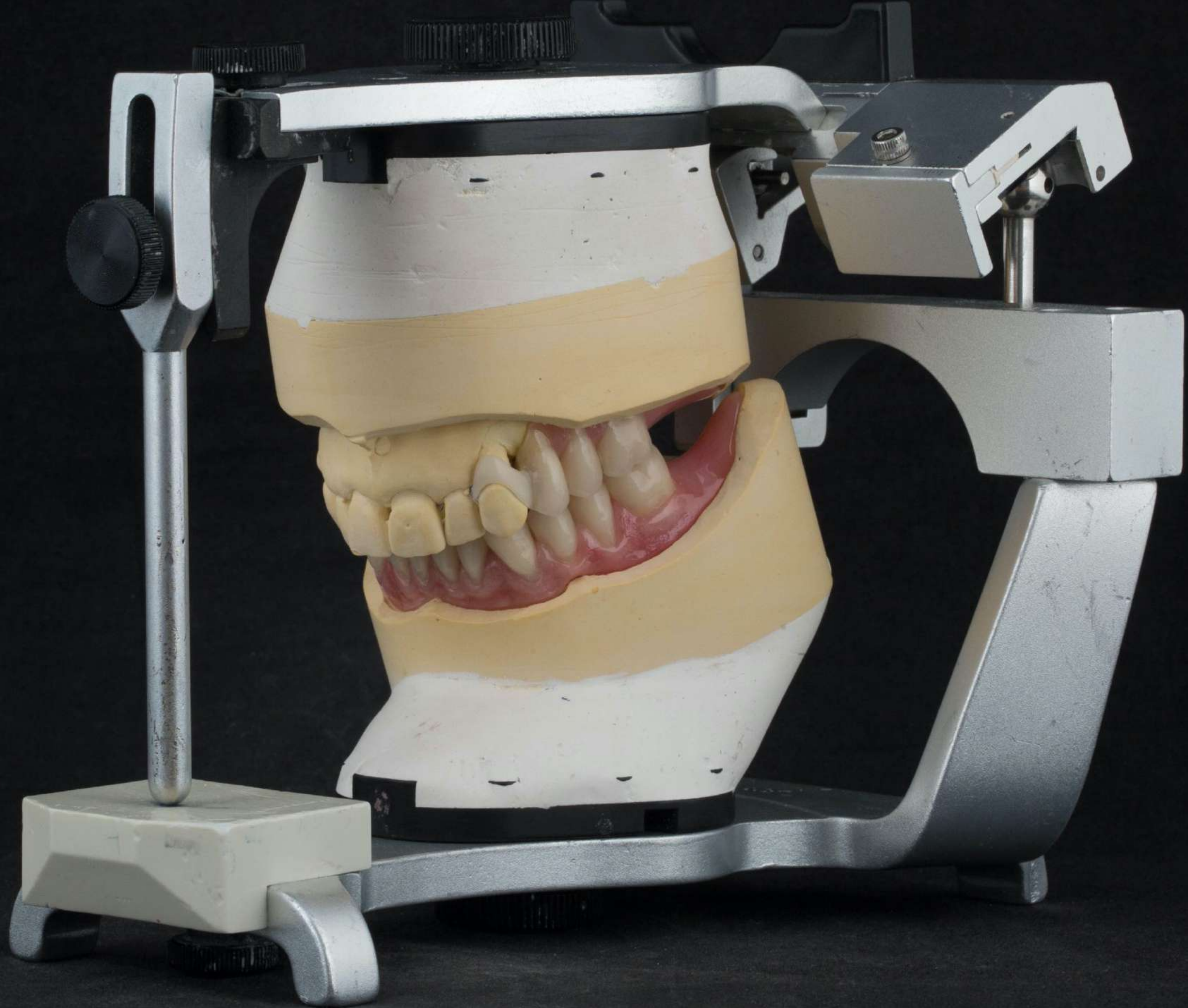




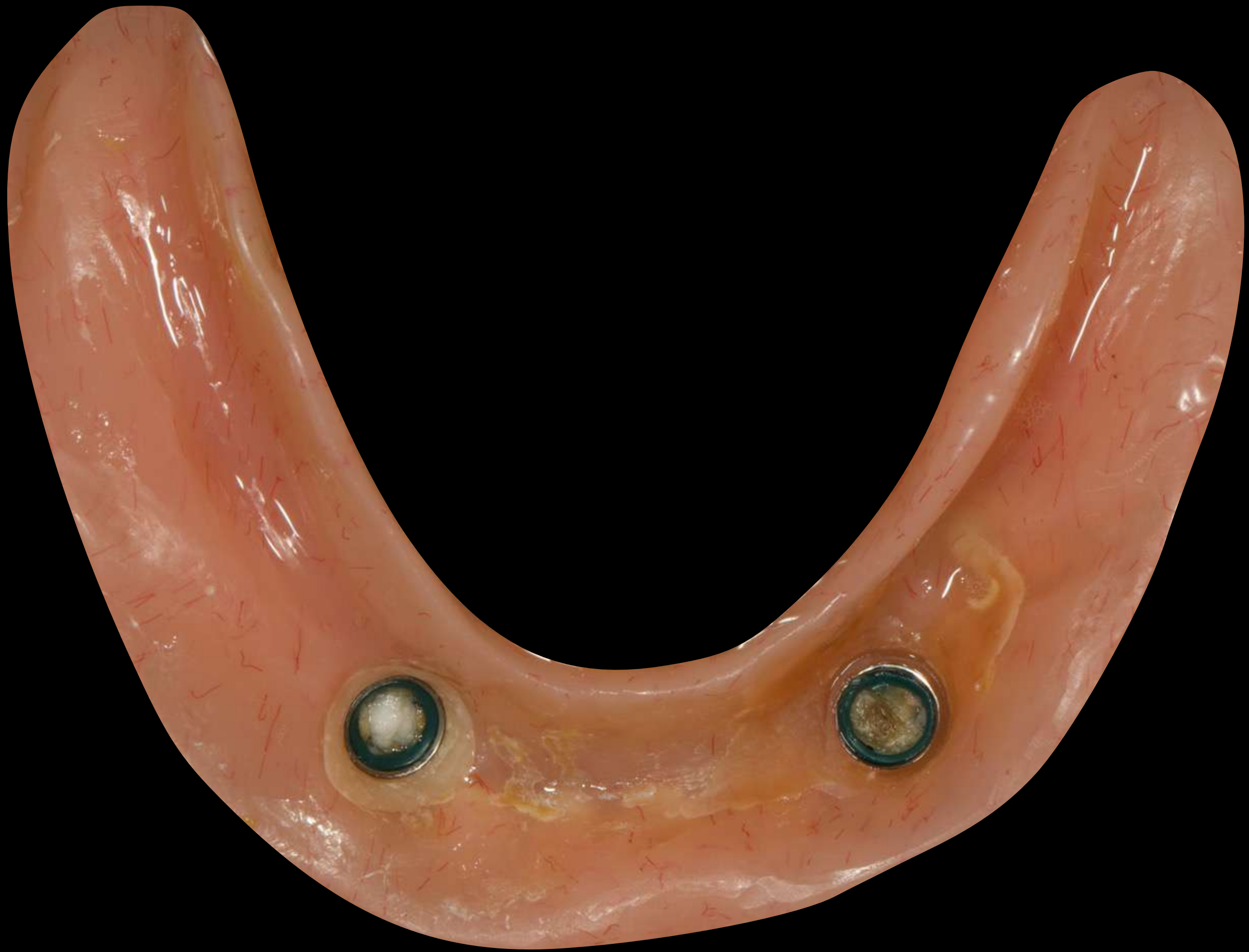CR

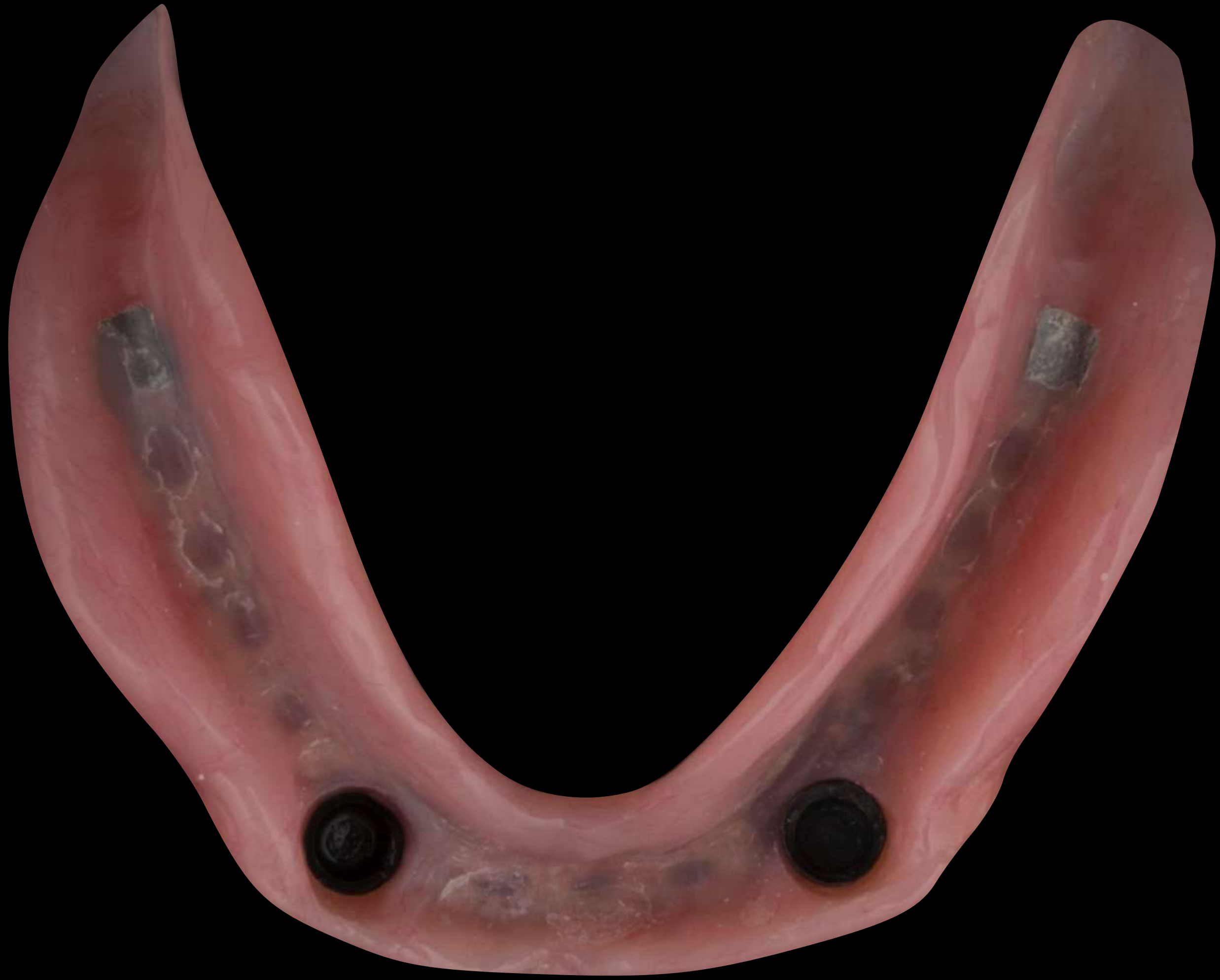




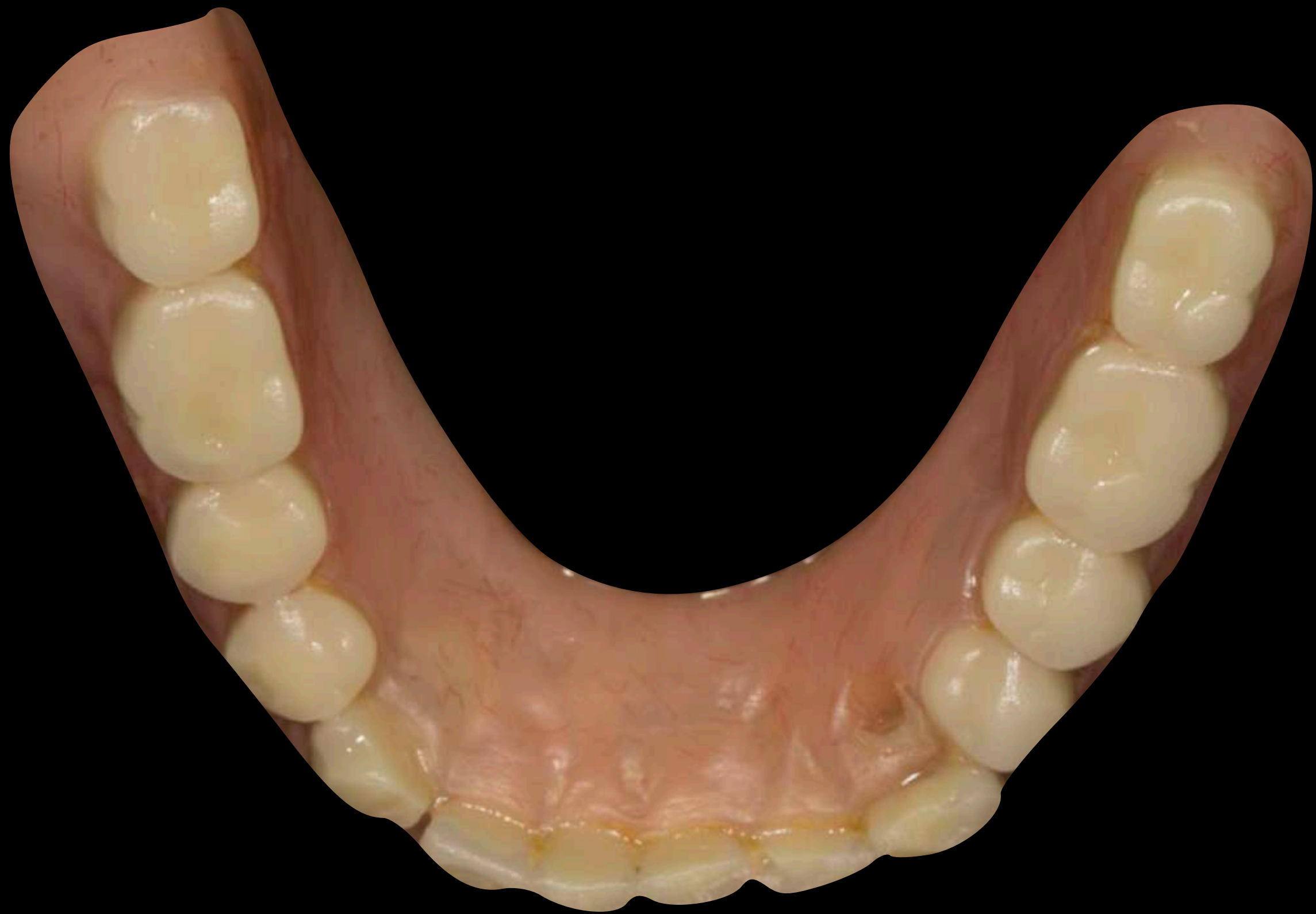


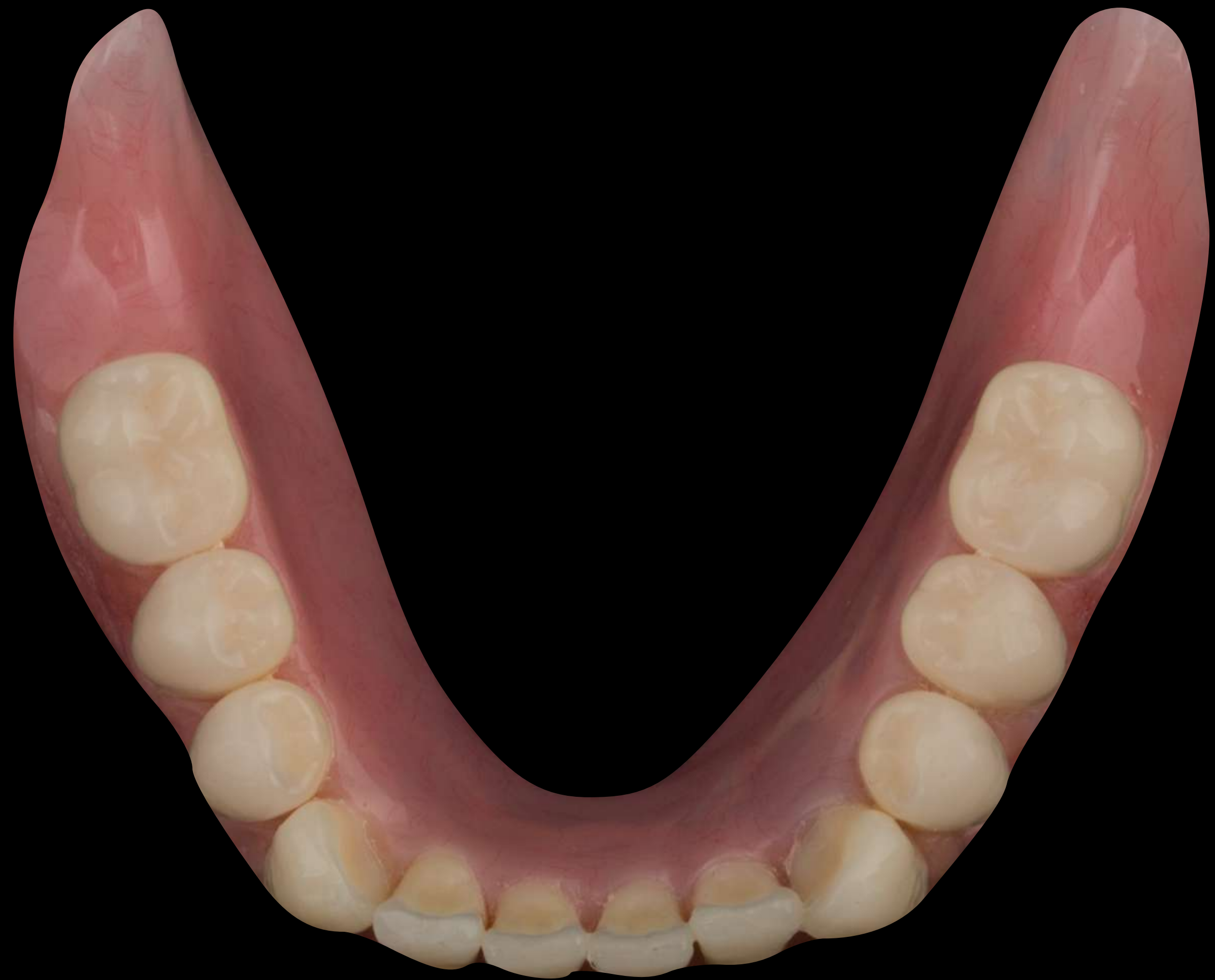Before



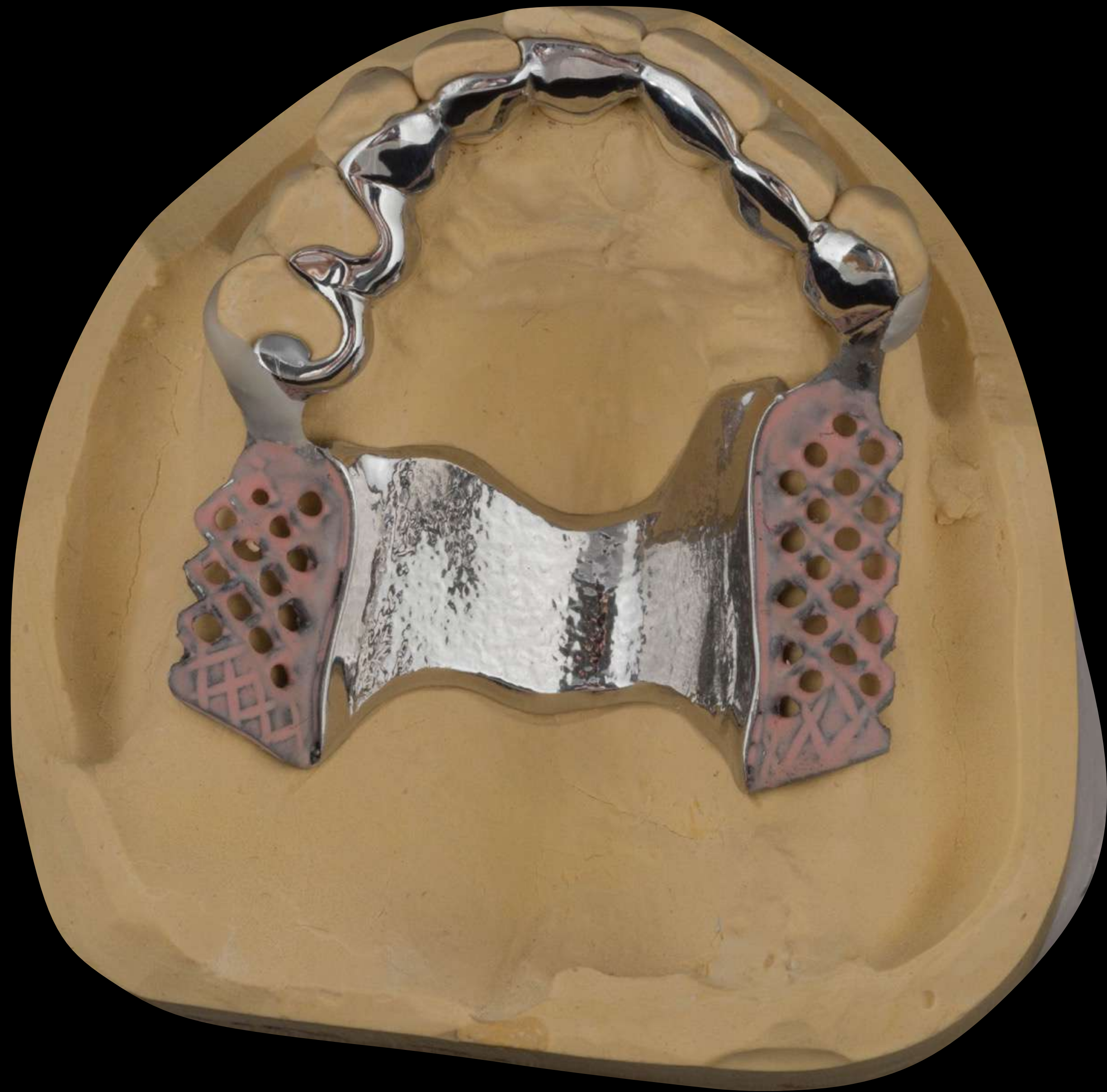After

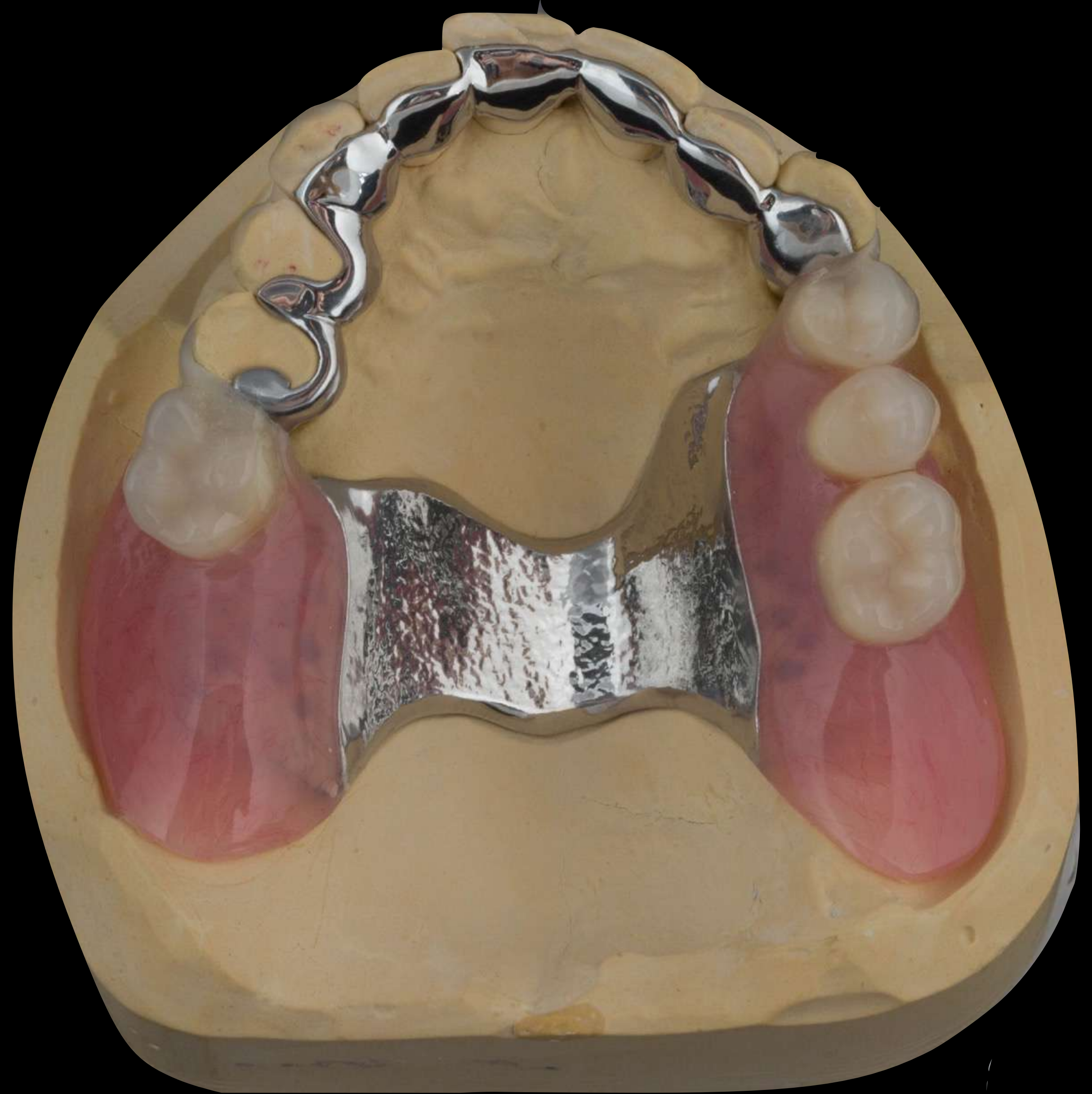

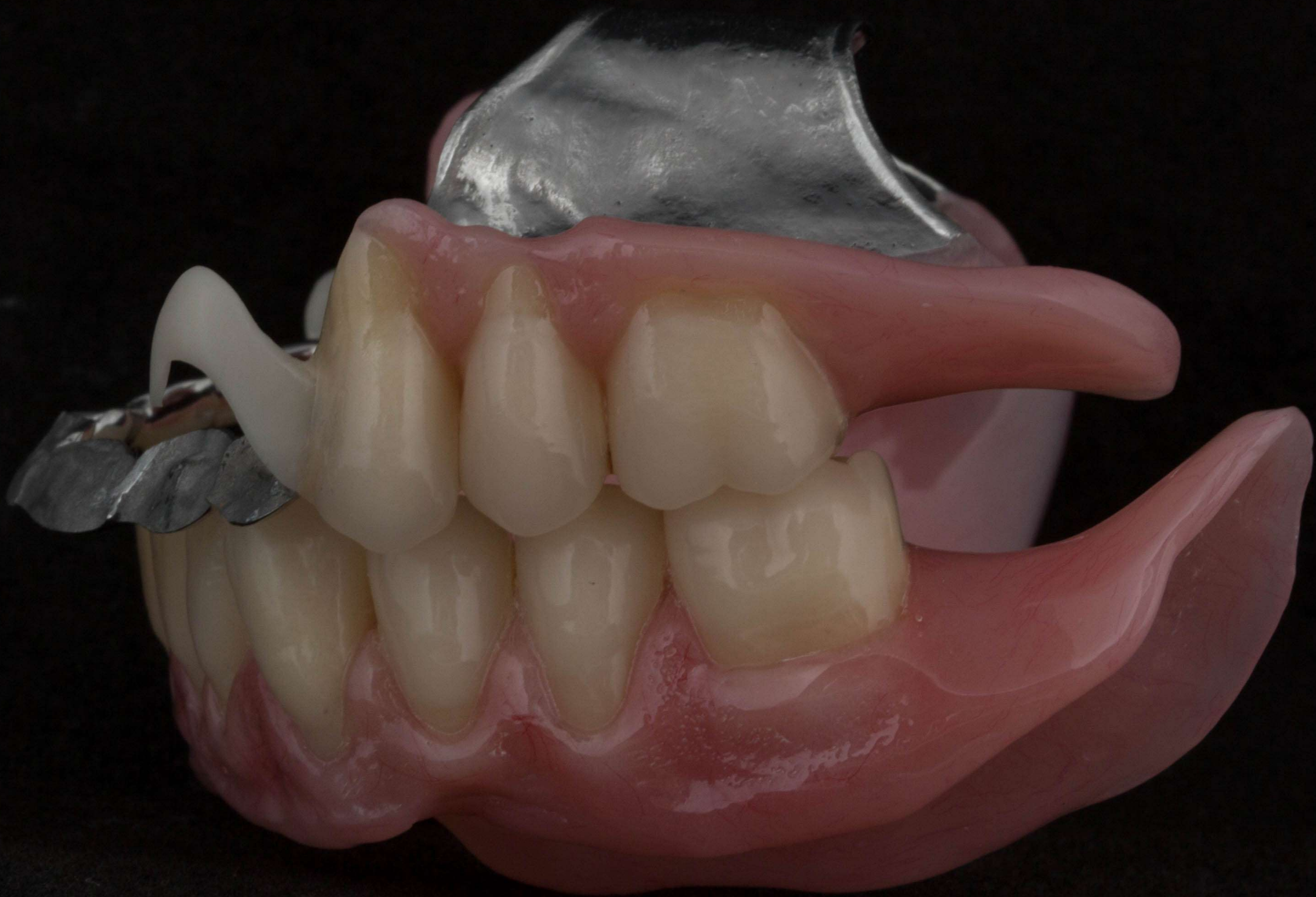Before



After

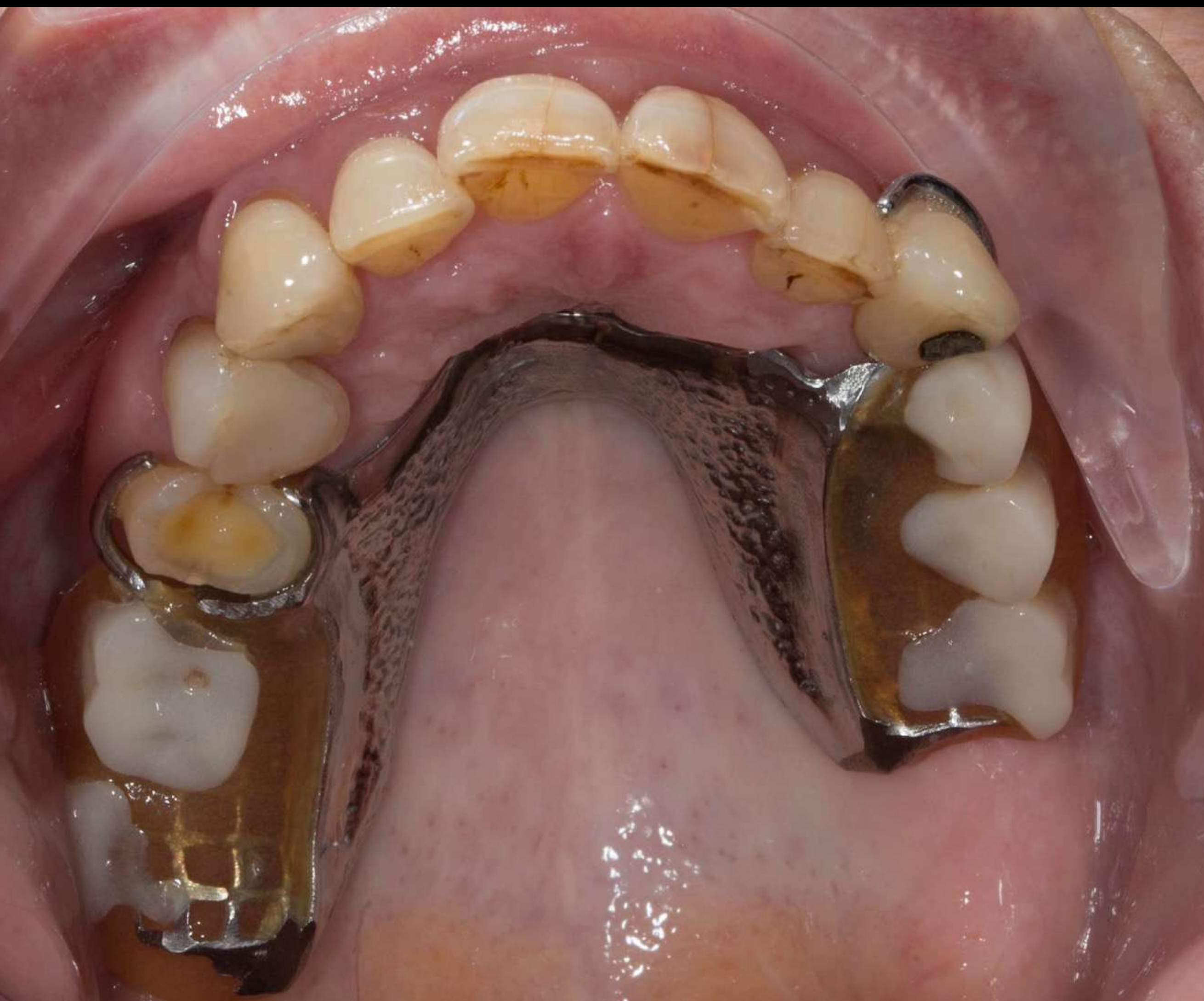




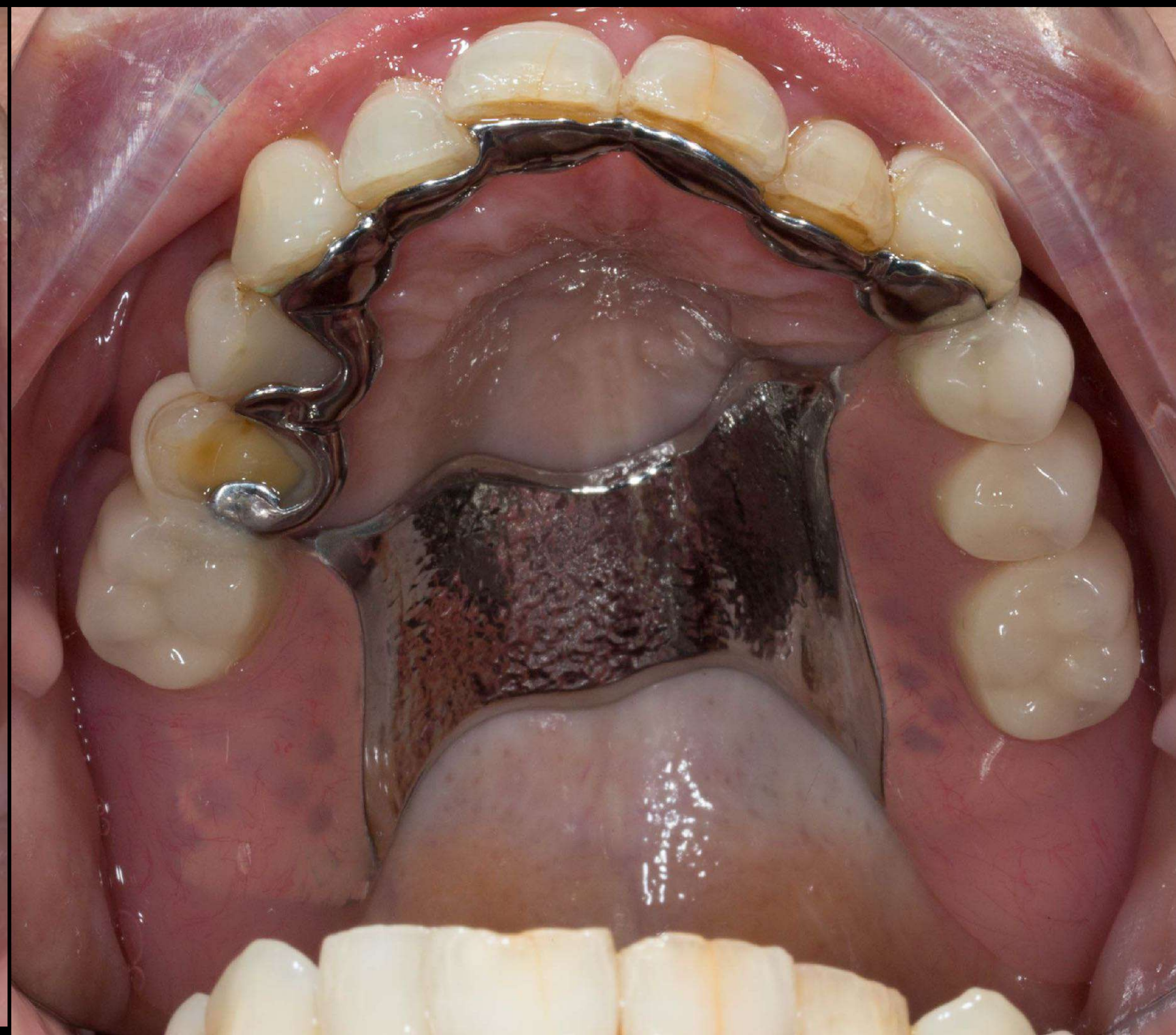


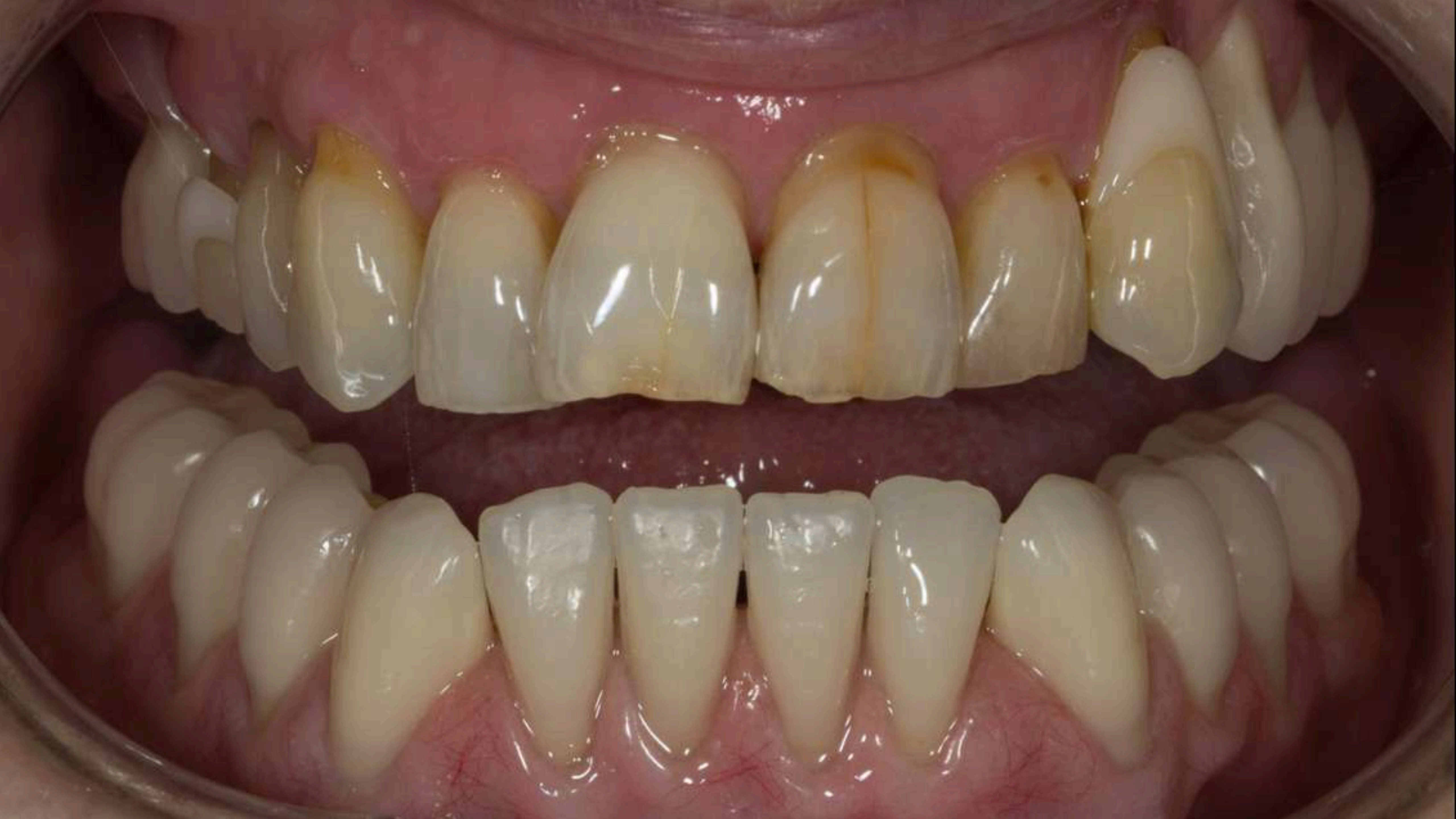myerson®
myersontooth.com

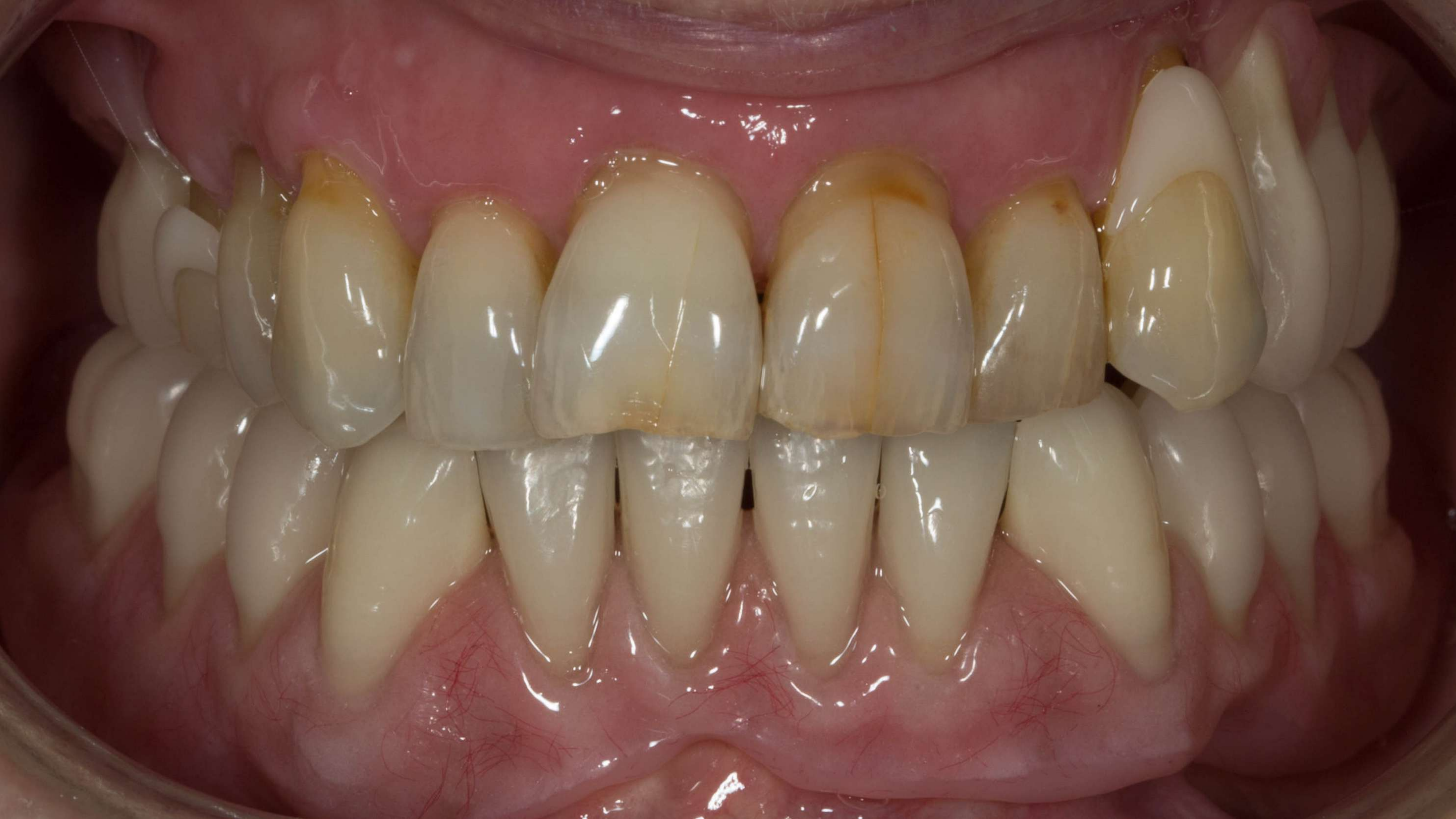

Before



After









Thank you